
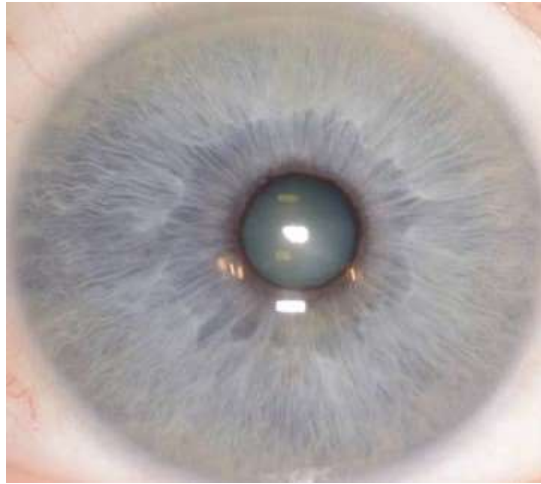


# Observe the Eyes

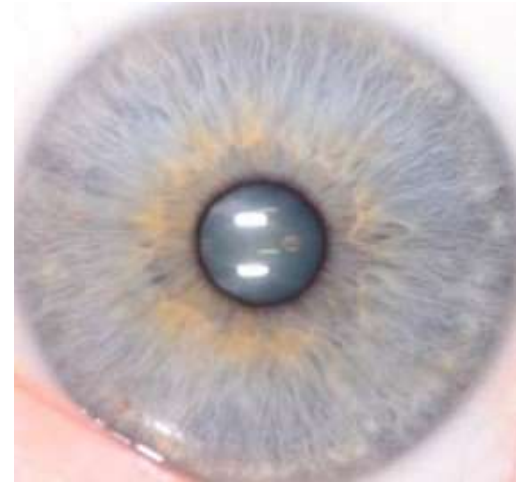




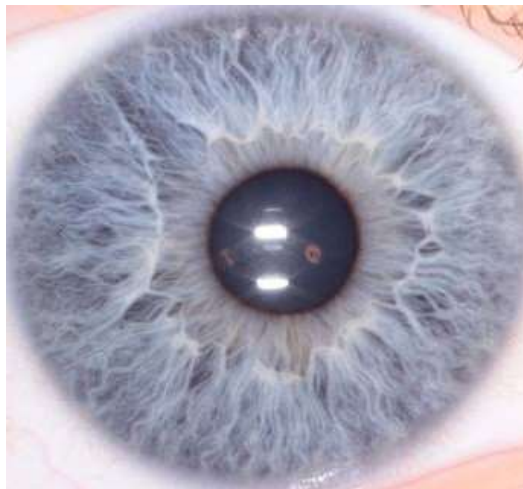
# Rating Constitution



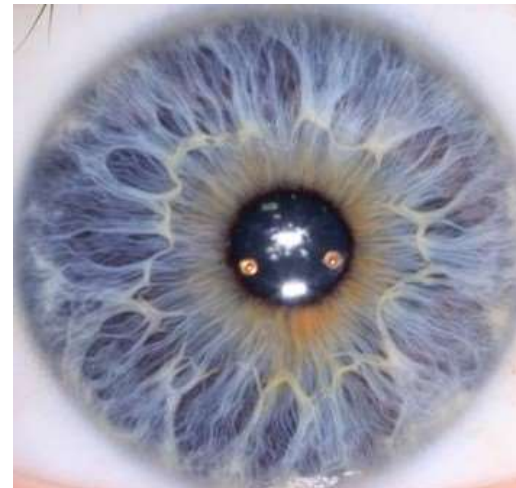
Very Resilient



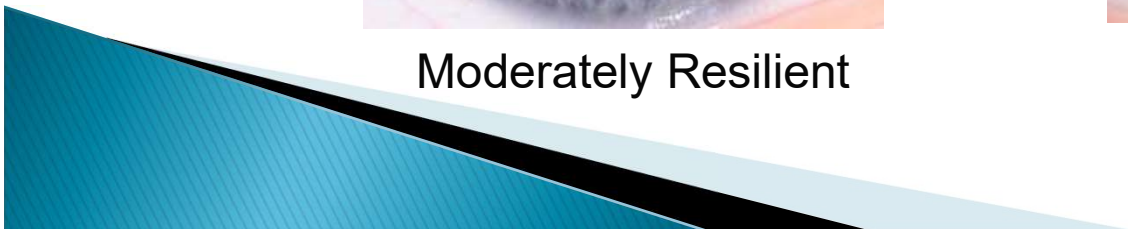
Resilient



Moderately Resilient



Least Resilient

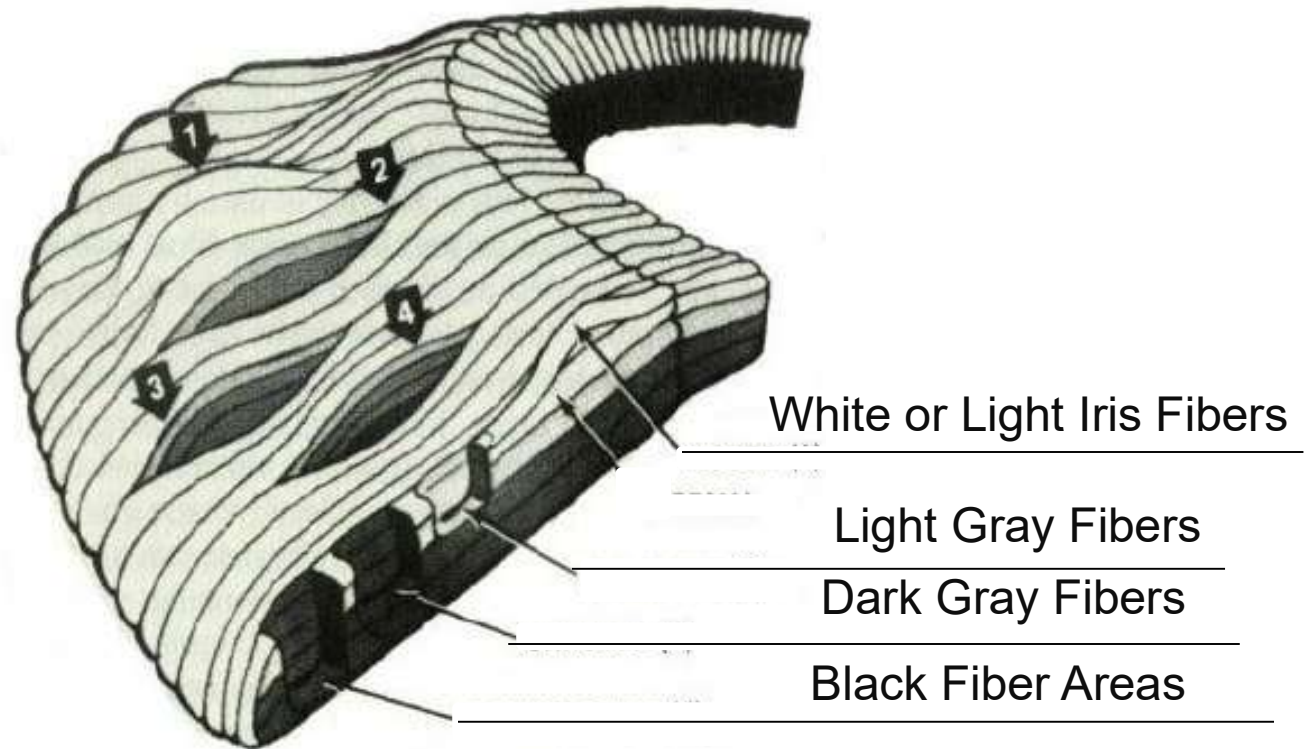




# Rating Constitution

Shading – From Light to Dark

1. White or Light Iris Fibers
2. Light Gray Fibers
3. Dark Gray Fibers
4. Black Fibers

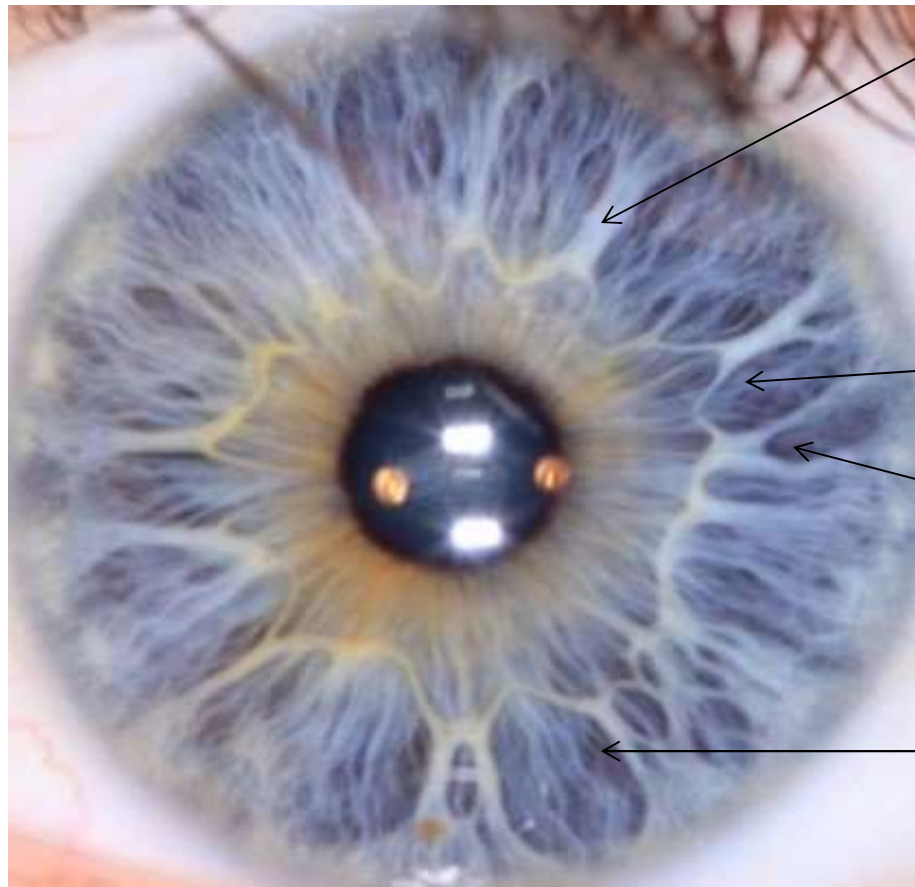


Shading = Reaction: The body's ability to react to illness



# Rating Constitution

Shading – From Light to Dark



White or  
Light Iris  
Fibers

White or  
Light Iris  
Fibers

Light Gray  
Fibers

Dark Gray  
Fibers

Black  
Fiber  
Areas

Light  
Gray  
Fibers

Black  
Fiber  
Areas

Dark  
Gray  
Fibers

Shading = Reaction: The body's ability to react to illness



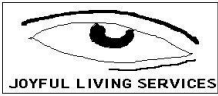

# Iris Signs to look for

Rarifications, Lacunae, Crypts, and Defect Signs are all genetic signs. They indicate a potential for deficiency, but may not be causing a problem at the moment.

- Radial Fibers or Trabeculae(e)
- Rarification or Rarefaction of Fibers
- Lacuna (e) types:
  - Open Lacuna
  - Closed Lacuna
  - Crypts
  - Defect Signs
- Cords
- Reflexive Signs
- Perifocal Lightening
- Transversals
  - Vascularized Transversals
  - Osseous Netting
  - Rooftop Transversals
  - Spleen/Heart Transversal
- Contraction Furrows
- Funnel
- Gateway Arch or Bridge
- Tophi
- Scurf Rim
- Circulatory Ring





# Iris Constitutional Subtypes by Color

Lymphatic	Biliary	Hematogenic
Overacid	Hydrogenoid	Ferrum Chromatose/Tiger Striping
Febrile	Ferrum Chromatose/Tiger Striping	Possible Elevated Blood Levels of Blood Pressure, Blood Sugar, and Elevated Cholesterol
Hydrogenoid	Scurf Rim	
Uric Acid		
Scurf Rim		


**Use general constitutional type nutrition information and then break it down further by subtype.**



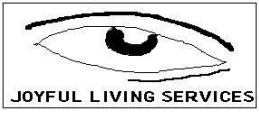

# Iris Constitutional Subtypes Based on Iris Structure

<b>Lymphatic</b>	<b>Biliary</b>	<b>Hematogenic</b>
Neurogenic	Neurogenic	Neurogenic
Anxiety Tetanic	Anxiety Tetanic	Anxiety Tetanic
Polyglandular	Polyglandular	Polyglandular
Connective Tissue	Connective Tissue	Connective Tissue

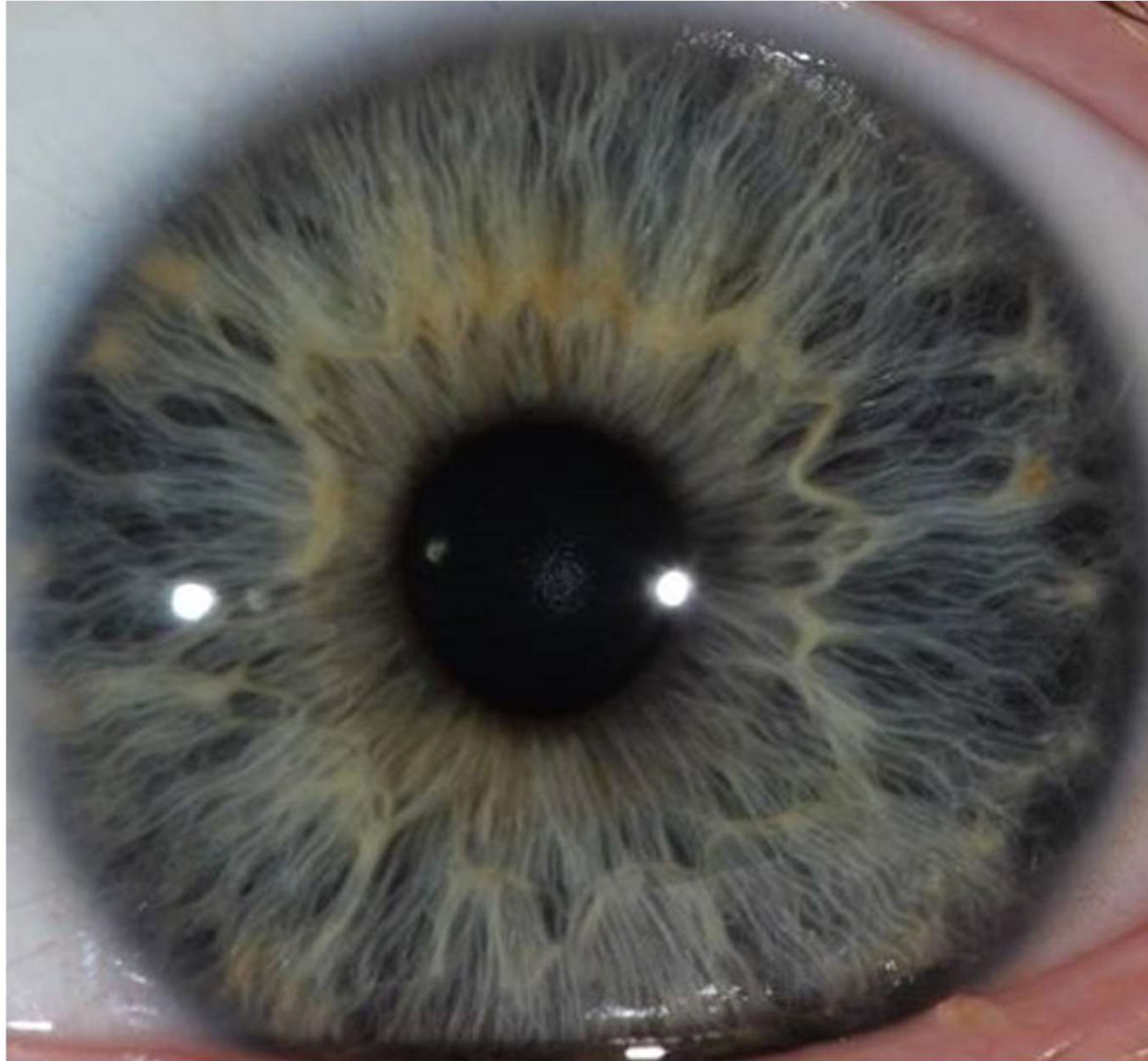


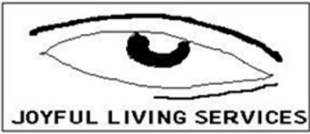


# Lymphatic Iris Constitution

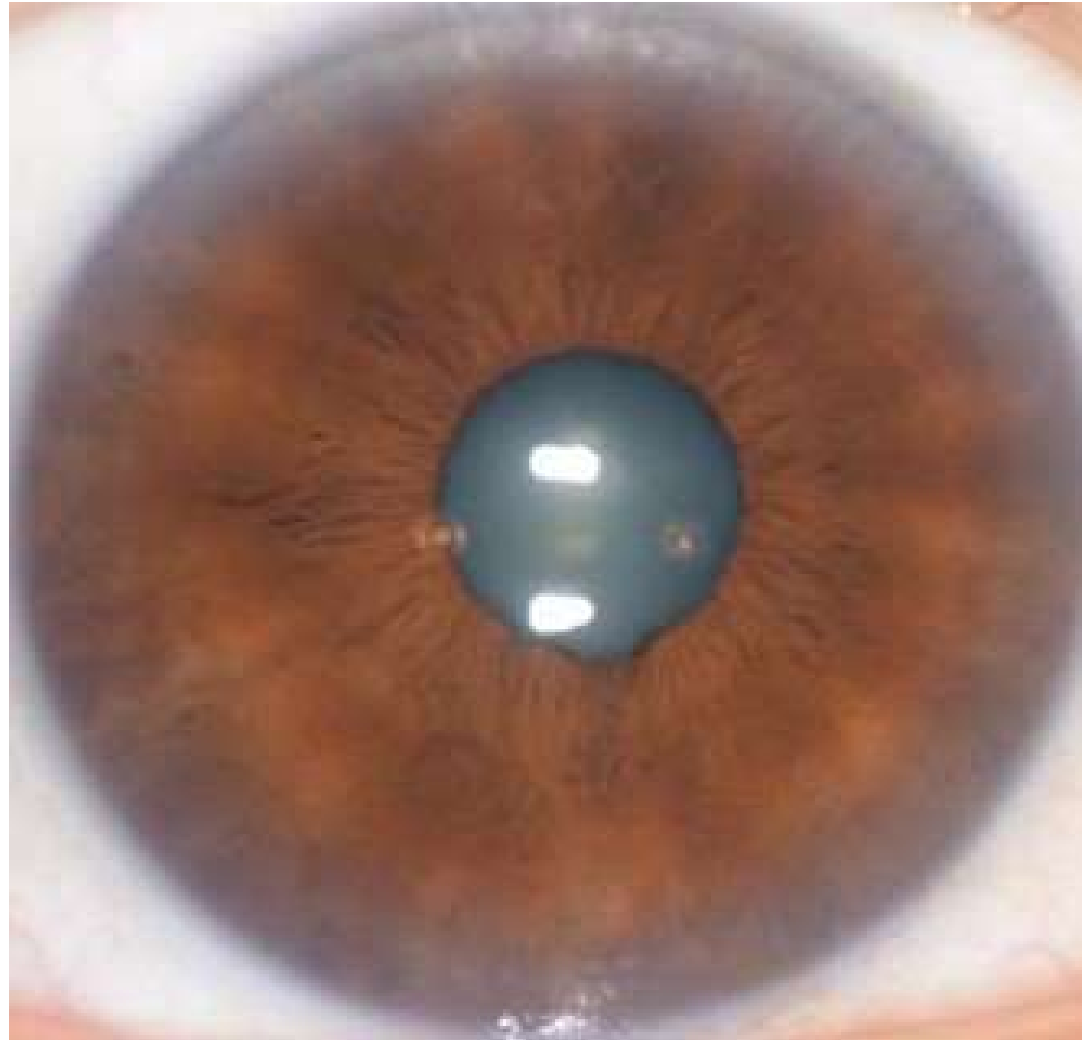
Iris 1 Subtype by Color and Structure?





# Hematogenic Iris Constitution

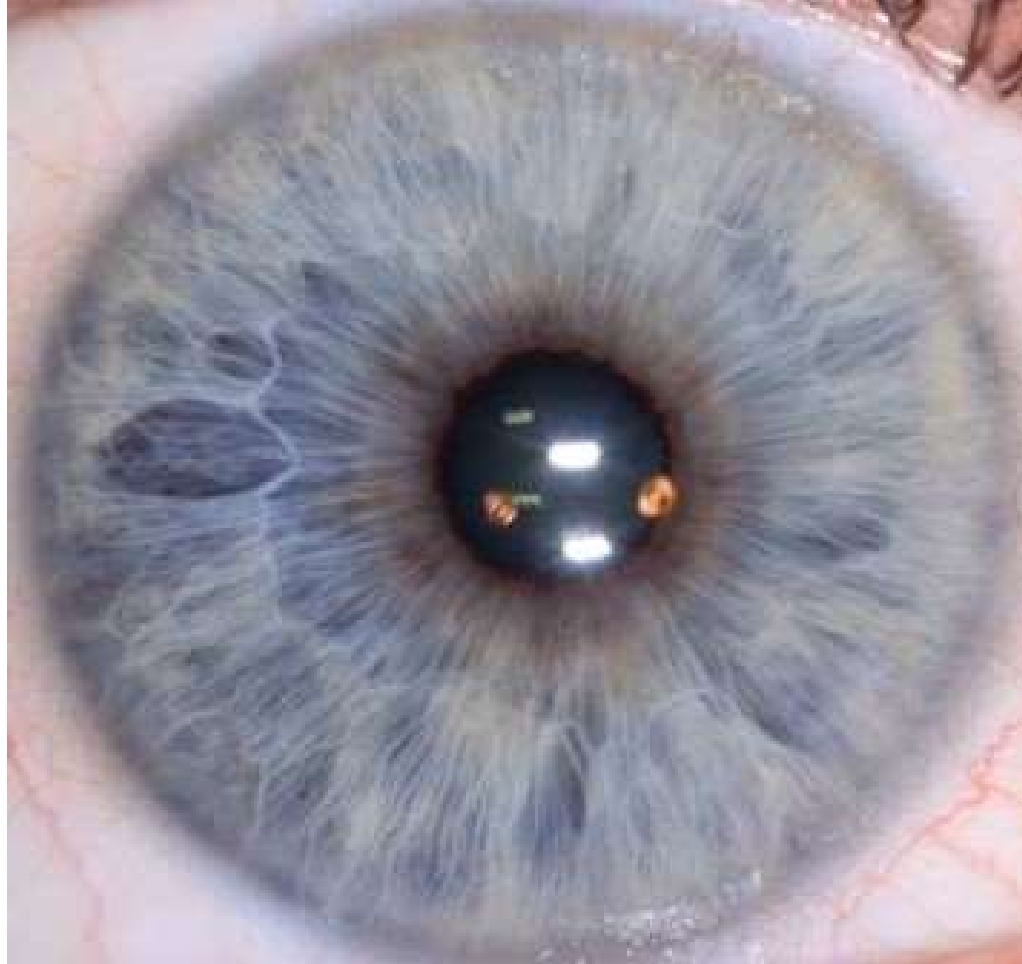
Iris 2 Subtype by Color and Structure?

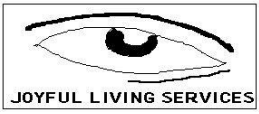



# Lymphatic Iris Constitution

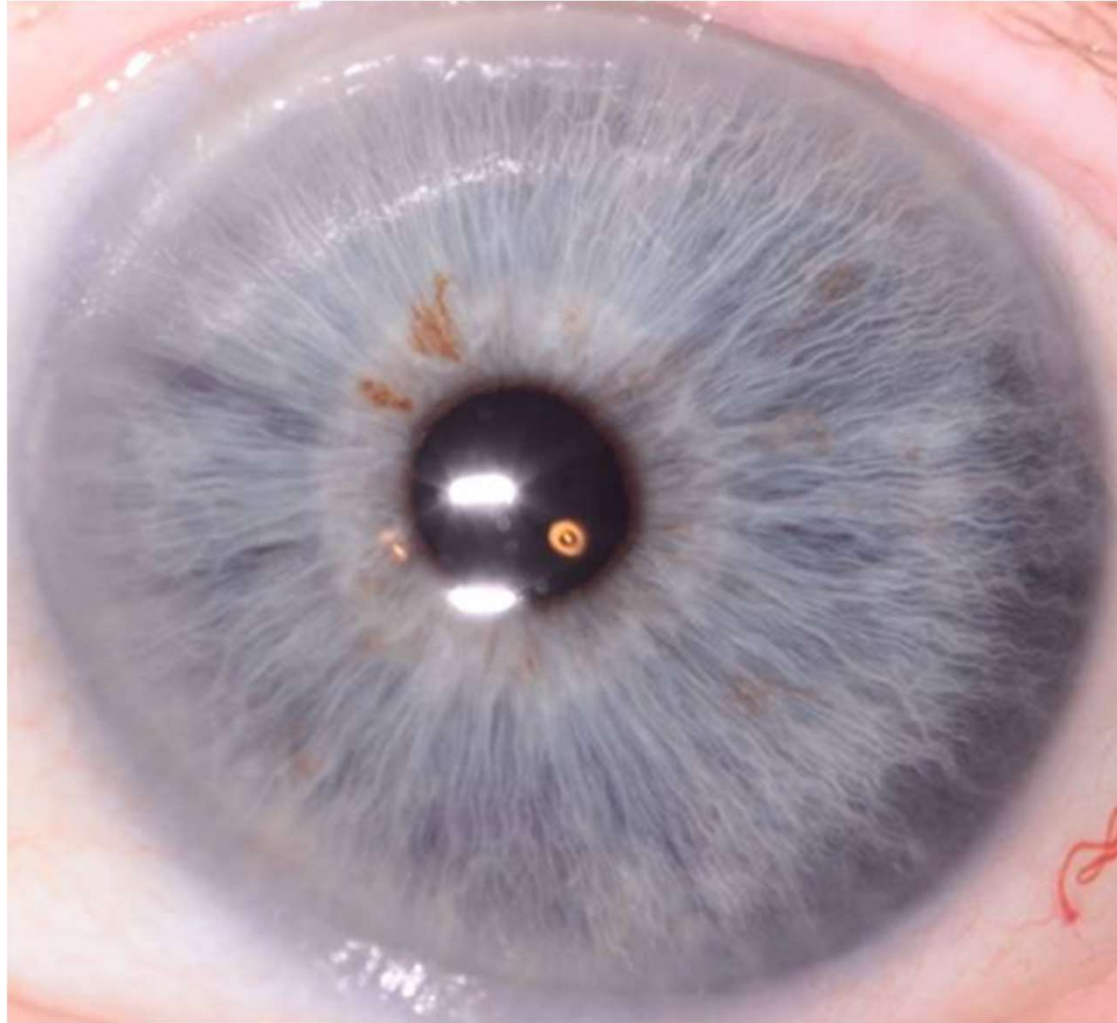
Iris 3 Subtype by Color and Structure?





# Lymphatic Iris Constitution

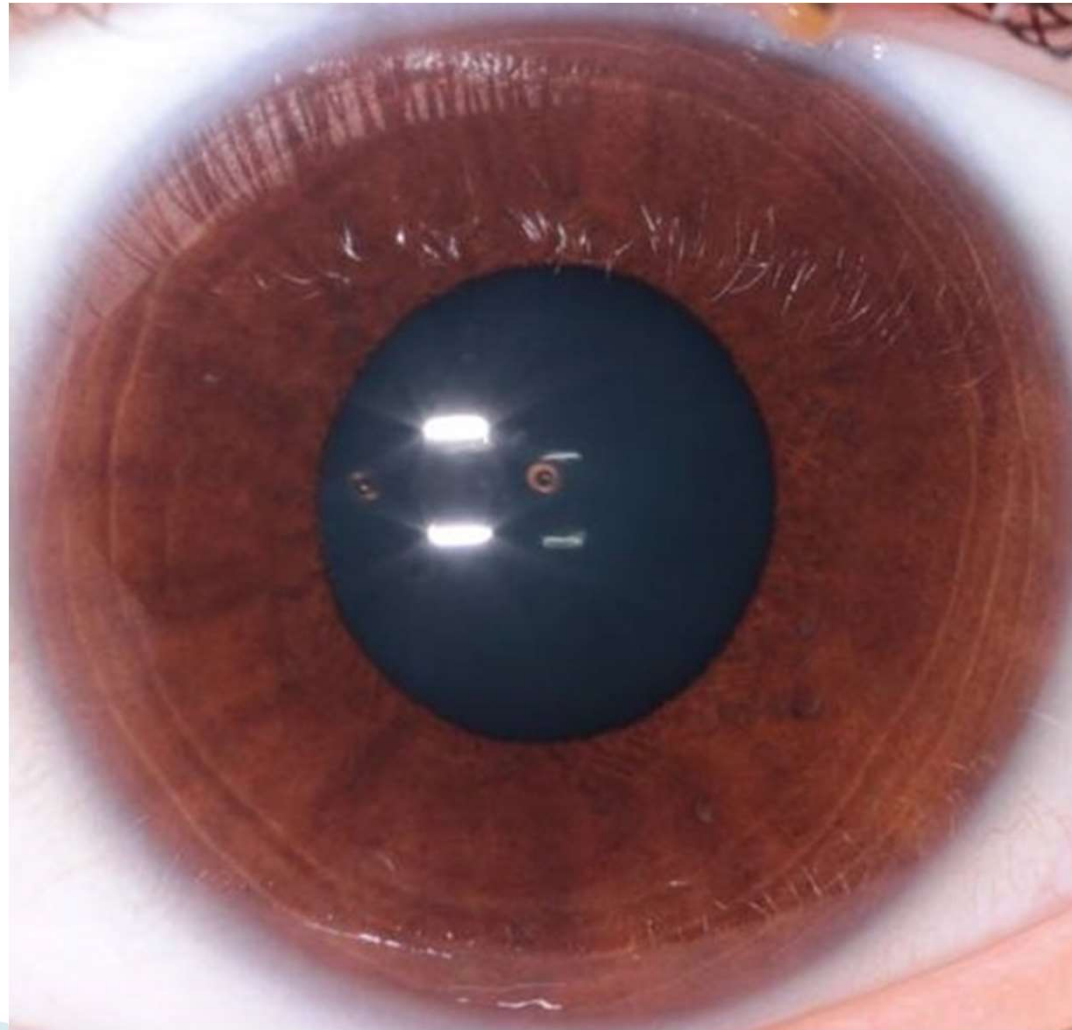
Iris 4 Subtype by Color and Structure?





# Hematogenic Iris Constitution

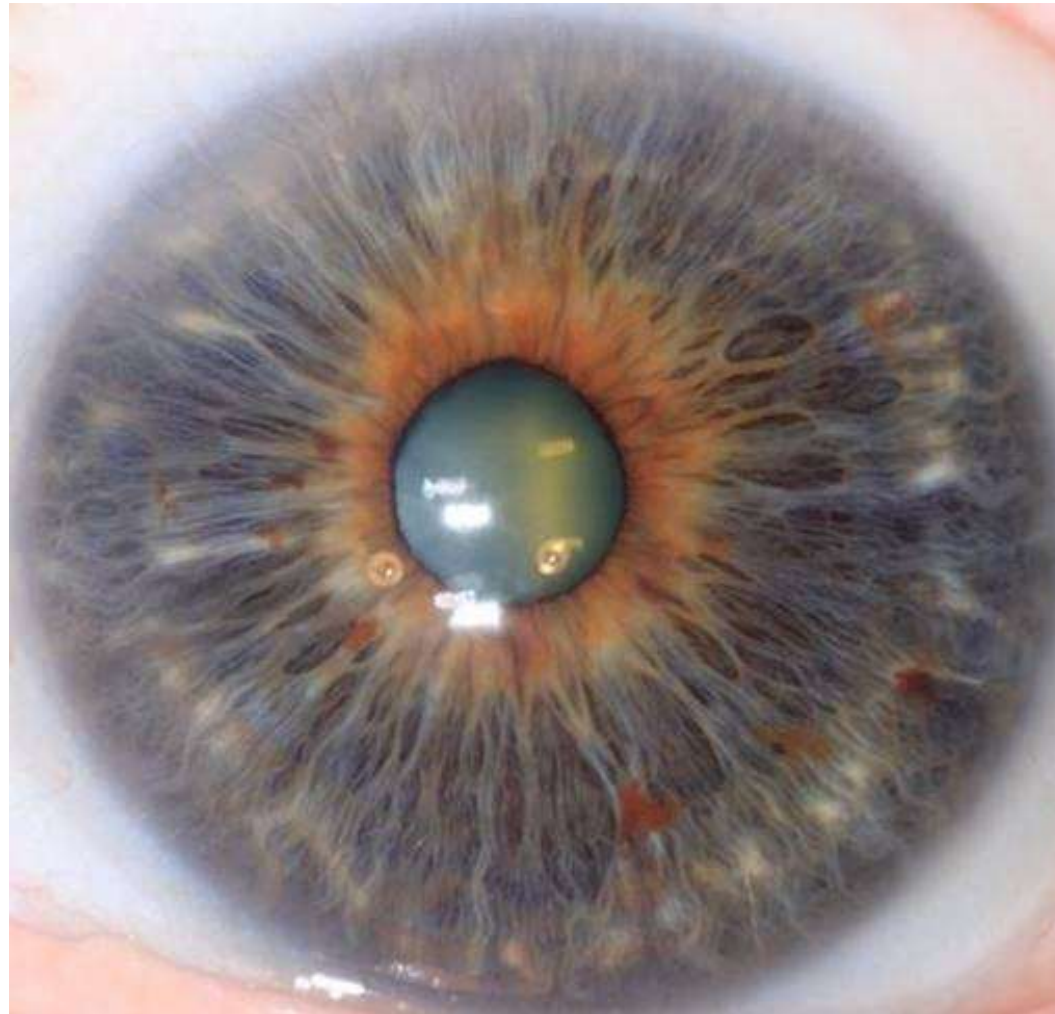
Iris 5 Subtype by Color and Structure?





# Lymphatic Iris Constitution

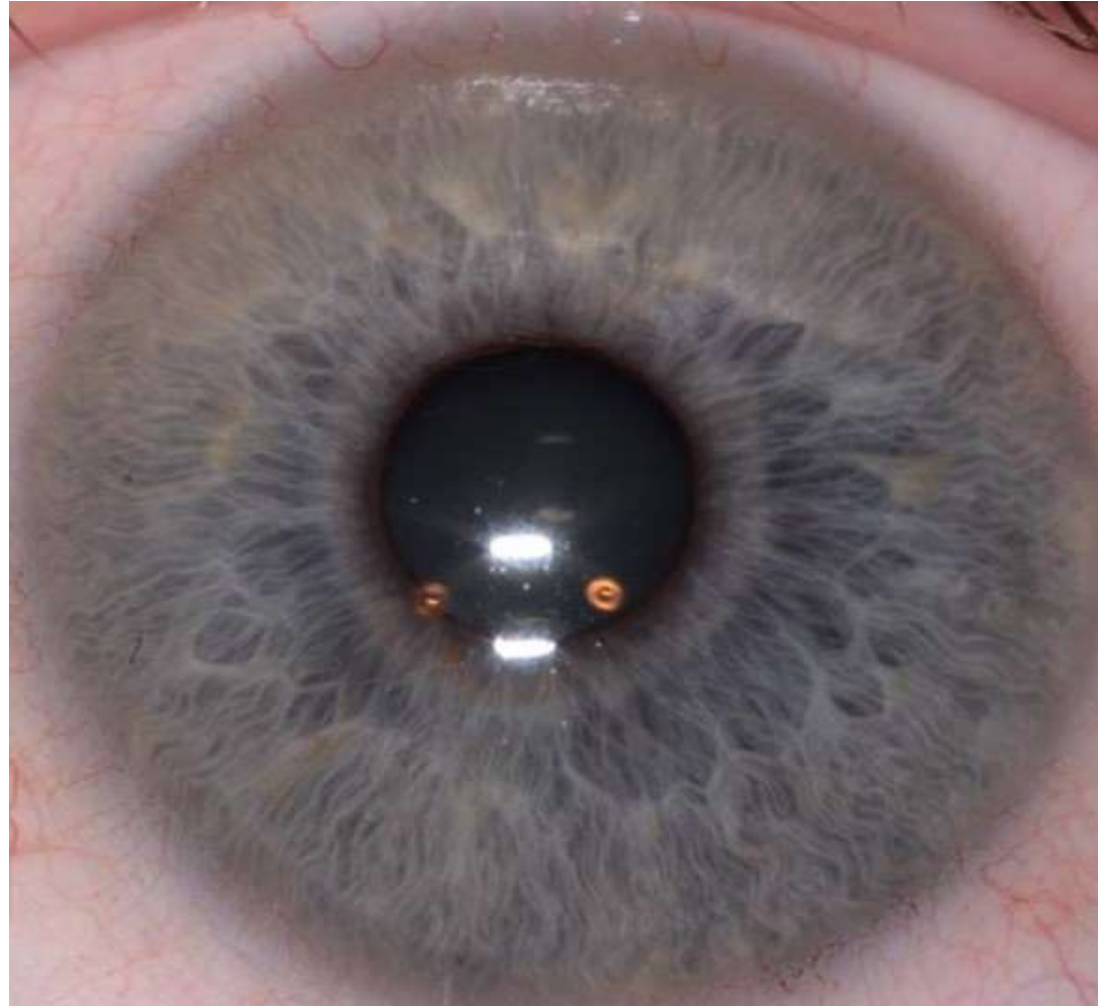
Iris 6 Subtype by Color and Structure?





# Lymphatic Iris Constitution

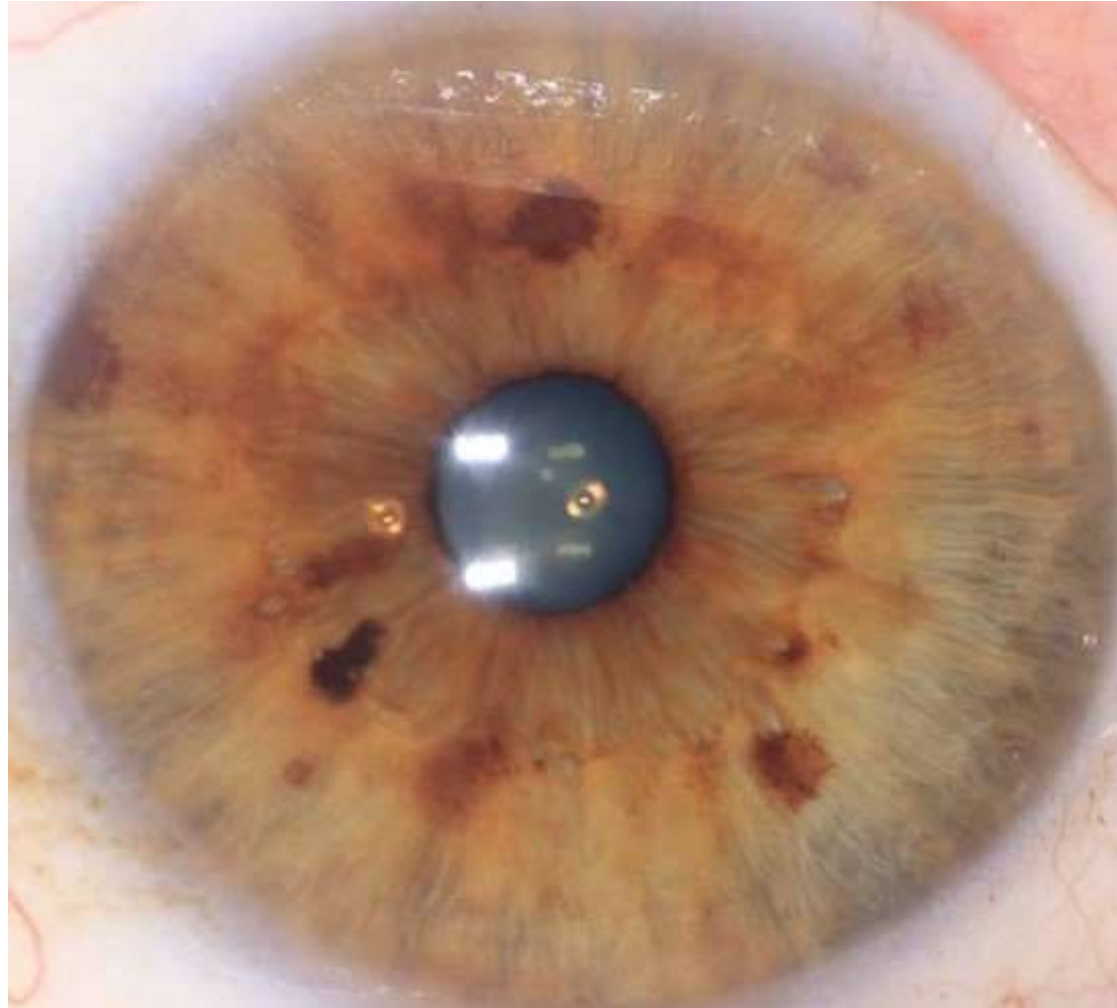
Iris 7 Subtype by Color and Structure?





# Mixed-Biliary Iris Constitution

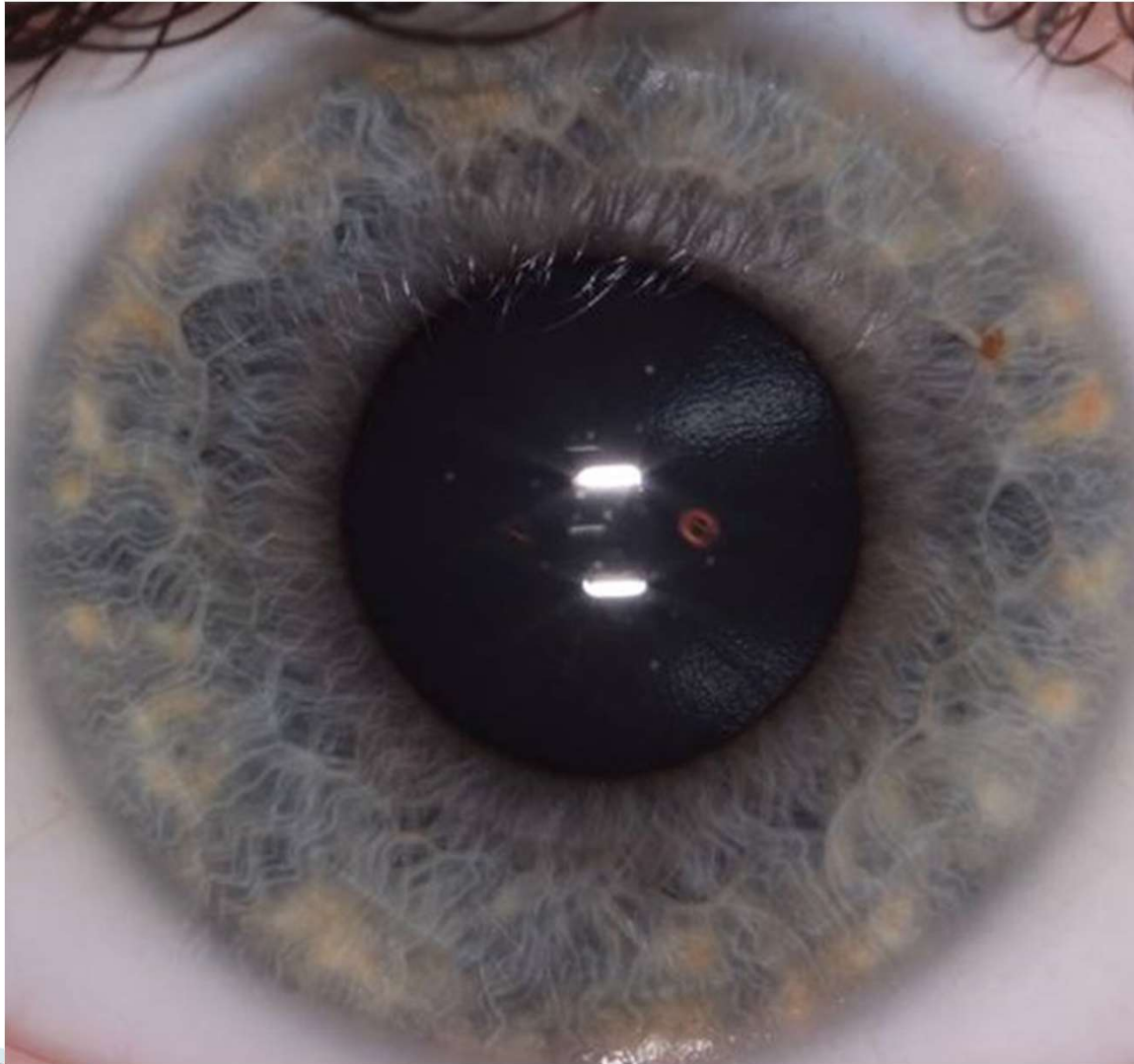
Iris 8 Subtype by Color and Structure?

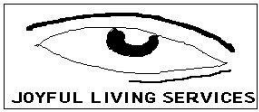



# Lymphatic Iris Constitution

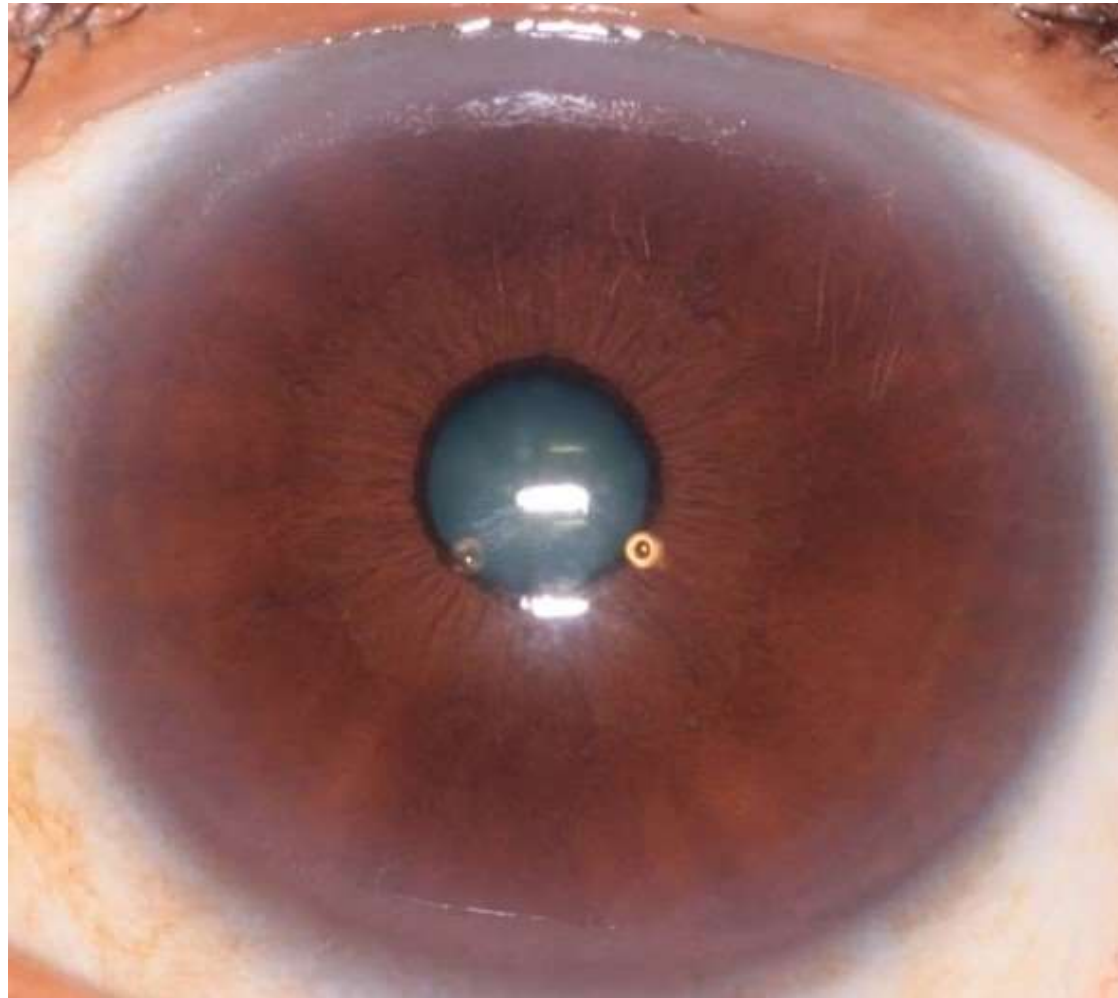
Iris 9 Subtype by Color and Structure?





# Hematogenic Iris Constitution

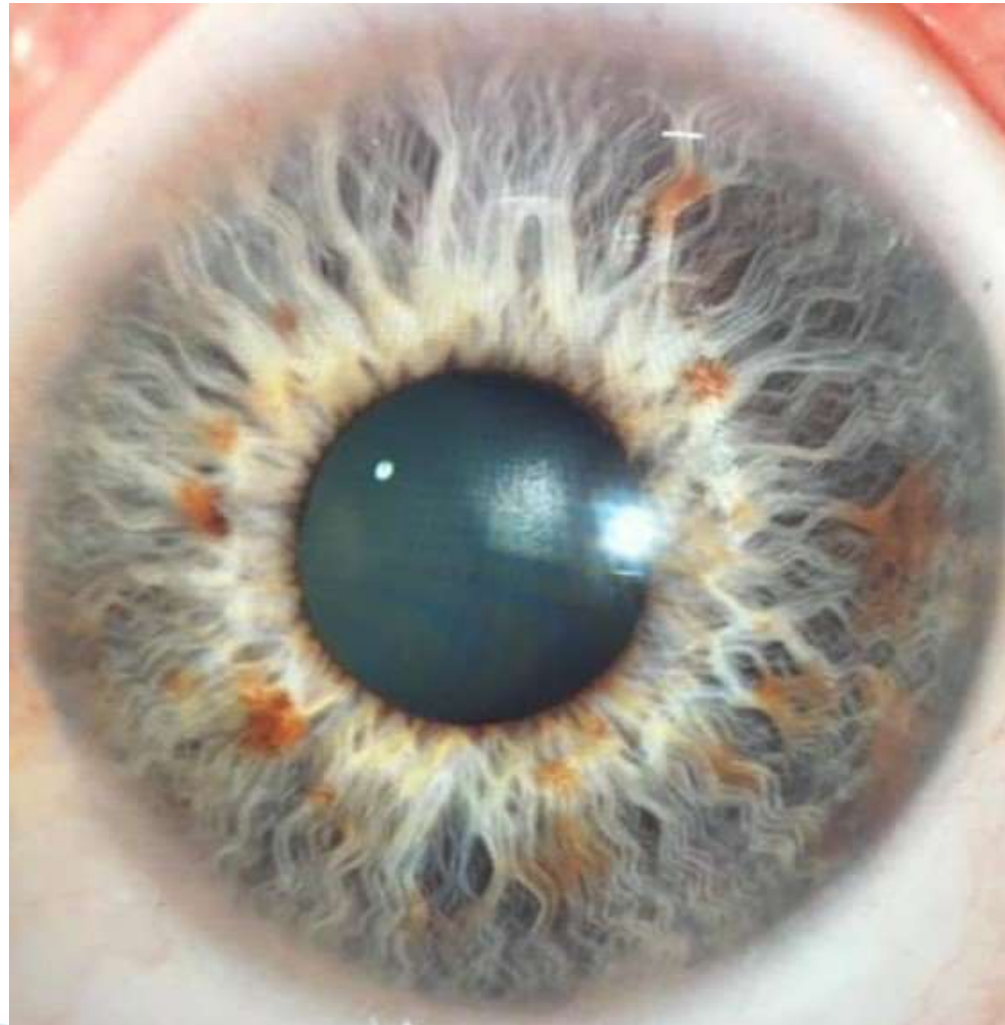Iris 10 Subtype by Color and Structure?





# Lymphatic Iris Constitution

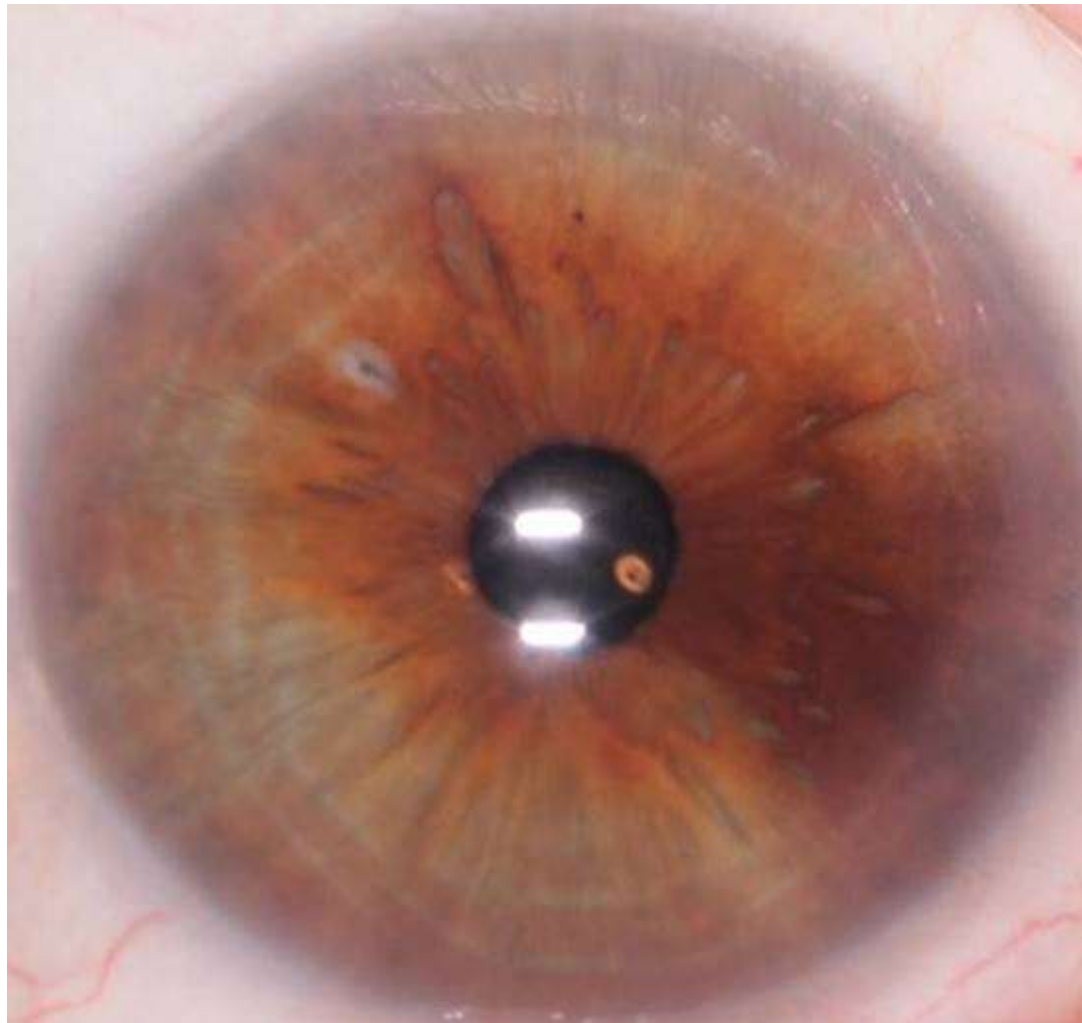
Iris 11 Subtype by Color and Structure?





# Mixed-Biliary Iris Constitution

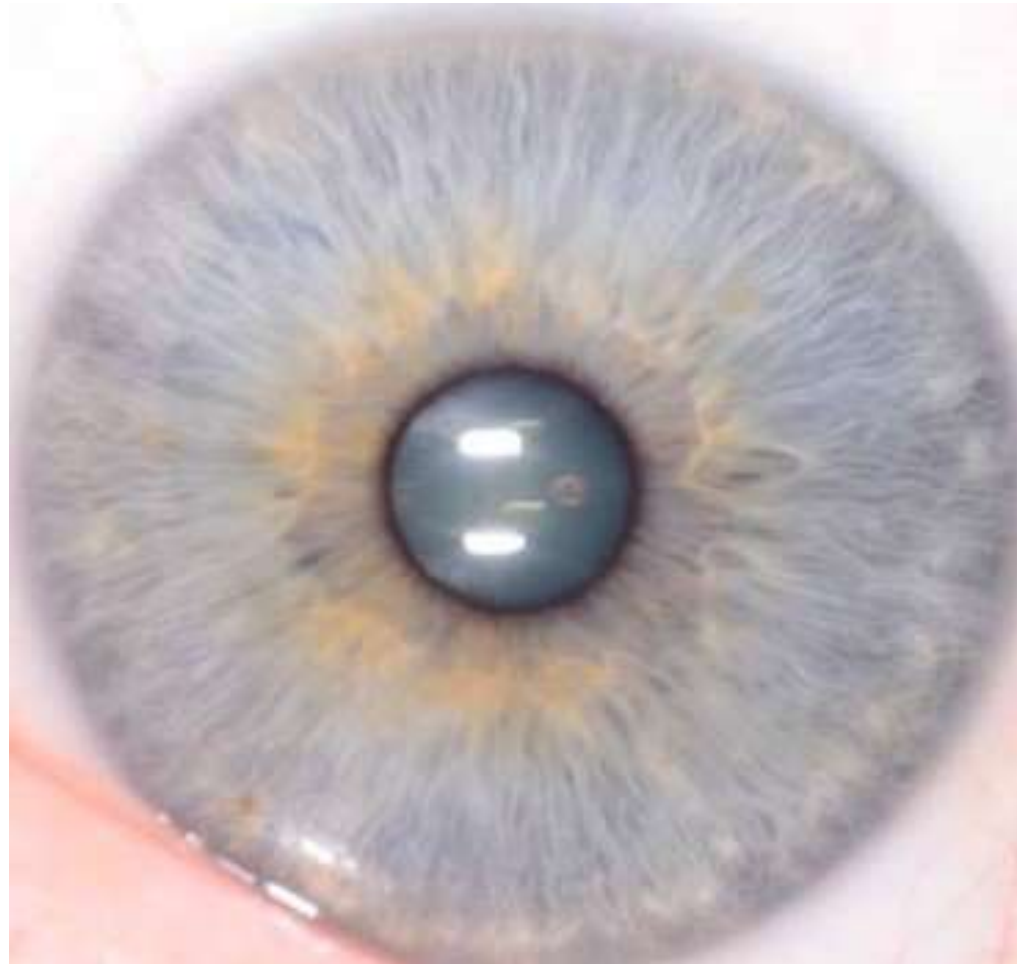Iris 12 Subtype by Color and Structure?





# Lymphatic Iris Constitution

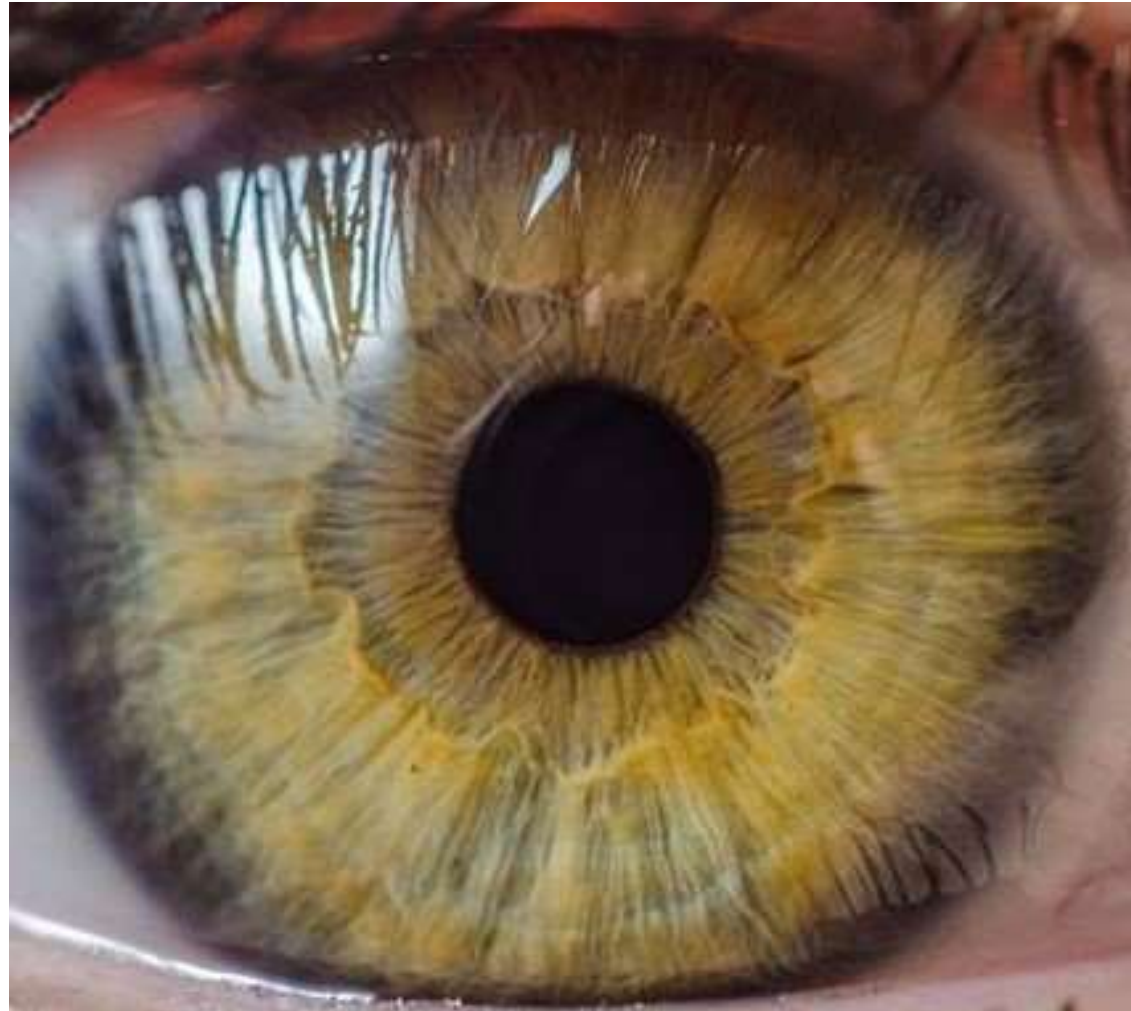
Iris 13 Subtype by Color and Structure?





# Mixed-Biliary Iris Constitution

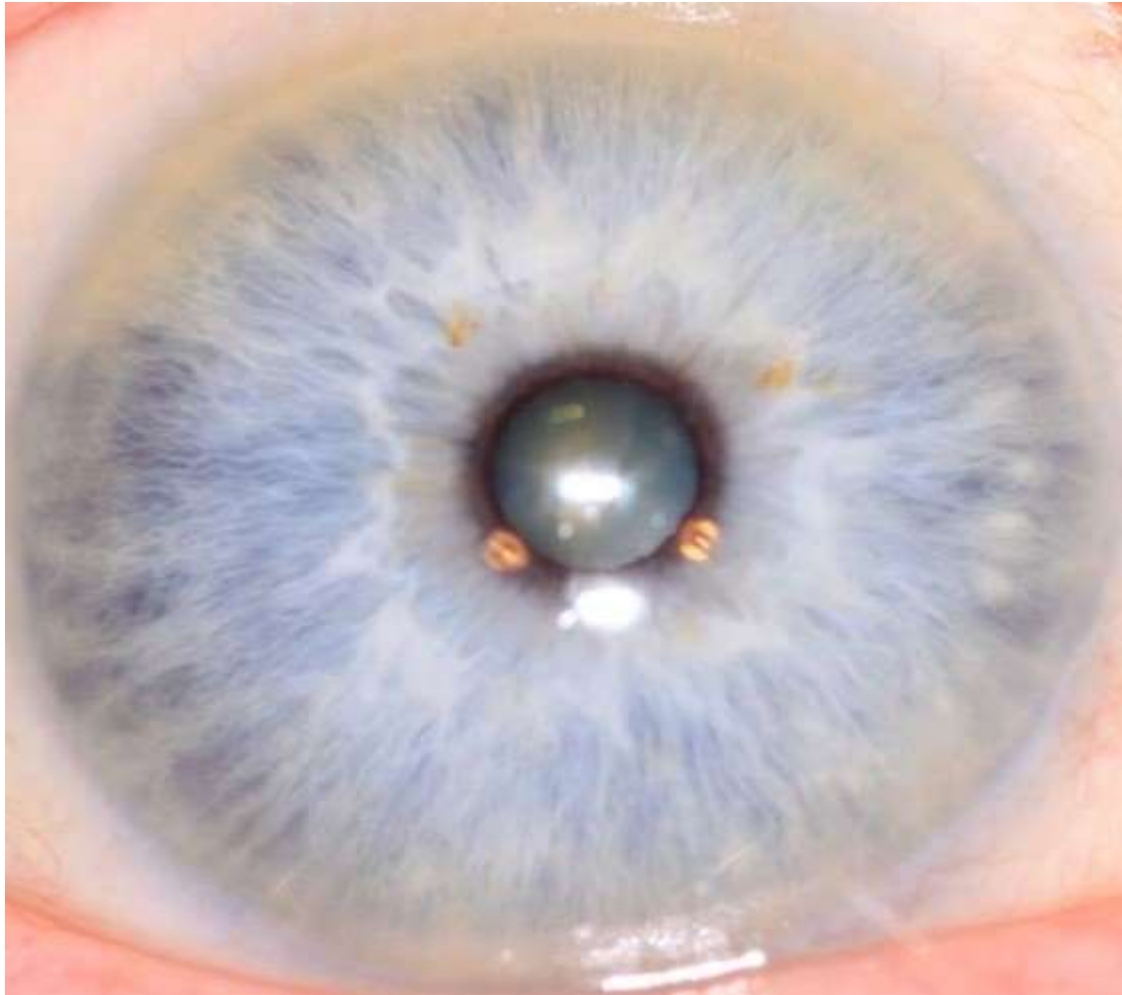Iris 14 Subtype by Color and Structure?





# Lymphatic Iris Constitution

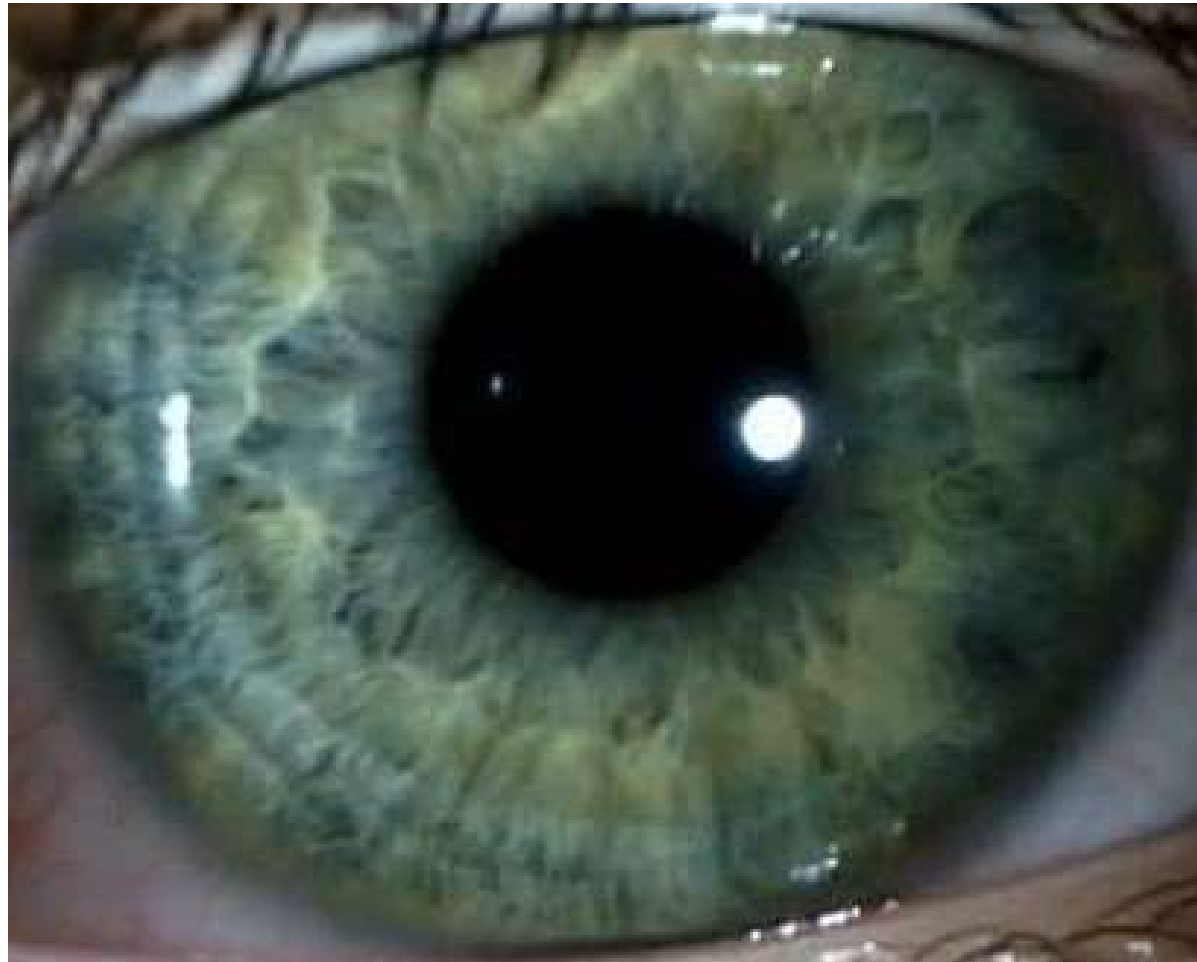
Iris 15 Subtype by Color and Structure?





# Lymphatic Iris Constitution

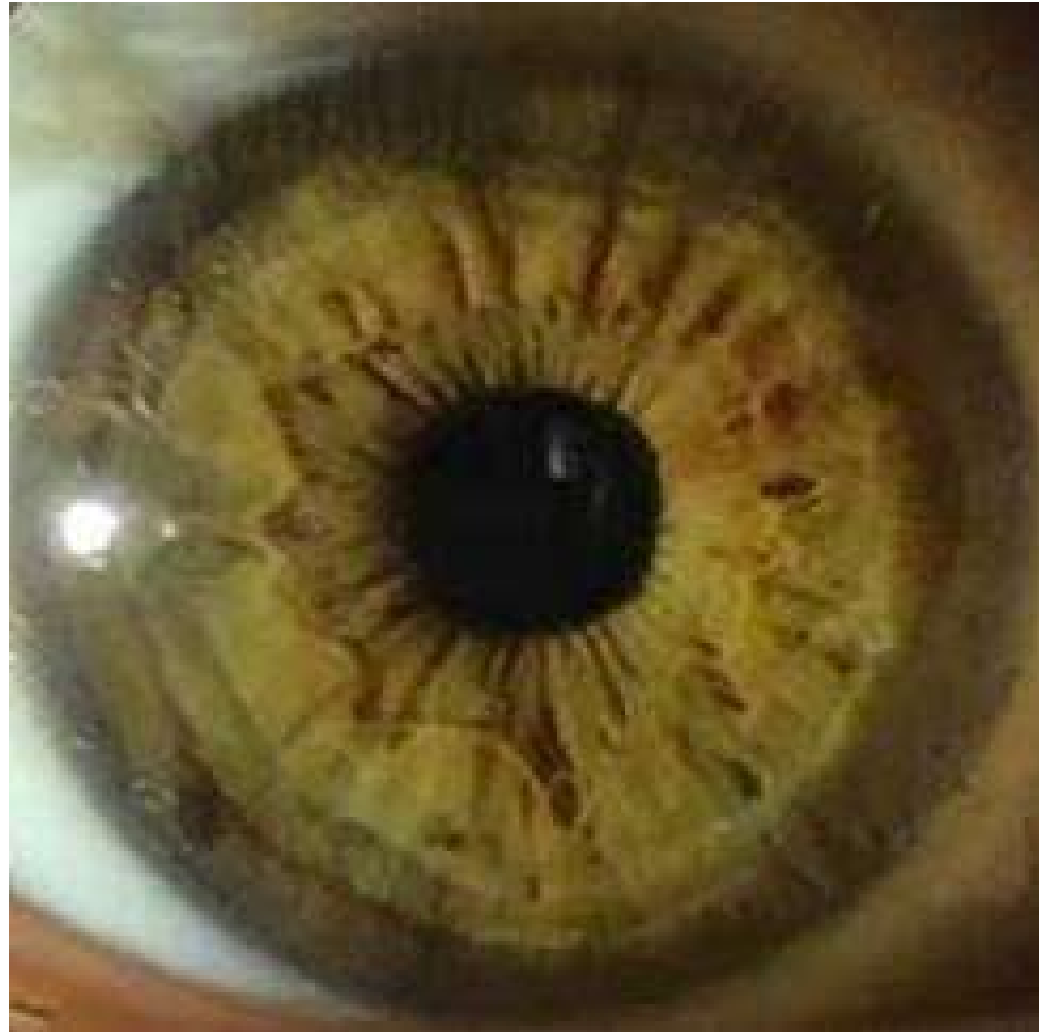
Iris 16 Subtype by Color and Structure?

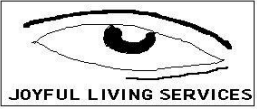



# Mixed-Biliary Iris Constitution

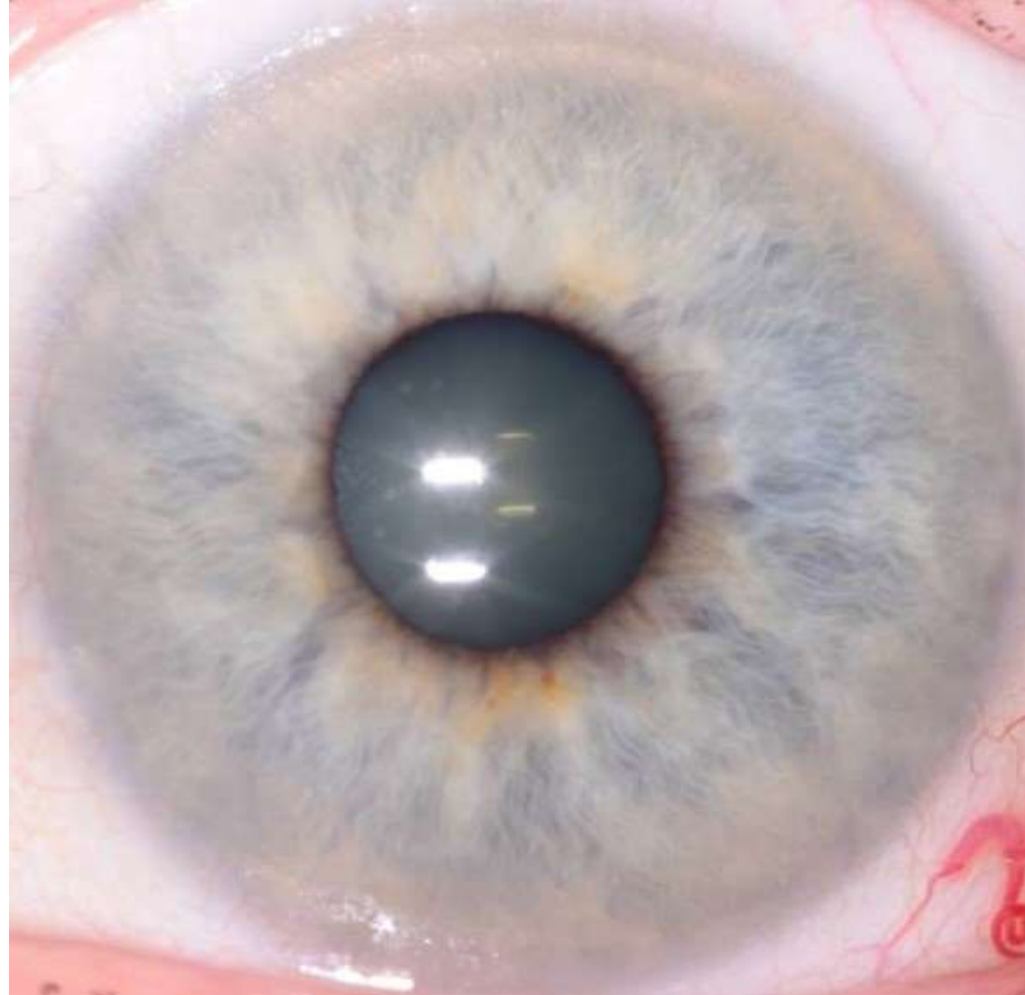
Iris 17 Subtype by Color and Structure?

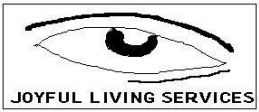



# Lymphatic Iris Constitution

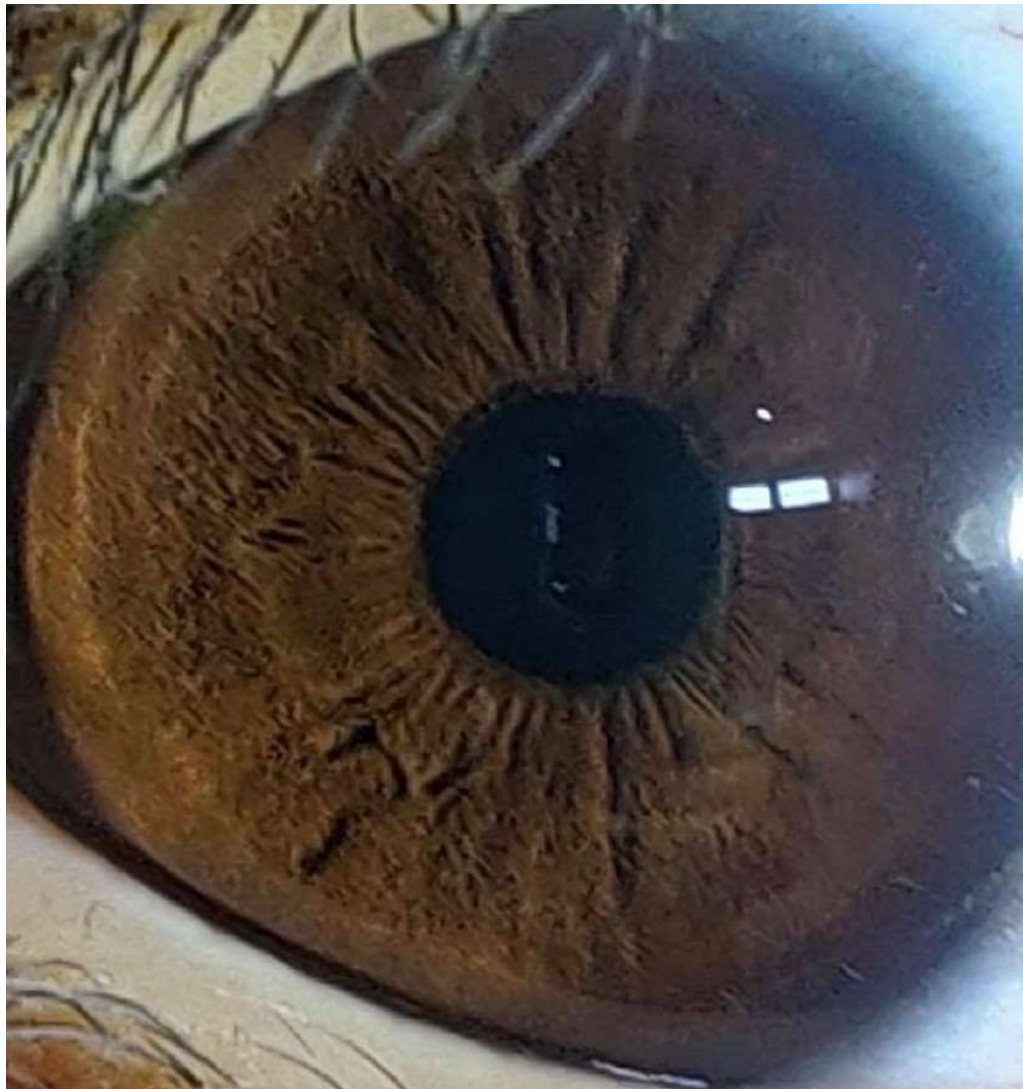
Iris 18 Subtype by Color and Structure?

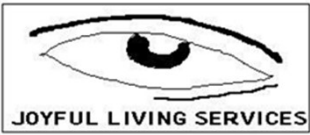



# Hematogenic Iris Constitution

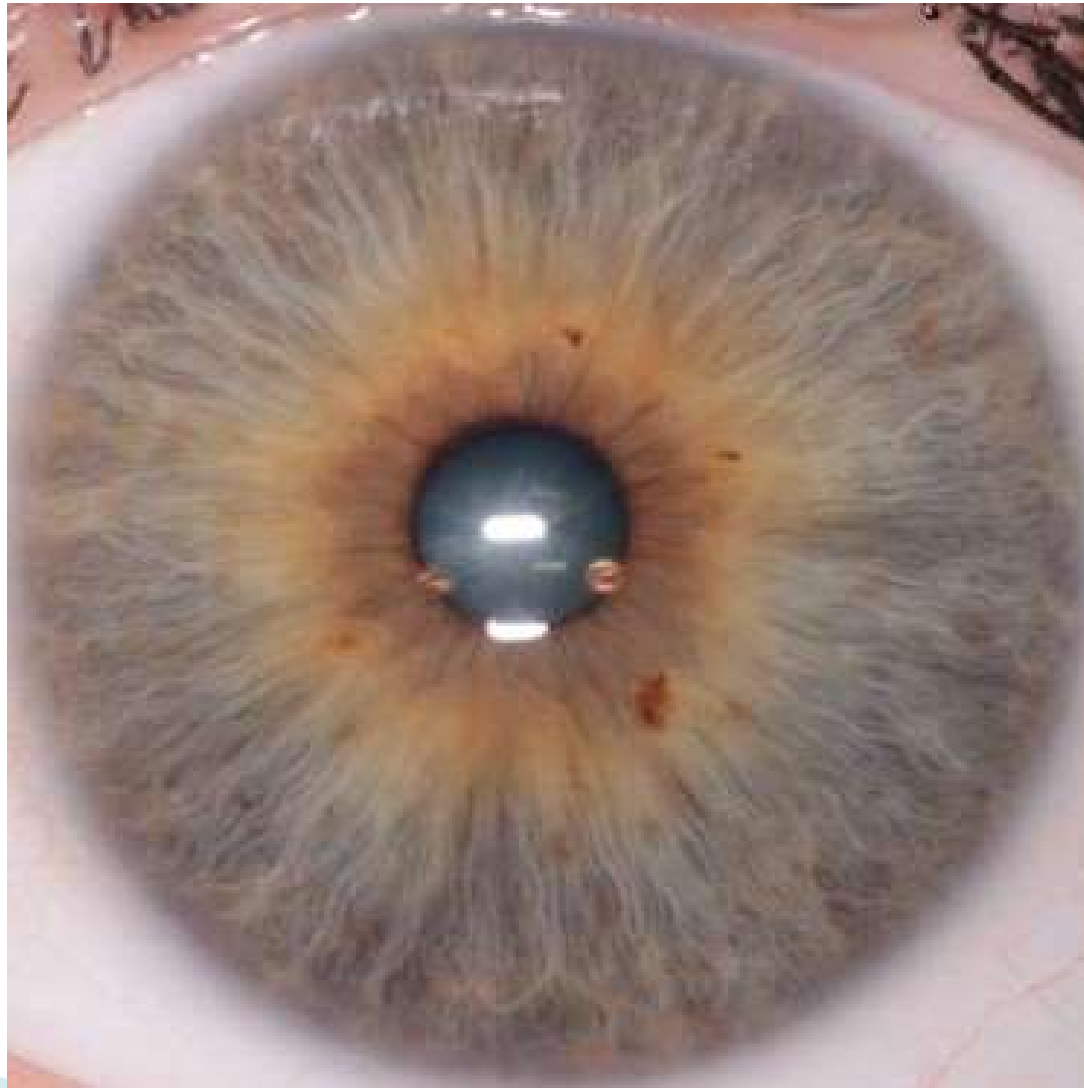
Iris 19 Subtype by Color and Structure?





# Lymphatic Iris Constitution

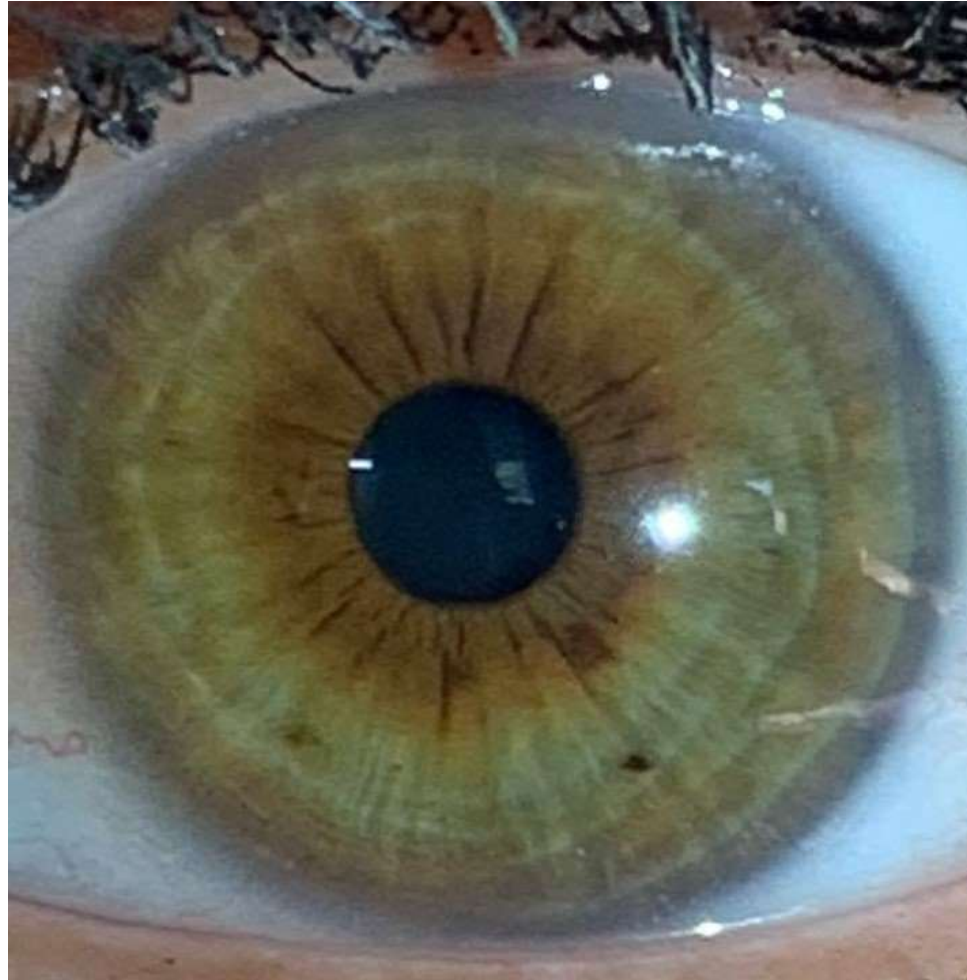
Iris 20 Subtype by Color and Structure?





# Mixed-Biliary Iris Constitution

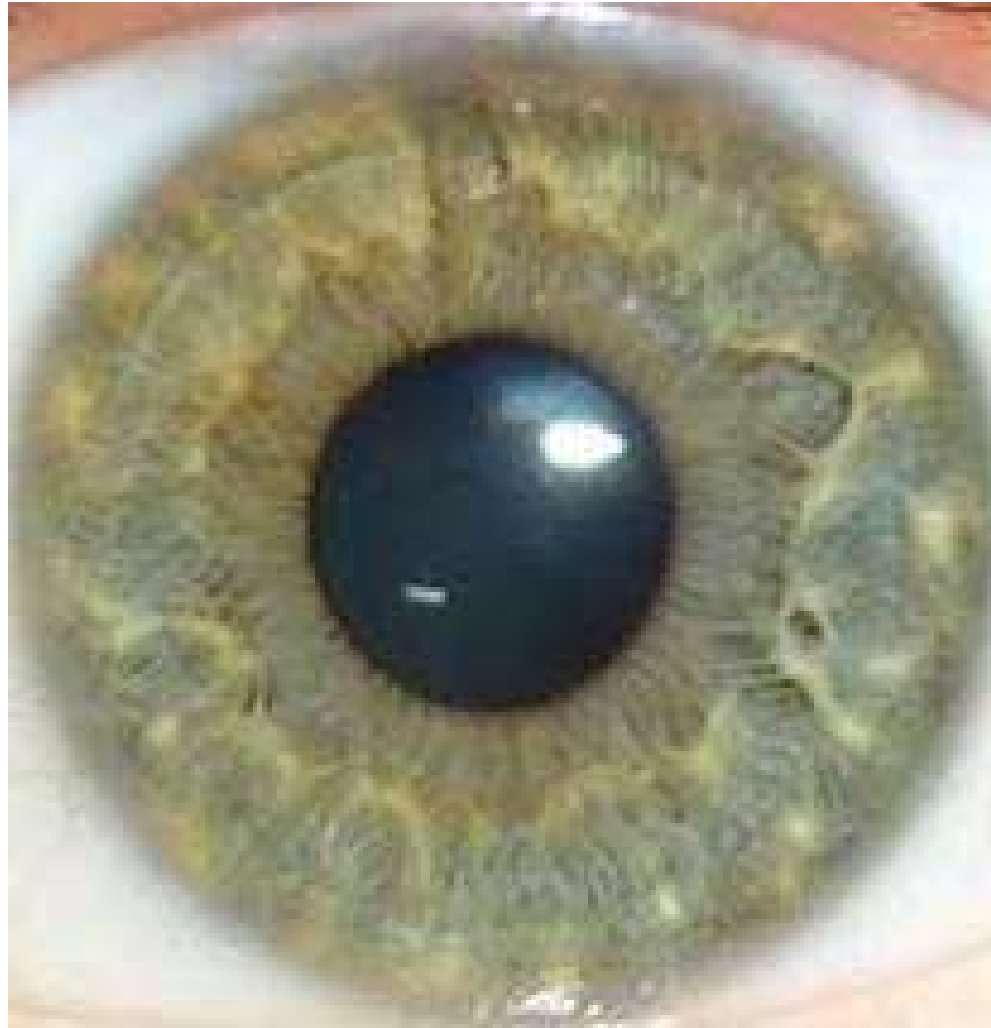Iris 21 Subtype by Color and Structure?





# Lymphatic Iris Constitution

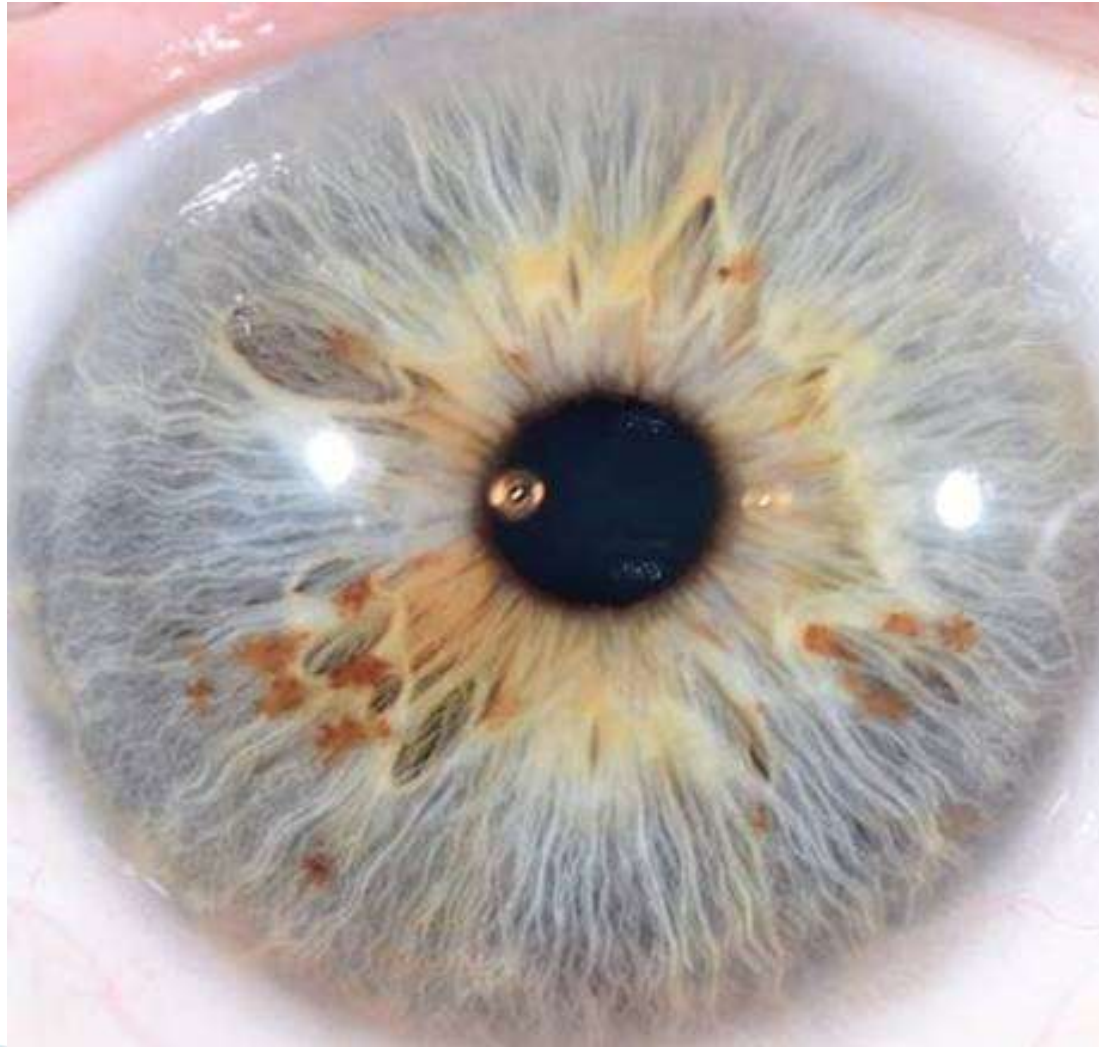
Iris 22 Subtype by Color and Structure?





# Lymphatic Iris Constitution

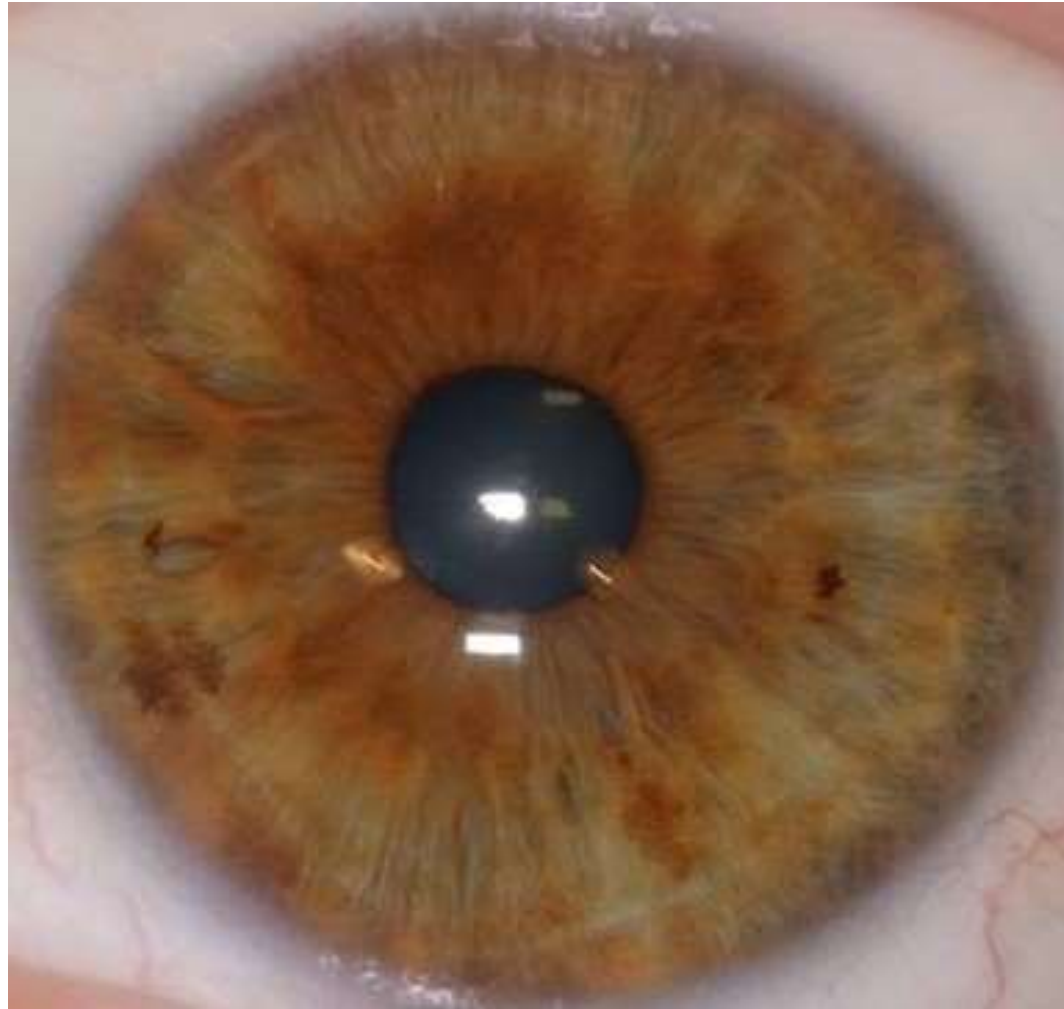Iris 23 Subtype by Color and Structure?





# Mixed-Biliary Iris Constitution


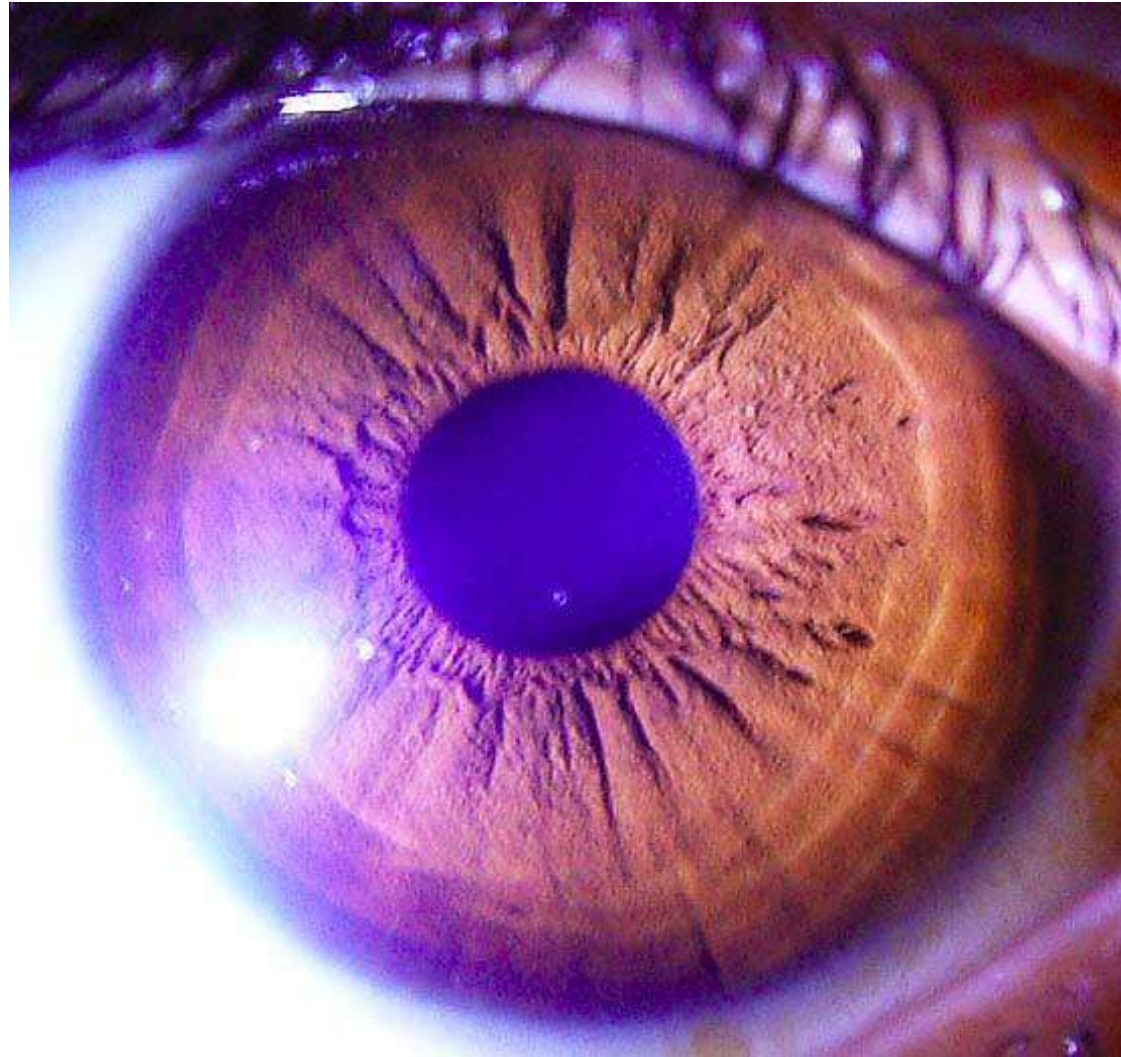
Iris 24 Subtype by Color and Structure?





# Hematogenic Iris Constitution

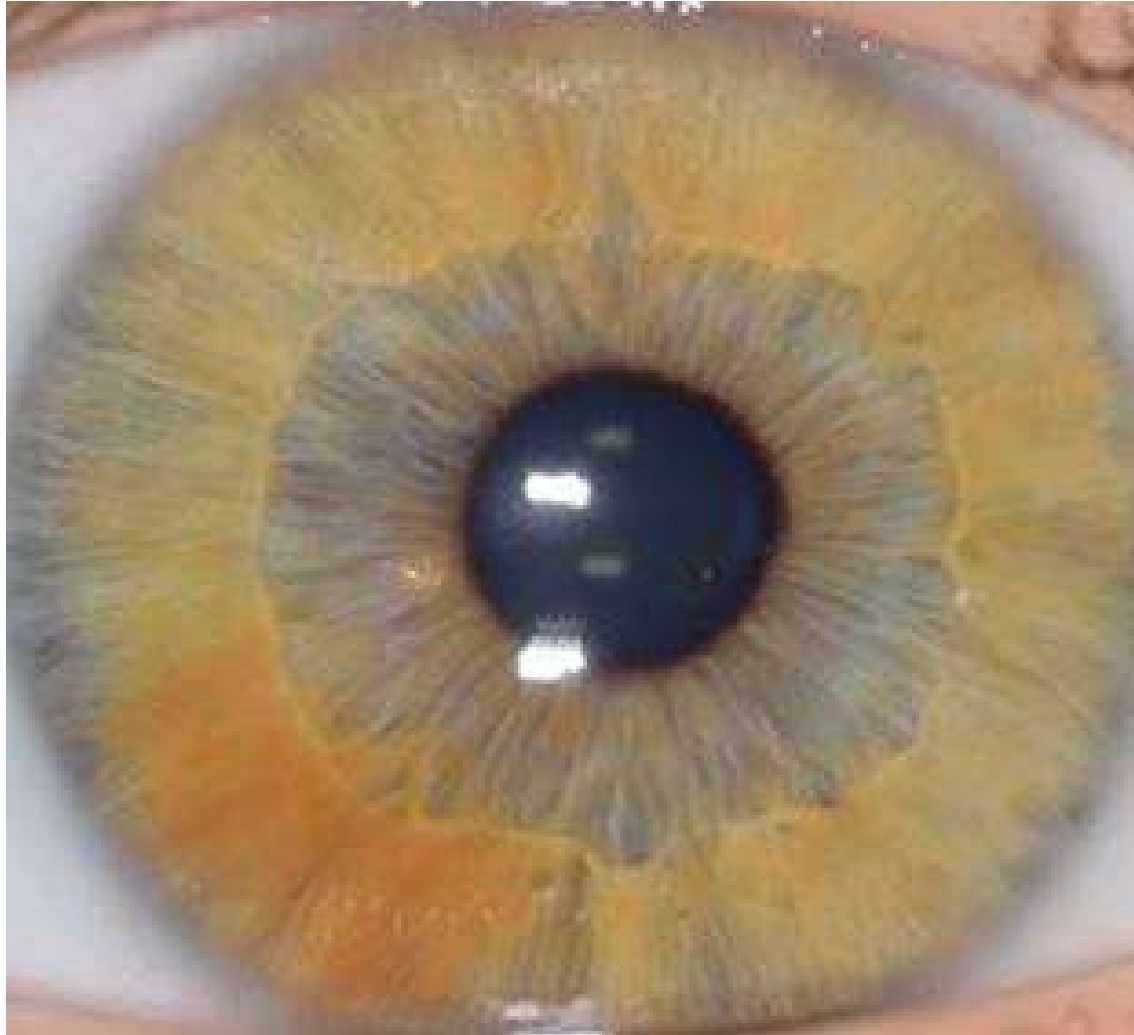
Iris 25 Subtype by Color and Structure?





# Mixed-Biliary Iris Constitution

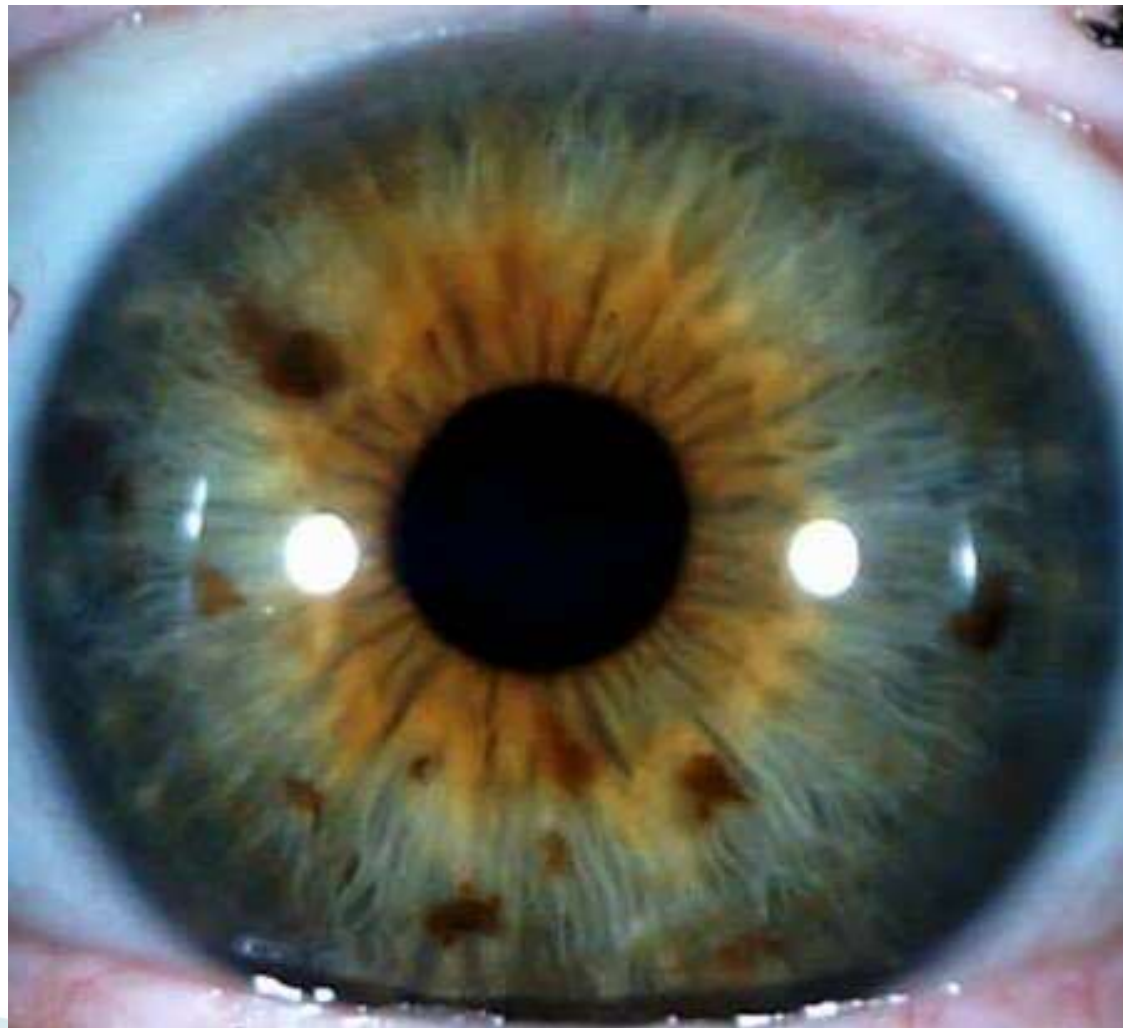
Iris 26 Subtype by Color and Structure?





# Lymphatic Iris Constitution

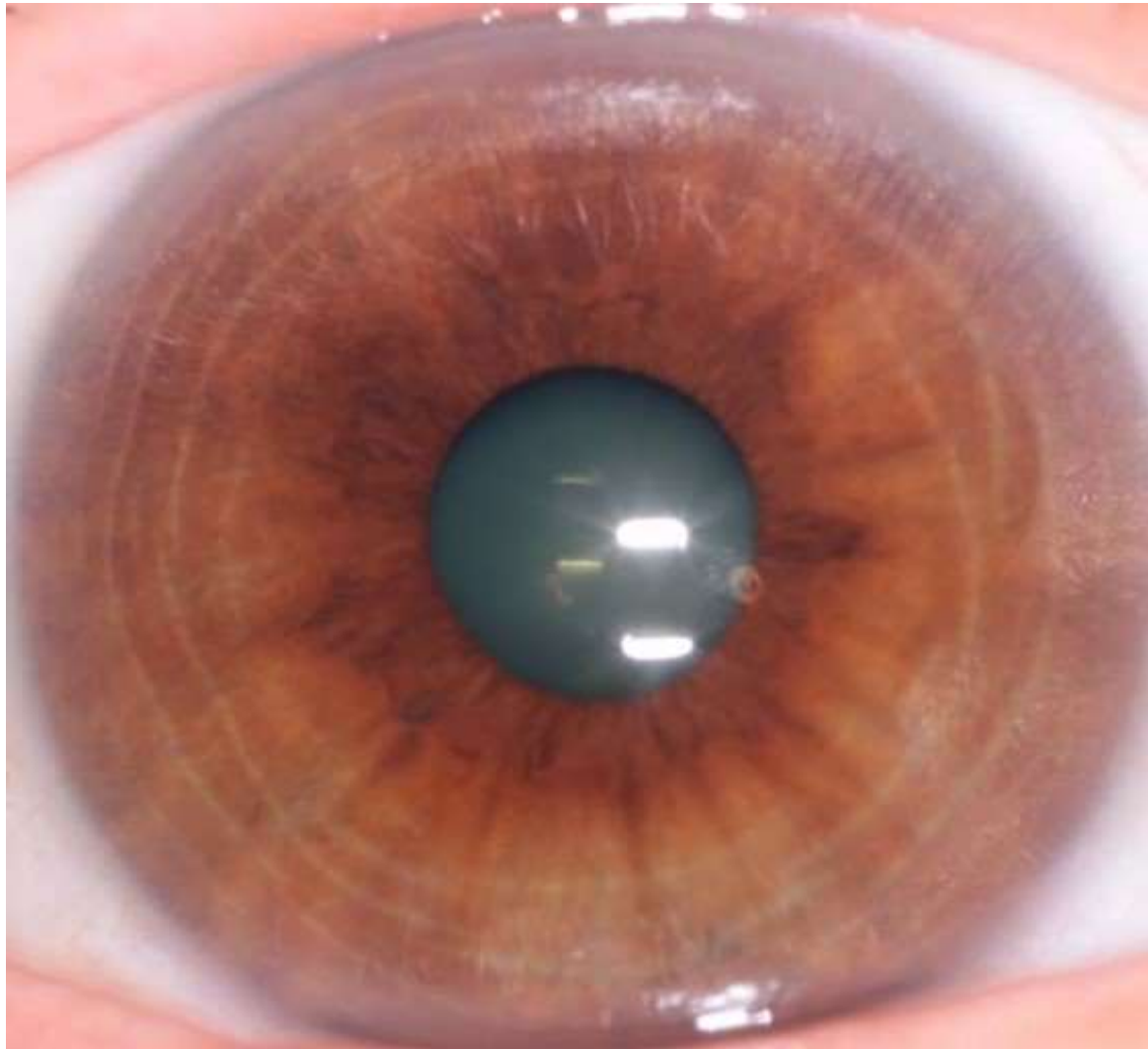
Iris 27 Subtype by Color and Structure?





# Mixed-Biliary Iris Constitution

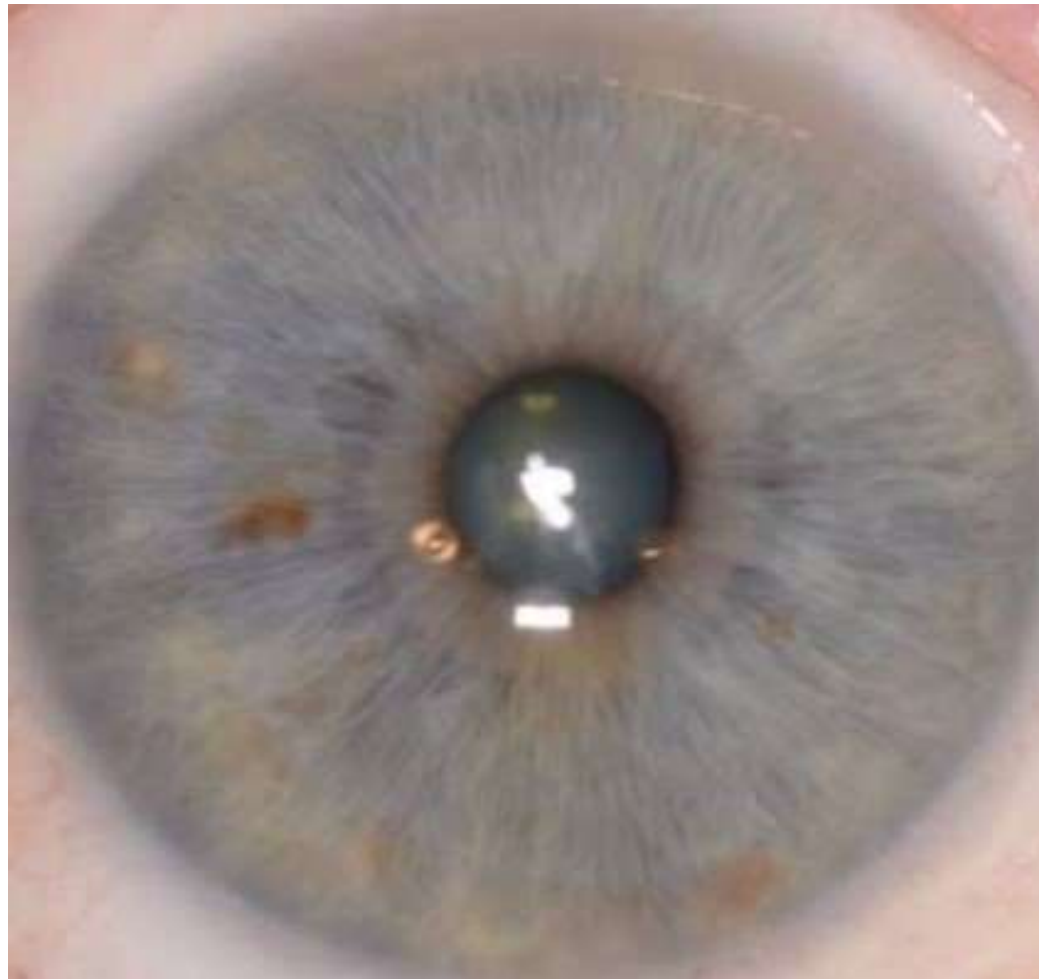
Iris 28 Subtype by Color and Structure?





# Lymphatic Iris Constitution

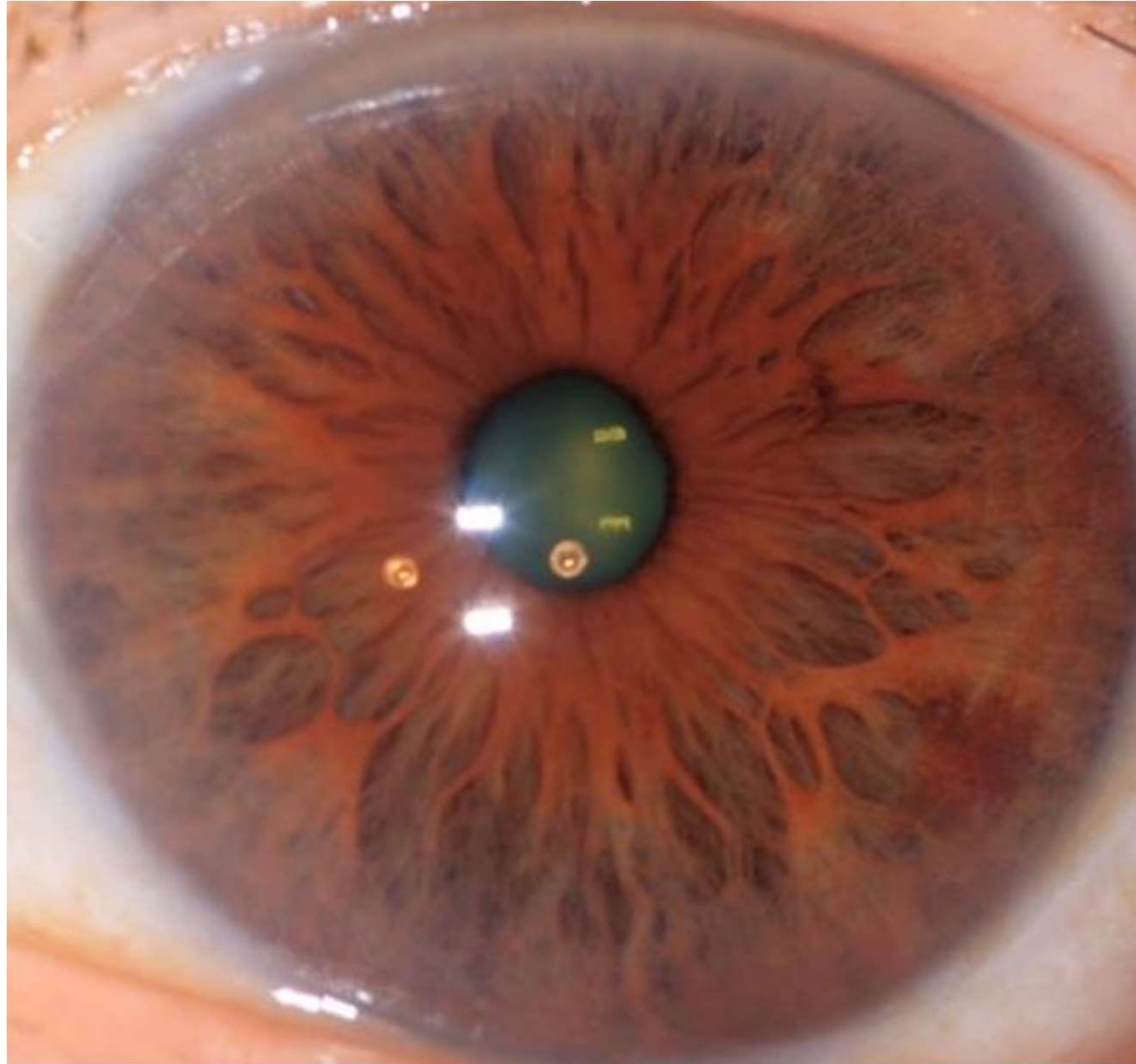
Iris 29 Subtype by Color and Structure?





# Mixed-Biliary Iris Constitution

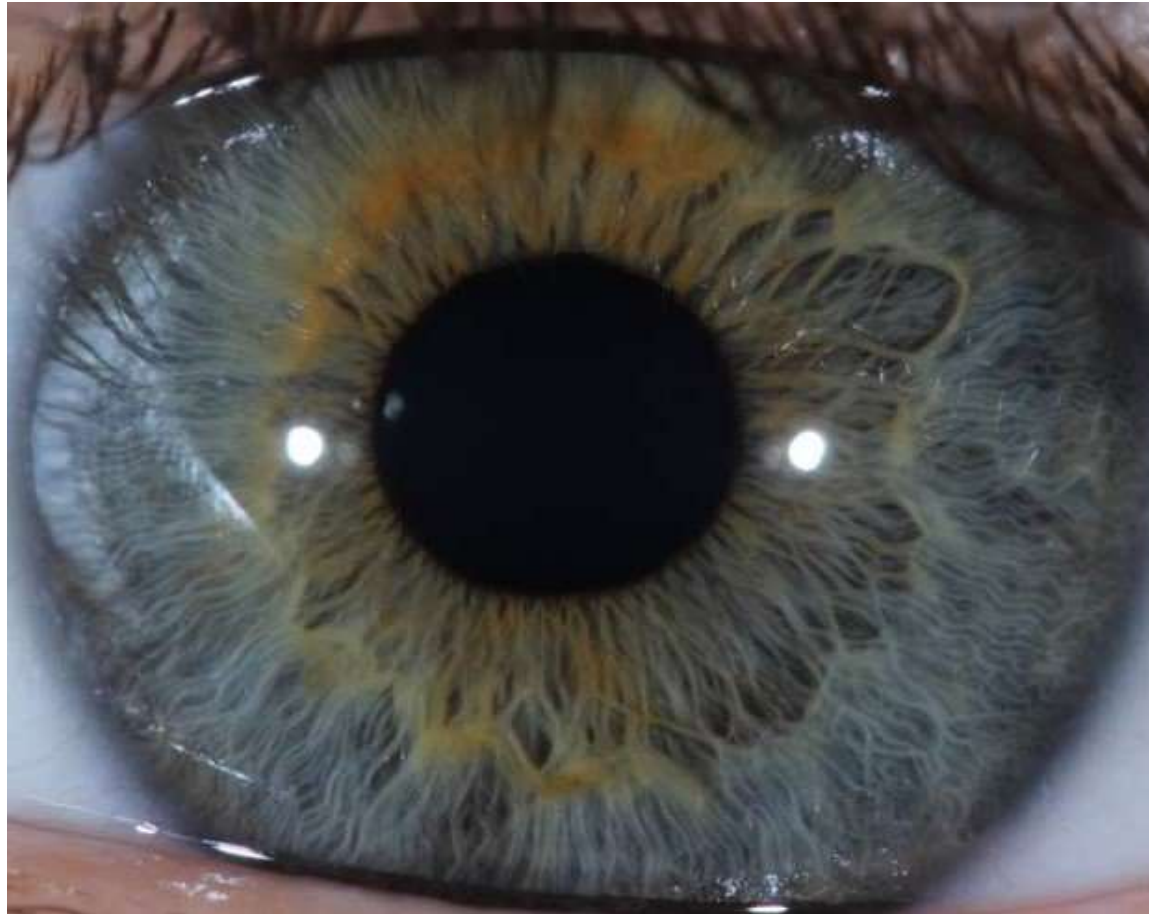
Iris 30 Subtype by Color and Structure?





# Lymphatic Iris Constitution

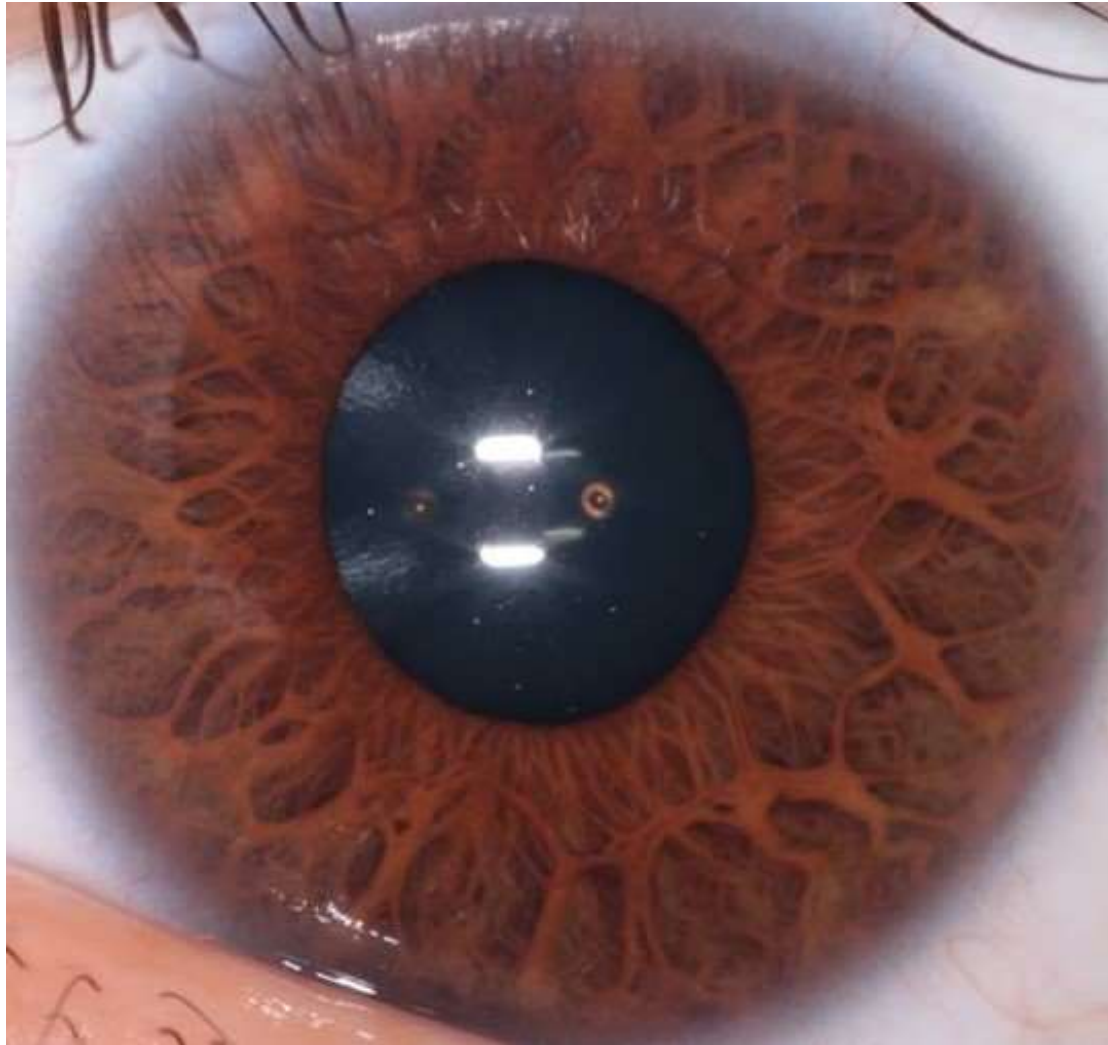
Iris 31 Subtype by Color and Structure?





# Mixed-Biliary Iris Constitution

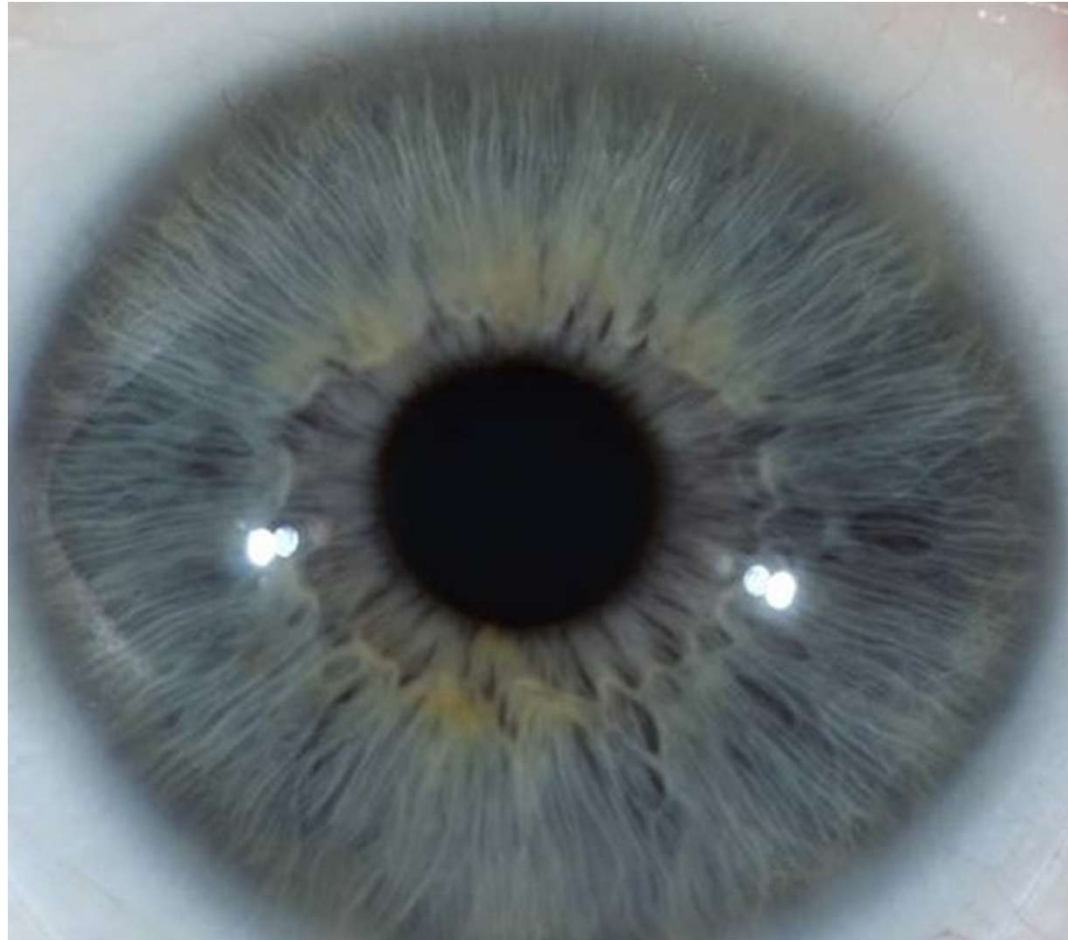
Iris 32 Subtype by Color and Structure?





# Lymphatic Iris Constitution

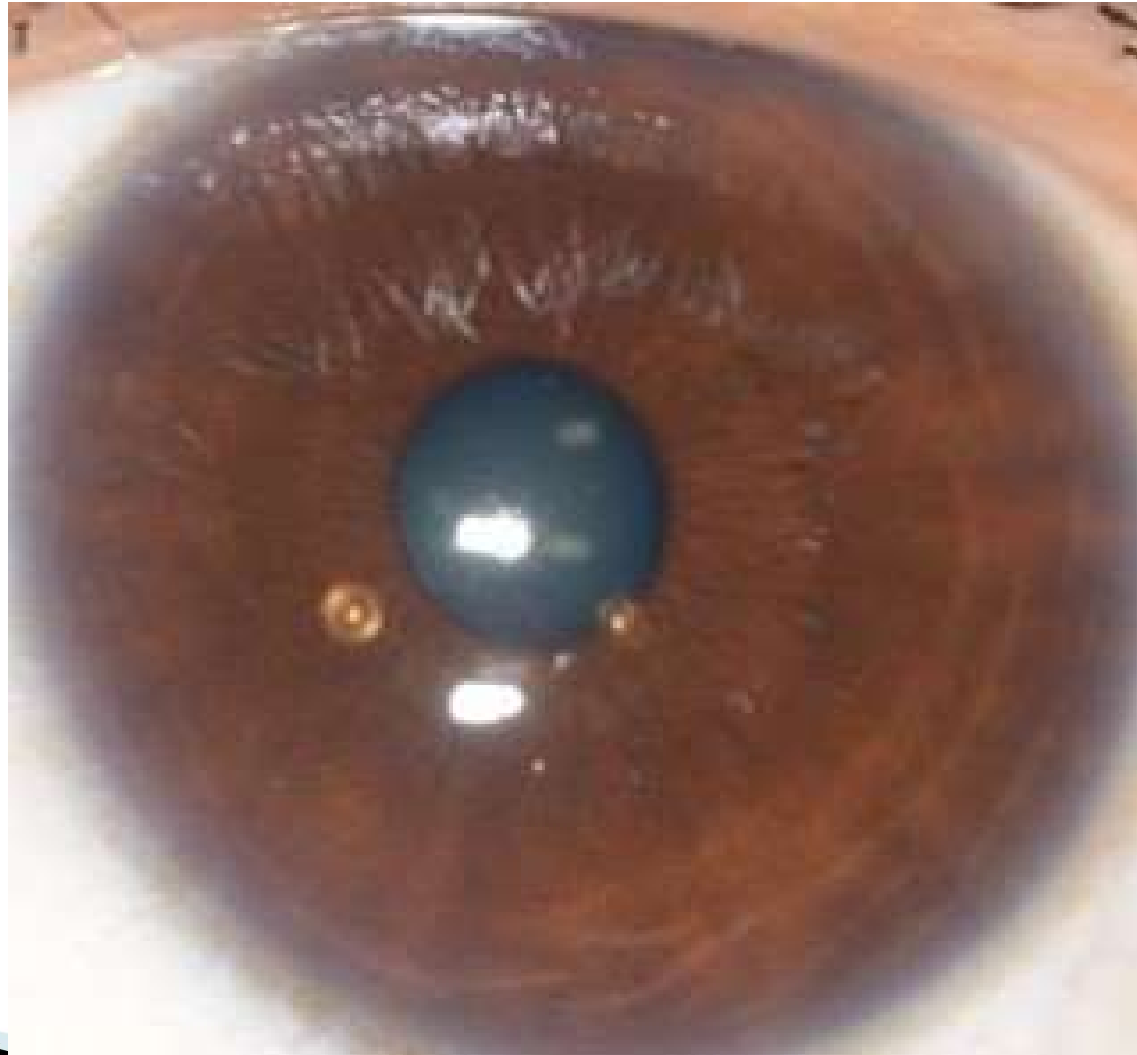
Iris 33 Subtype by Color and Structure?





# Hematogenic Iris Constitution

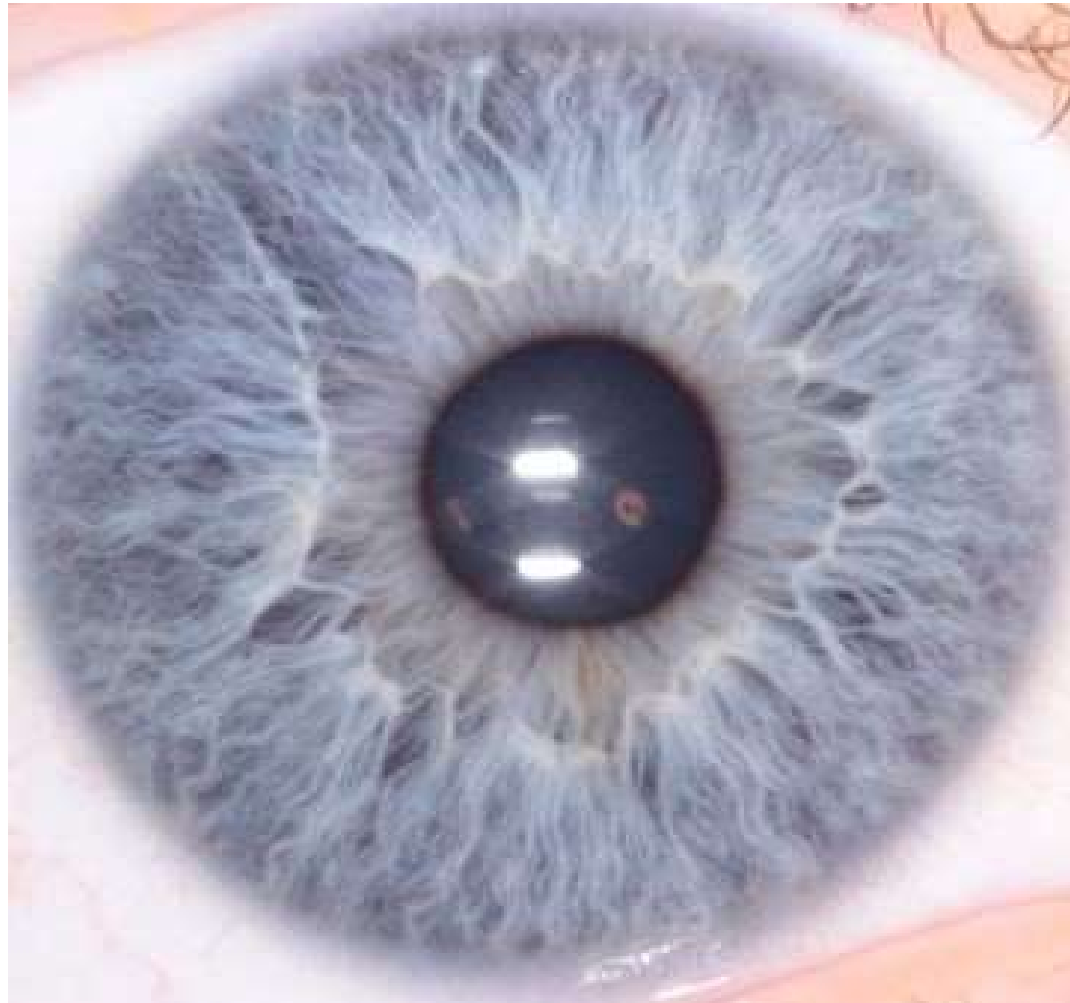
Iris 34 Subtype by Color and Structure?





# Lymphatic Iris Constitution

Iris 35 Subtype by Color and Structure?





# Lymphatic Iris Constitution

Iris 36 Subtype by Color and Structure?

