Anatomy and Physiology of the Eye as it Relates to Iridology

By:

Brenda R. Generali, CNC, CCI
IIPA Certified Comprehensive Iridologist

Joyful Living Services

P.O. Box 485
Weimar, CA 95736-0485
Telephone: 530-878-1119

E-mail: iridology@netzero.net
Web site: http://www.joyfullivingservices.com

Welcome everyone!

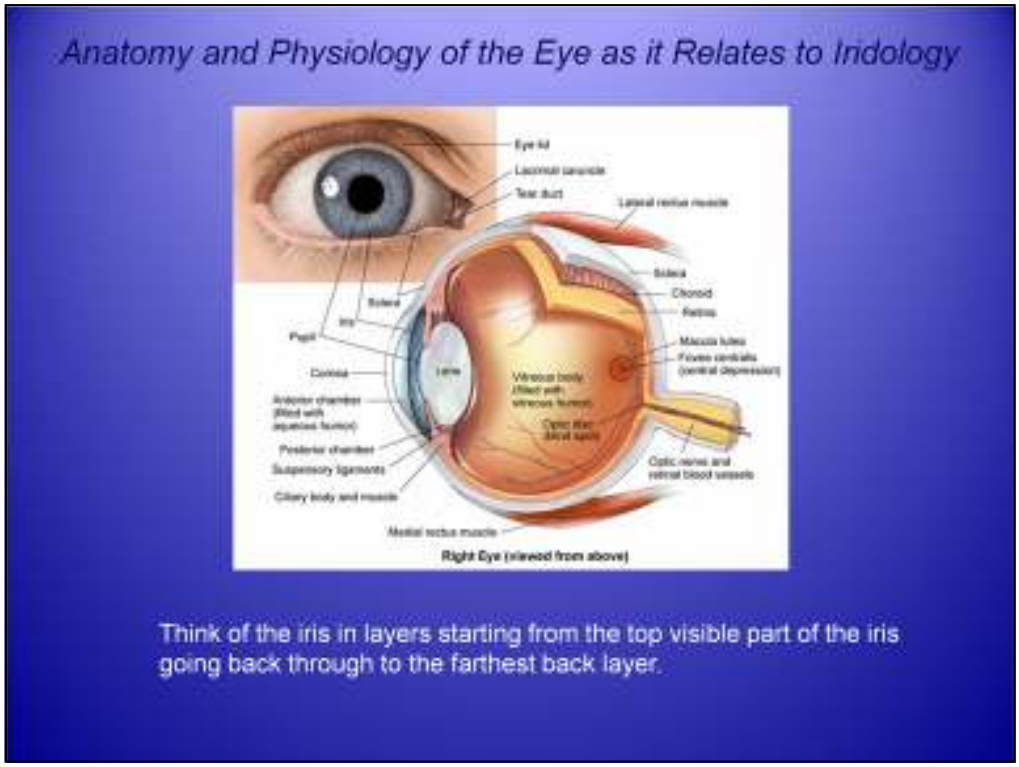

- The eye is our organ of sight. The eye has a number of components which include but are not limited to the corner, iris, pupil, lens, retina, macula, optic nerve, choroid and vitreous.
- **Cornea**: clear front window of the eye that transmits and focuses light into the eye.
- **Iris**: colored part of the eye that helps regulate the amount of light that enters
- **Pupil**: dark aperture in the iris that determines how much light is let into the eye
- **Lens**: transparent structure inside the eye that focuses light rays onto the retina
- **Retina**: nerve layer that lines the back of the eye, senses light, and creates electrical impulses that travel through the optic nerve to the brain
- **Macula**: small central area in the retina that contains special light-sensitive cells and allows us to see fine details clearly
- **Optic Nerve**: connects the eye to the brain and carries the electrical impulses formed by the retina to the visual cortex of the brain
- **Vitreous**: clear, jelly-like substance that fills the middle of the eye

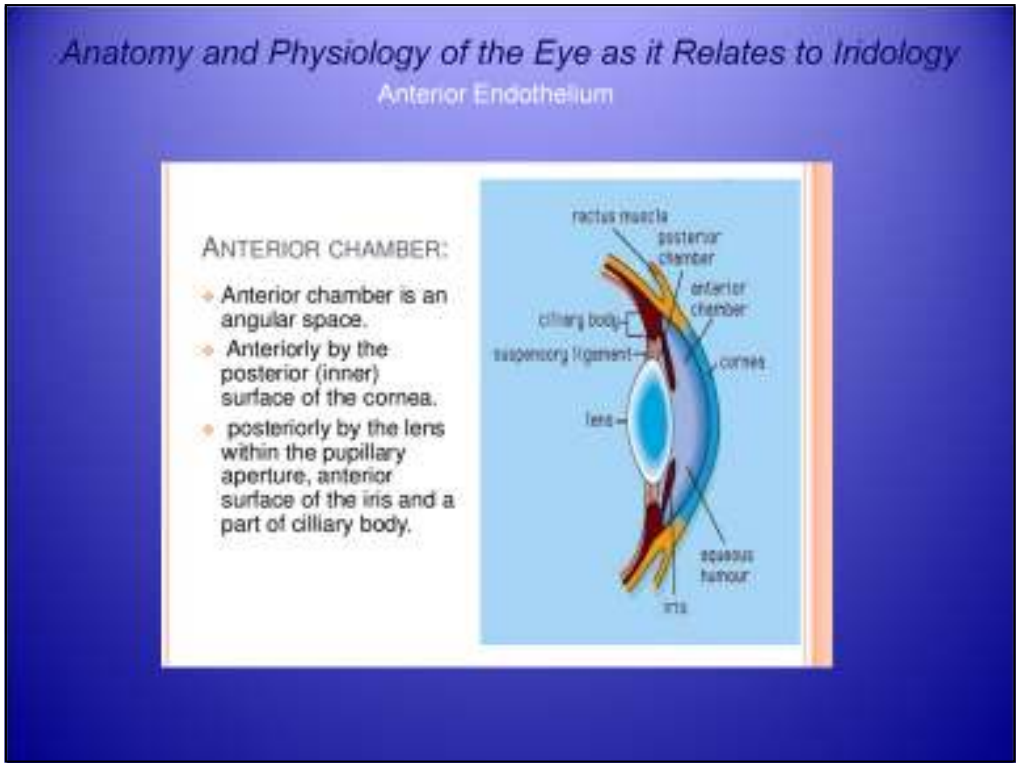

The **<u>anterior endothelium</u>** is invisible to the naked eye. It is located at the very top outermost part of the iris and consists of a single layer of flattened cells. The anterior endothelium is a continuation of the posterior surface of the corner. Because this layer can only be seen under very high powered magnification, it has little significance in our study of the iris or the field of iridology.

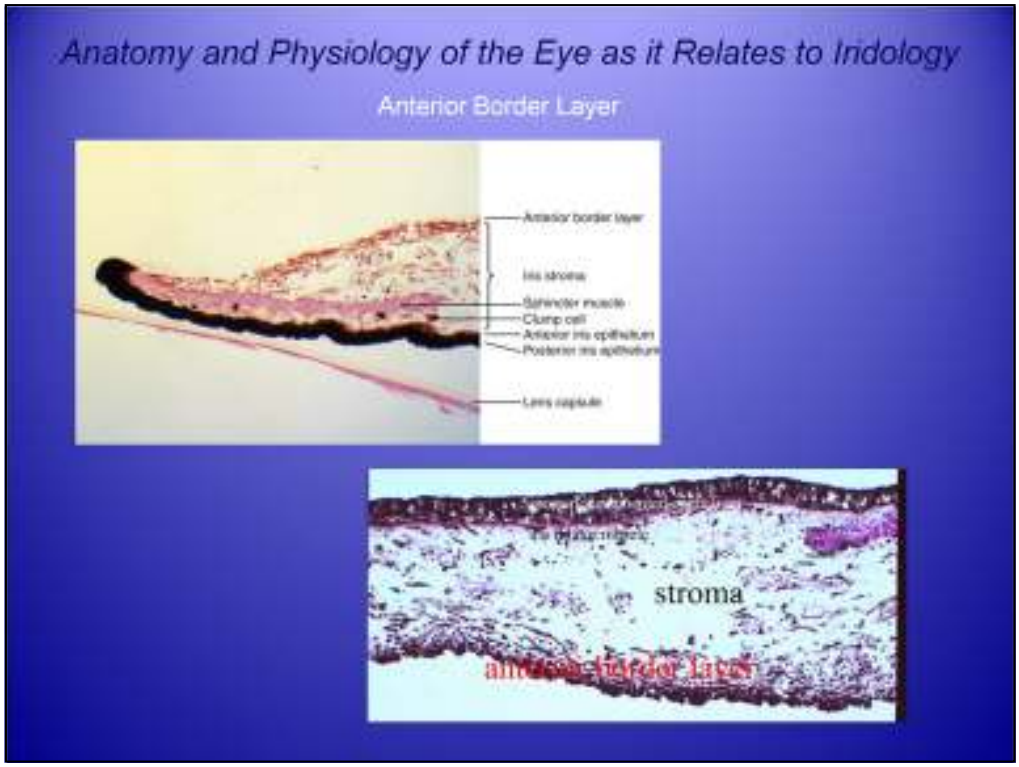

Just behind the flattened invisible anterior endothelium is the **anterior border layer**. This is the layer where the pigment is located and that provides the color of the iris. Depending on the density of this layer and the amount of pigmentation, the anterior border layer helps determine the color of the iris. In the blue iris, this layer is thin and has only a few pigment cells; in the brown iris, it is thick and densely pigmented.

Within thee anterior border layer are intertwining processes of connective tissue and pigment cells.

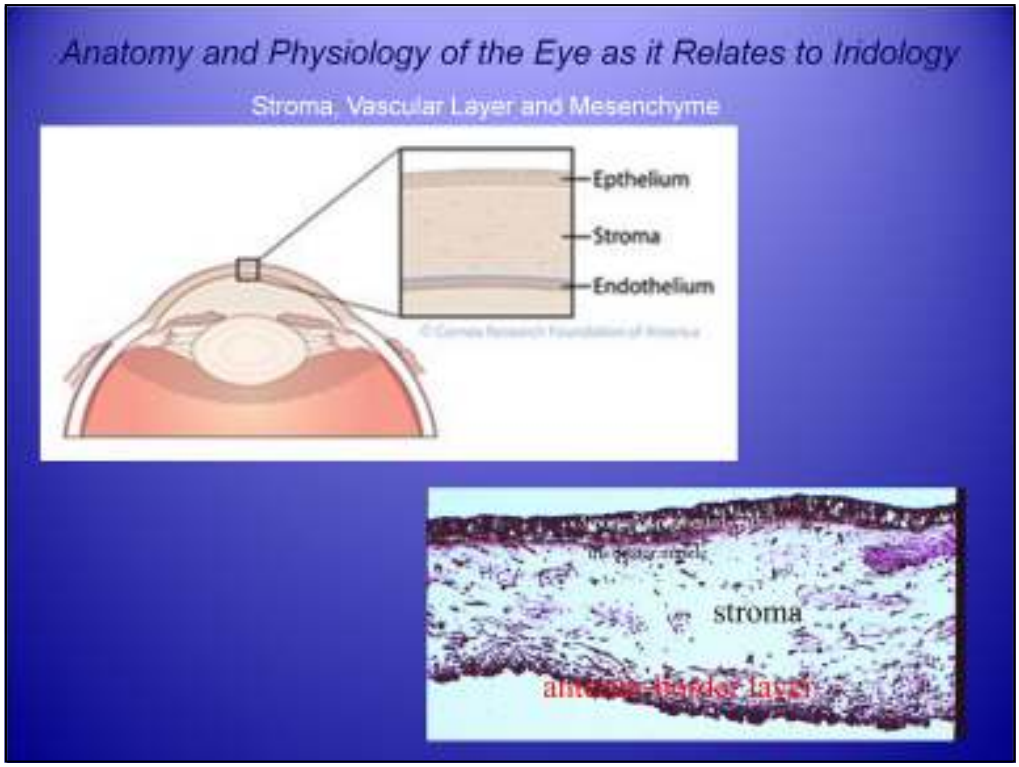

In back of the anterior border layer lies the **stroma**. The stroma is made up of blood vessels enmeshed with connective tissue and constitutes the bulk of the iris. The blood vessels within the stroma run radially, giving rise to the streaks that can be seen on the anterior surface. It is important to remember that the stroma is vascular and not muscular. Each blood vessel of the stroma is wrapped in a collagen sheath similar to the way nerves are covered by the protective Schwann sheath or myelin sheath. These vessels are called iris fibers or trabeculae.

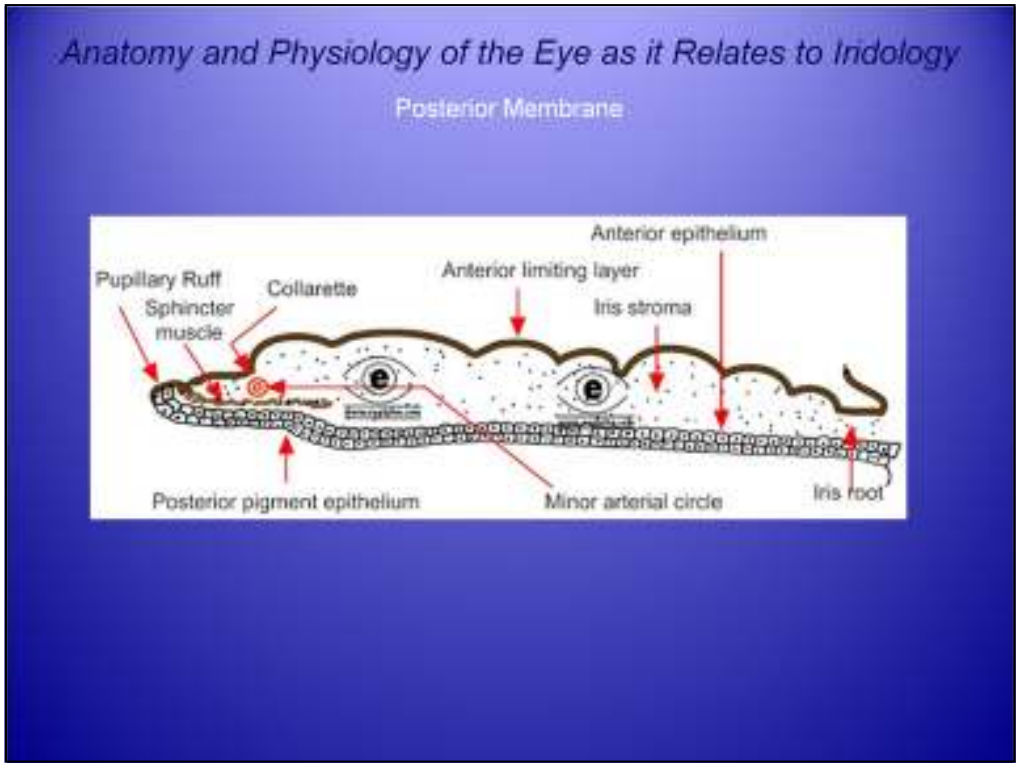

Behind the stroma or bulk of the iris is a layer of muscle called the **posterior membrane**. This membrane is also called the dilator layer because it is responsible for the dilation of the pupil when it is exposed to darkness and thus allows the person to see better in the dark. The posterior membrane consists of a thin layer of plain muscle fiber. When it contracts, it draws the pupillary margin inward, causing the pupil to dilate.

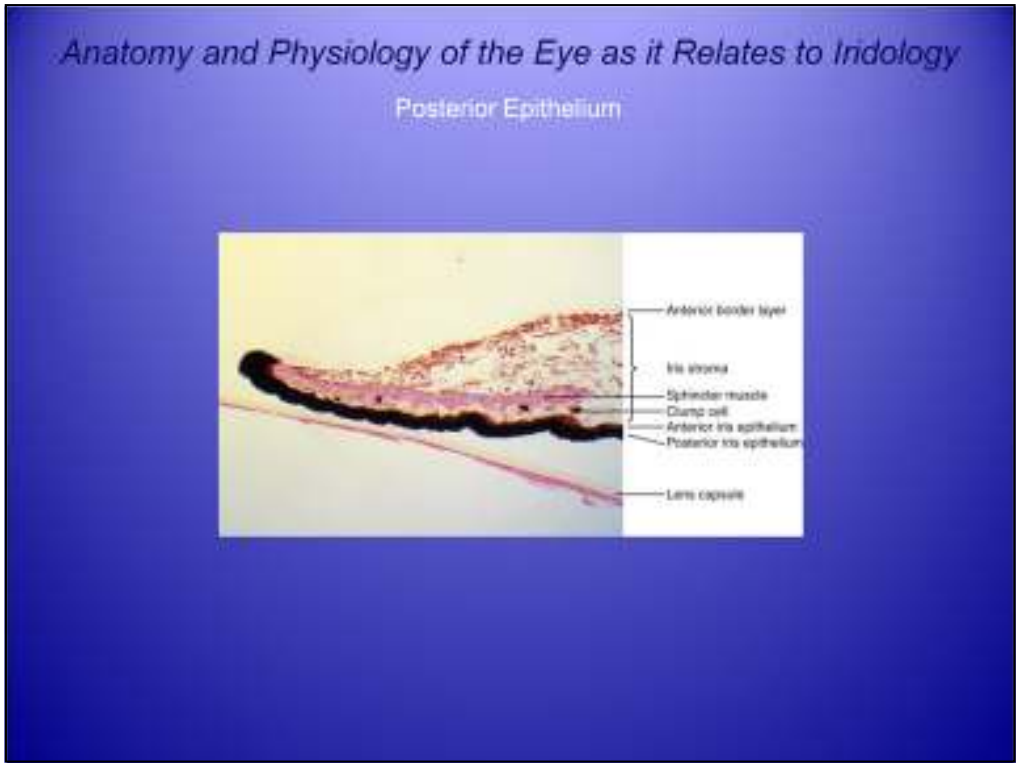

The very back layer of the iris, which lies behind the posterior membrane is the **posterior endothelium**. This consists of two layers of highly pigmented cells. These line the back of the iris and curl around the pupillary margin, creating the black fringe that provides a border to the pupil and can be seen with the naked eye. This black fringe is also called the pupillary border or pupillary ruff and encircles the pupil. This darkly-pigmented posterior endothelium layer serves to prevent the penetration of light through the iris into the posterior chamber of the eyeball. When pigments start to form in the cells of the anterior border layer of the iris, they diffuse from the posterior endothelium.

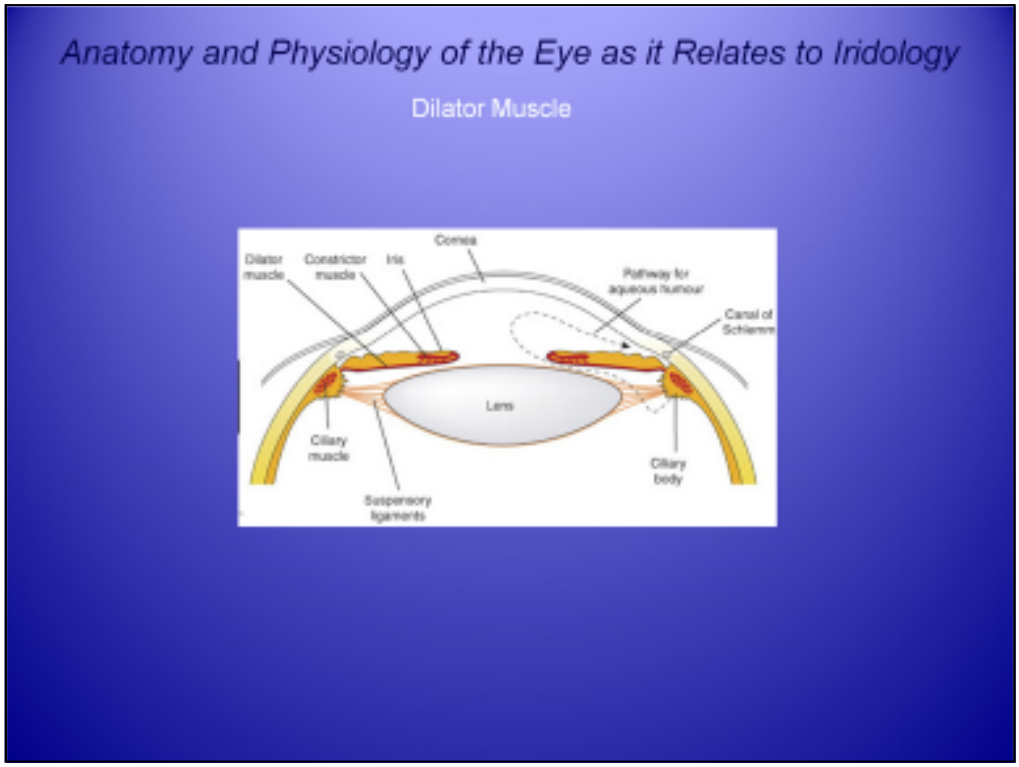

The **Dilator Muscle** is composed of cells characteristic of both posterior pigment epithelium and muscle. The dilator muscle is innervated mostly by the sympathetic aspect of the autonomic nervous system arising from the thoracic segments of the spinal cord around the first thoracic nerve. The posterior highly pigmented epithelium and dilator muscle are formed from the neurectoderm, which is the same tissue that makes up the brain and spinal cord. The neuroectoderm, also called neural ectoderm or neural tube epithelium is the portion of the ectoderm, one of the primary germ cell layers in the early embryo, that develops into the central and peripheral nervous systems.

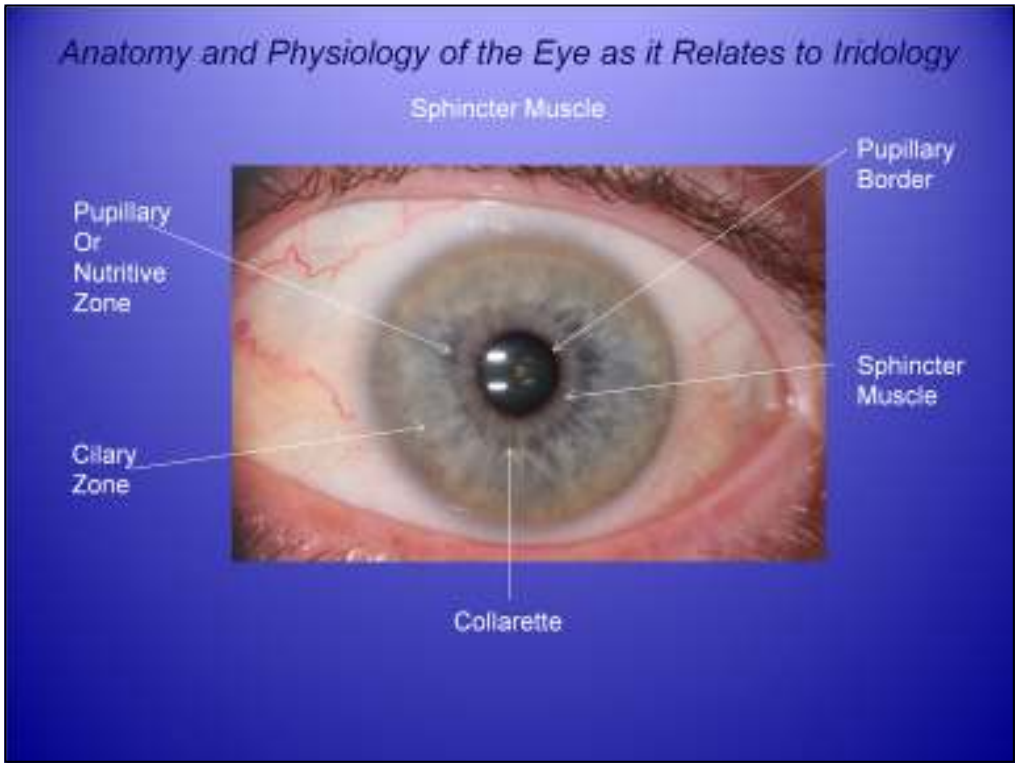

The **Sphincter muscle** is a doughnut shaped muscle that is located beneath the stroma that we often see visible in zone one. We can often see this muscle showing beneath the stroma when the iris fibers are separated and/or less dense in this area. The sphincter muscle is primarily innervated or influenced by the parasymphathetic aspect of the autonomic nervous system that enters the back of the eye through the long ciliary nerves. These nerves arise in the ciliary ganglion behind the eye, and in turn whose branches come from the third cranial nerve and originate in the oculomotor nucleus of the mid-brain. This area reflects the stomach, which is also innervated by the parasymphathetic nervous system. The sphincter muscle has sympathetic enervation as well.

The **Pupillary Zone** is a relatively flat part of the iris that includes zones one and two or the stomach and intestinal reaction fields and surrounds the pupillary ruff or pupillary border. This zone is called the nutritive zone.

The **Ciliary Zone** is an area outside the collarette which includes all of the iris outside the collarette to the iris edge. Within the ciliary zone are 3-4 layers of the iris fibers or trabeculae. These fibers are also called vascular arcades and are blood vessels covered by a collagen sheath. Woven within these iris fibers are layers of connective tissue. There are various iris signs or topographical markings located in the ciliary zone. Inherent deficiencies called contraction furrows or cramp rings may be seen in some irises. Cramp rings are grooves in the iris fibers that look much like ditches that follow underlying patterns of posterior epithelium and furrows of the dilator muscle. The ciliary zone reflects the conditions of all major organs, glands, and systems of the body other than the stomach and gastrointestinal tract.