Anatomy and Physiology of the Eye as it Relates to Iridology

By:

Brenda R. Generali, CNC, CCI
IIPA Certified Comprehensive Iridologist

Joyful Living Services

P.O. Box 485
Weimar, CA 95736-0485
Telephone: 530-878-1119

E-mail: iridology@netzero.net
Web site: http://www.joyfullivingservices.com

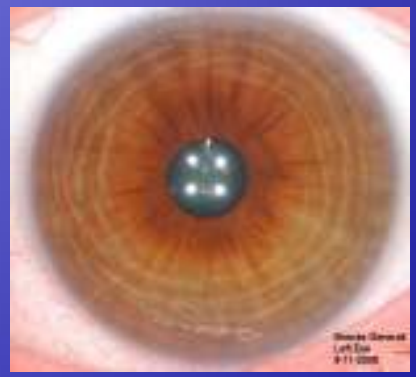

Anatomy and Physiology of the Eye as it Relates to Iridology

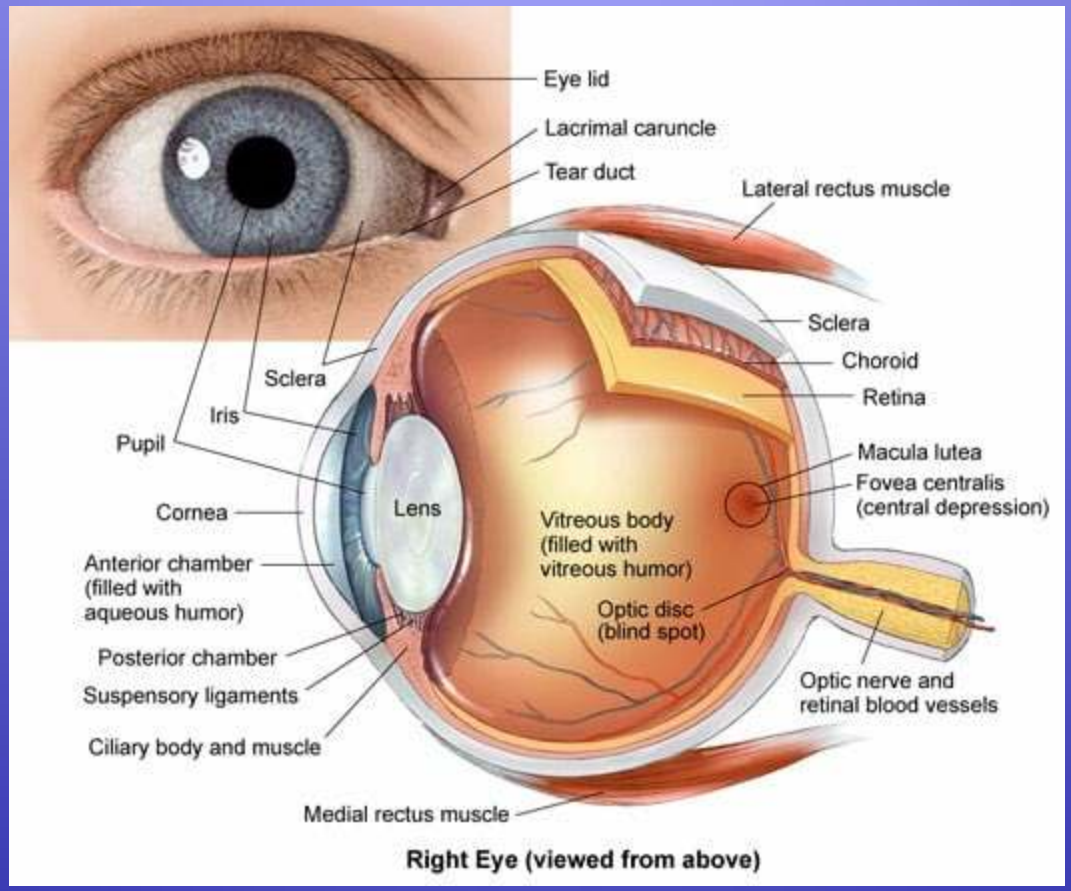

Think of the iris in layers starting from the top visible part of the iris going back through to the farthest back layer.

Anatomy and Physiology of the Eye as it Relates to Iridology

Anterior Endothelium

ANTERIOR CHAMBER:

- Anterior chamber is an angular space.
- Anteriorly by the posterior (inner) surface of the cornea.
- posteriorly by the lens within the pupillary aperture, anterior surface of the iris and a part of cilliary body.

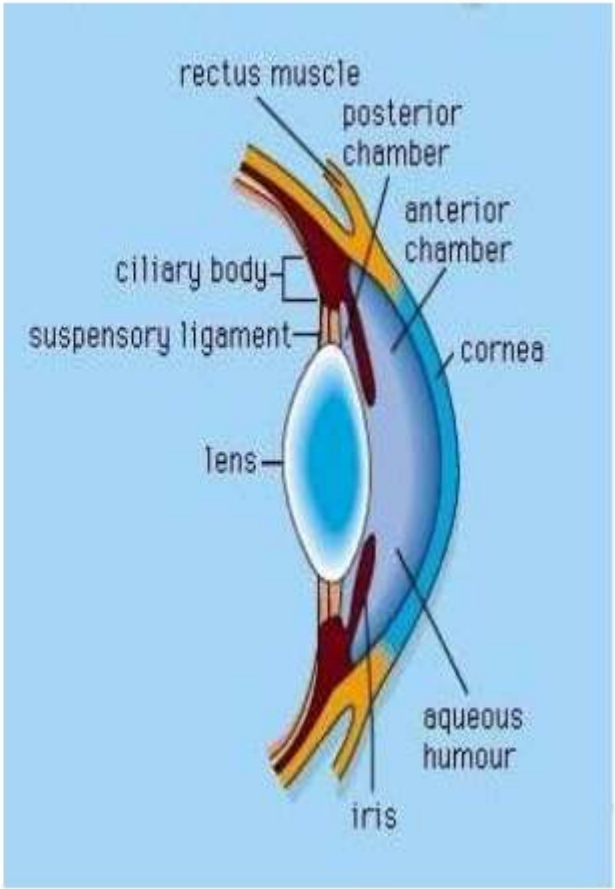

Anatomy and Physiology of the Eye as it Relates to Iridology

Anterior Border Layer

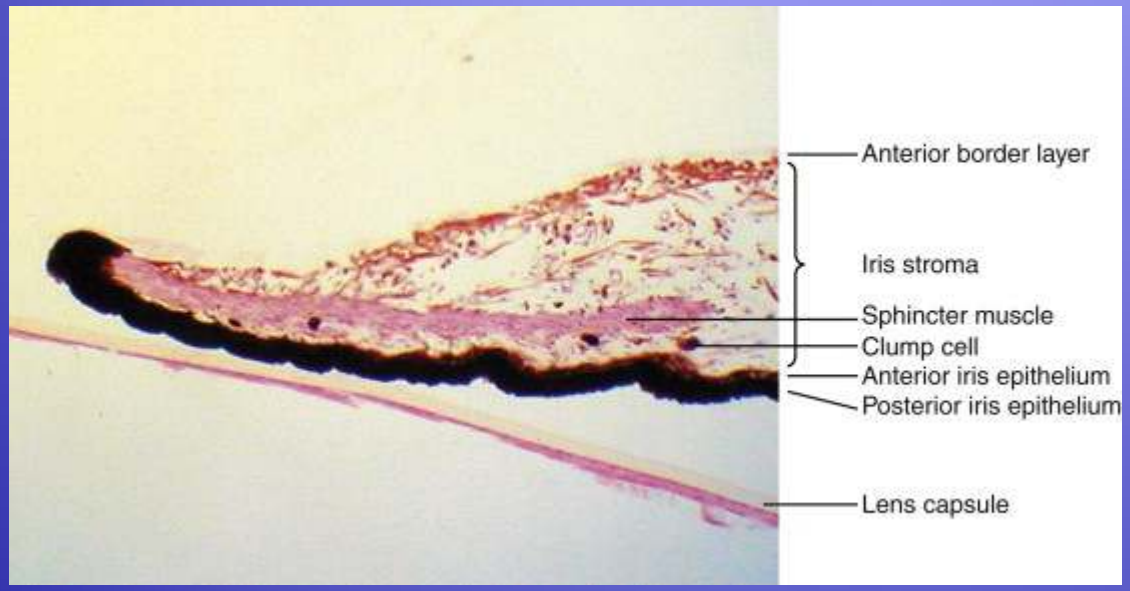

Anatomy and Physiology of the Eye as it Relates to Iridology

Stroma, Vascular Layer and Mesenchyme

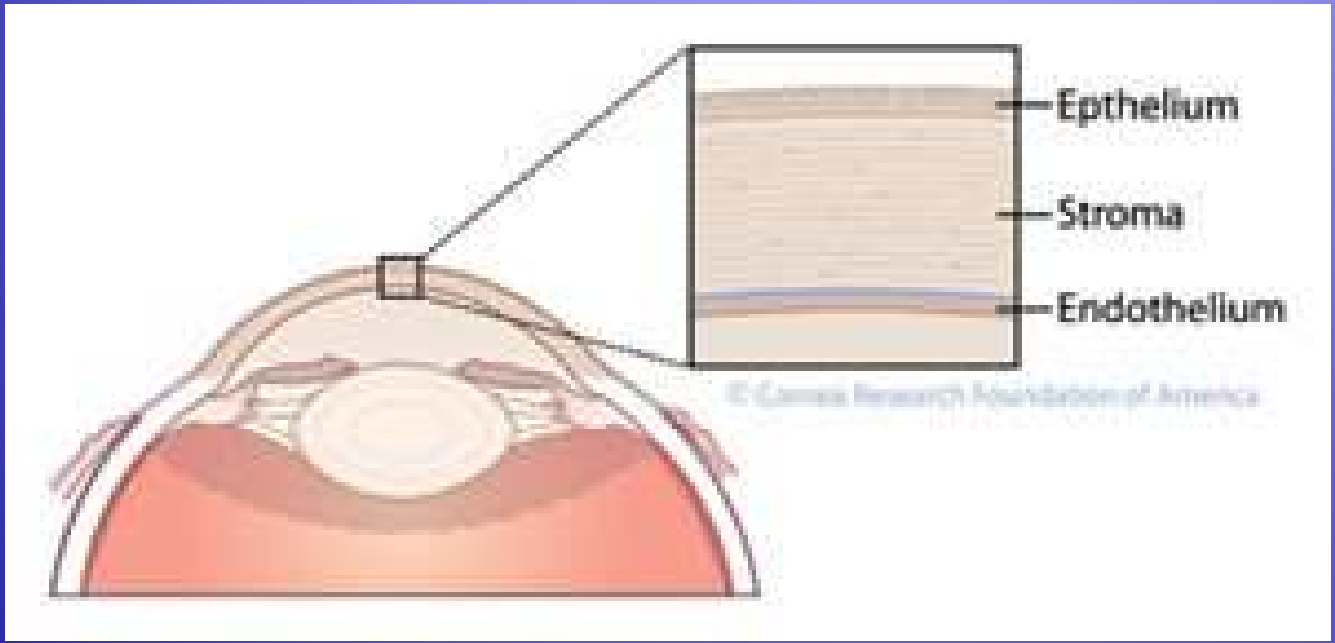

Anatomy and Physiology of the Eye as it Relates to Iridology

Posterior Membrane

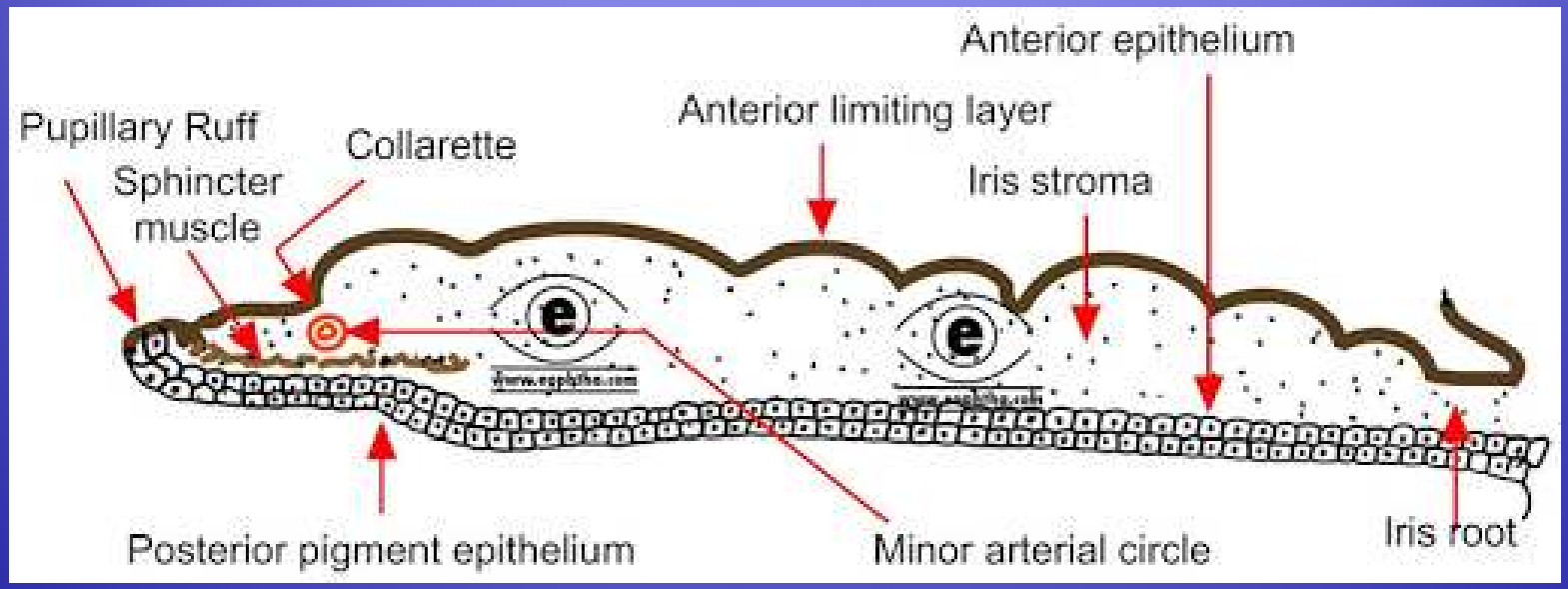

Anatomy and Physiology of the Eye as it Relates to Iridology

Posterior Epithelium

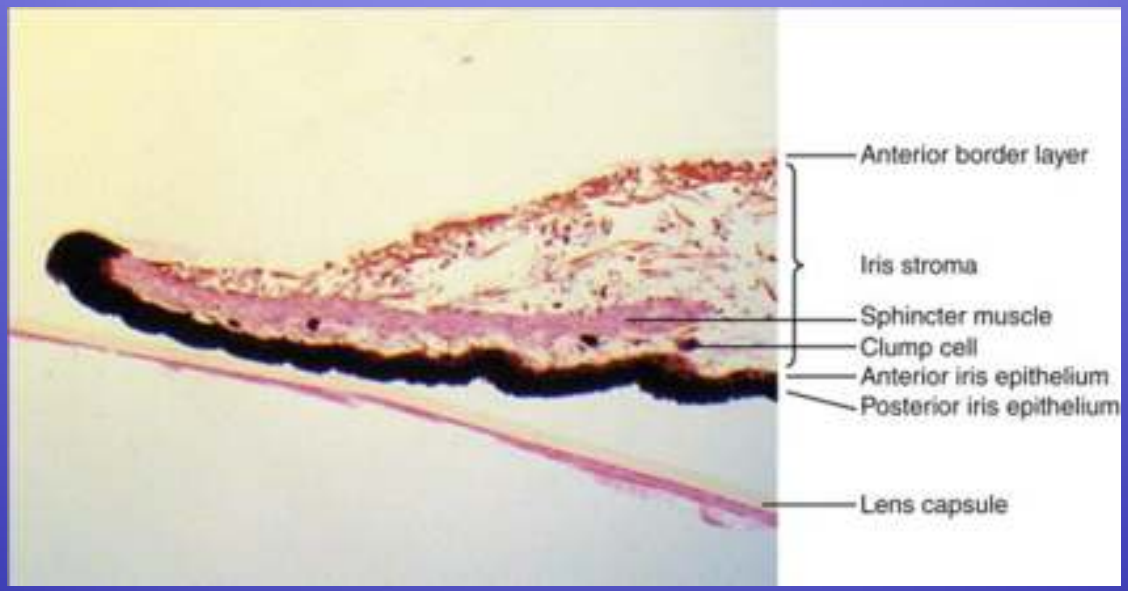

Anatomy and Physiology of the Eye as it Relates to Iridology

Dilator Muscle

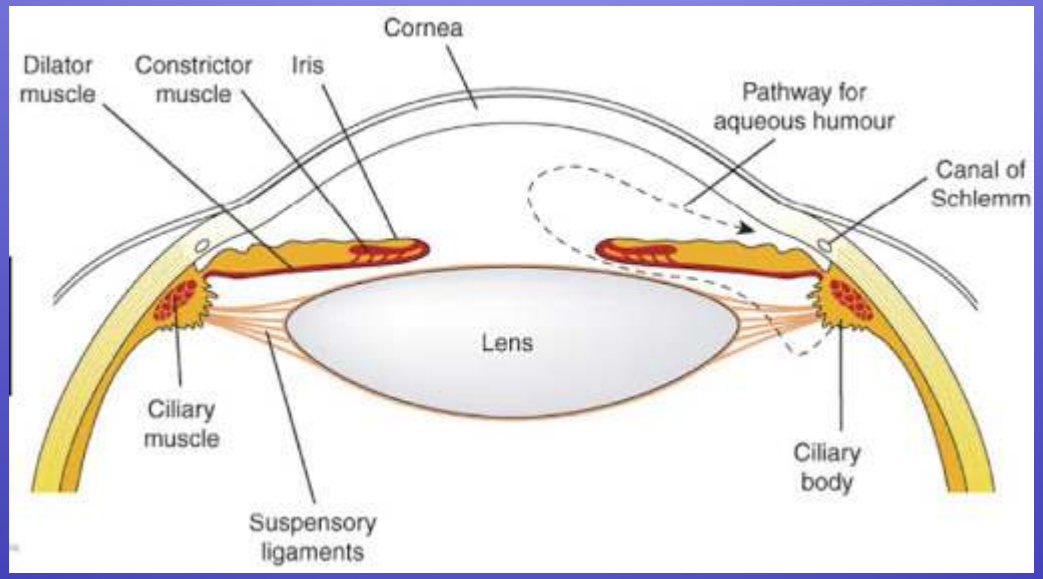
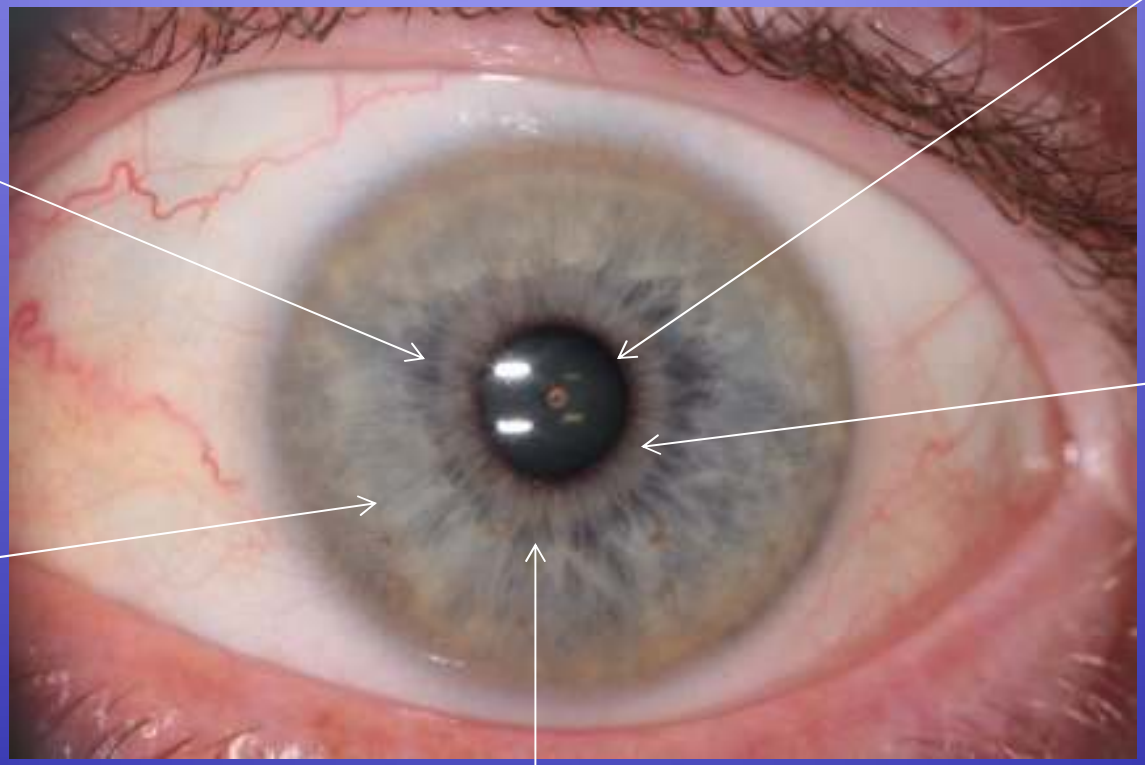
Anatomy and Physiology of the Eye as it Relates to Iridology