

IIPA Level III

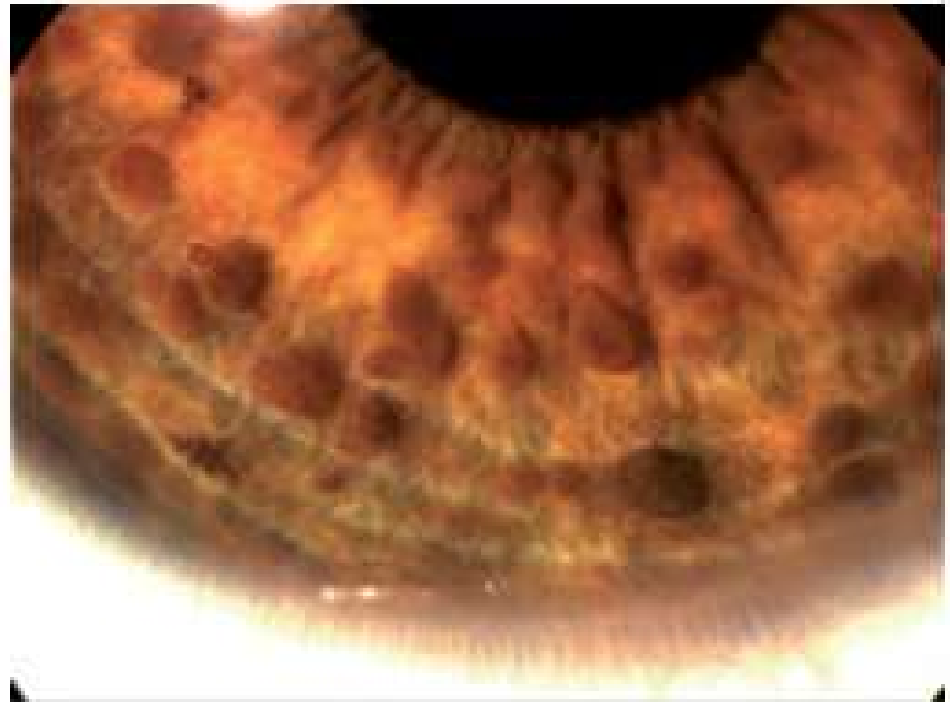
Atypical Ocular Signs

By Ellen Tart-Jensen



Atypical Ocular Signs

What They Mean to
the Health of the
Body



Iris photographs by Miles Research Imaging System: www.milesresearch.com

Ellen Tart-Jensen, Ph.D, D.Sc., CCII

www.bernardjensen.com, www.myinfiniteiris.com

(760) 471-9977

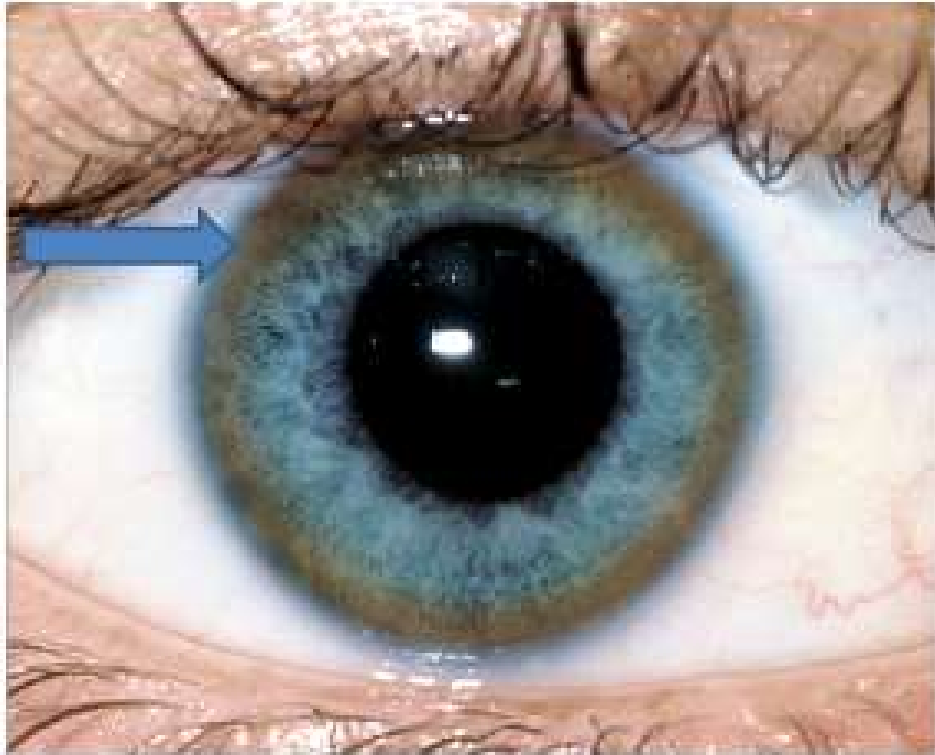


Our Amazing Eyes

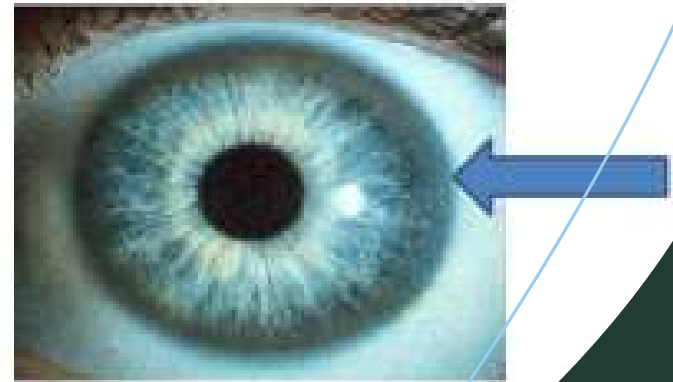
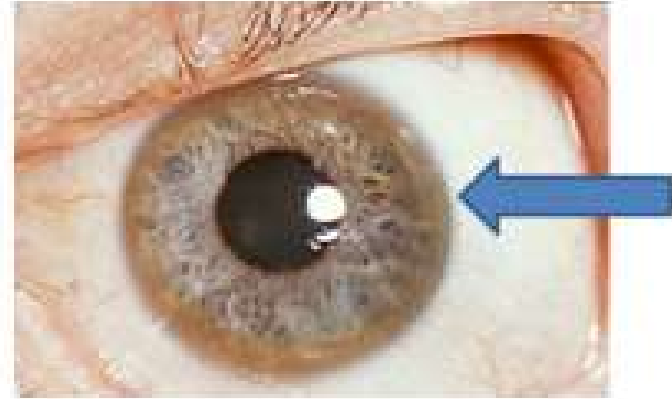
- There is so much to learn from all the information that has been revealed and so much still to discover.**
- Today we will study some of the results of the research concerning atypical ocular signs that will help the iridologist know what to do when they encounter these signs.**



Wilson's Disease



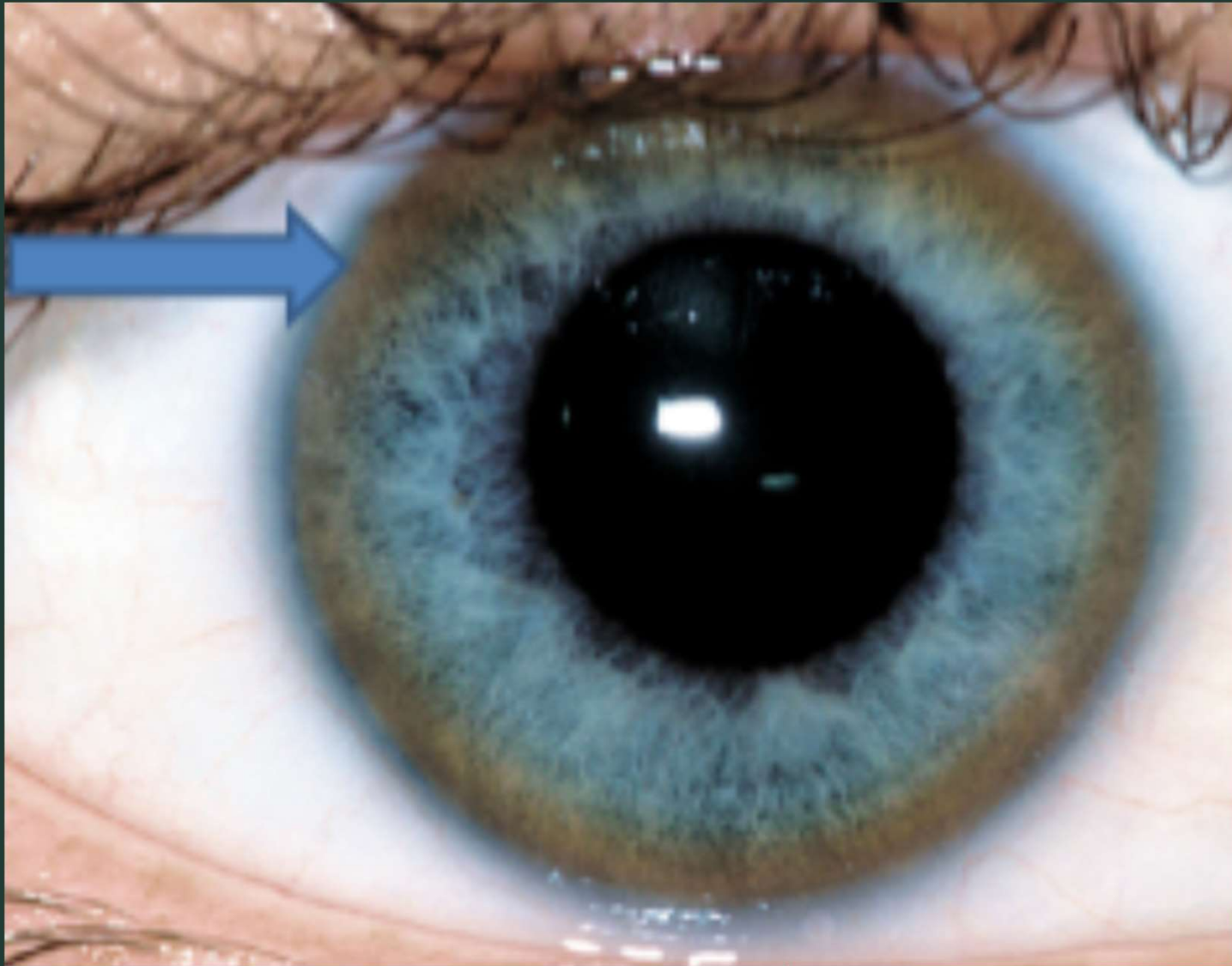
Kayser-Fleischer Ring



Wilson's Disease: Kayser- Fleischer Ring

- A genetic disorder caused by a **defect in the way the body utilizes copper in the liver.**
- The disease causes a faulty storage of copper so that it cannot be excreted properly in the bile.
- Copper accumulates in the liver causing biliary damage.
- When the liver is injured, copper leaches out into the blood stream.
- High levels of copper in the blood lead to copper deposits in the cornea.





The Kayser Fleisher Ring

- Named for Dr. Bernhard Kayser and Dr. Bruno Fleischer of Germany who first described the ring in 1902.
- Golden brown to greenish-brown colored ring.
- Appears first in the superior portion of the iris edge, then at the inferior edge and finally will encircle the entire circumference of the iris edge in the cornea.
- Copper may also accumulate in the brainstem, cerebellum, and cerebral cortex **causing severe neurological problems.**
- The Kayser-Fleisher ring is present in 97% of patients with neurologic manifestations of Wilson's Disease.



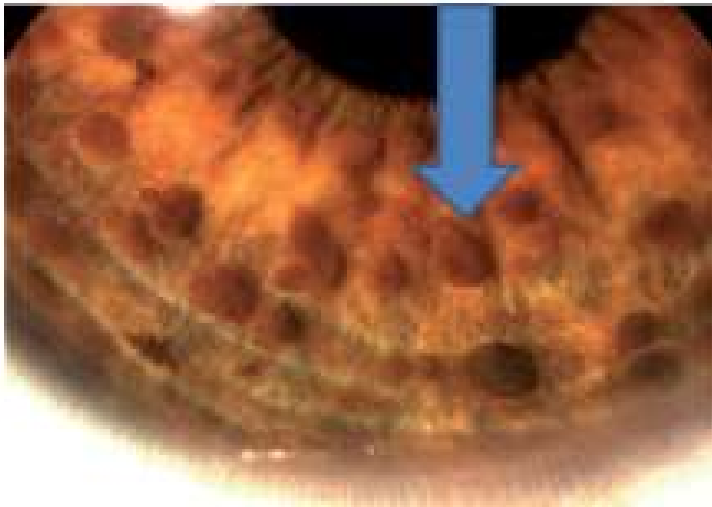
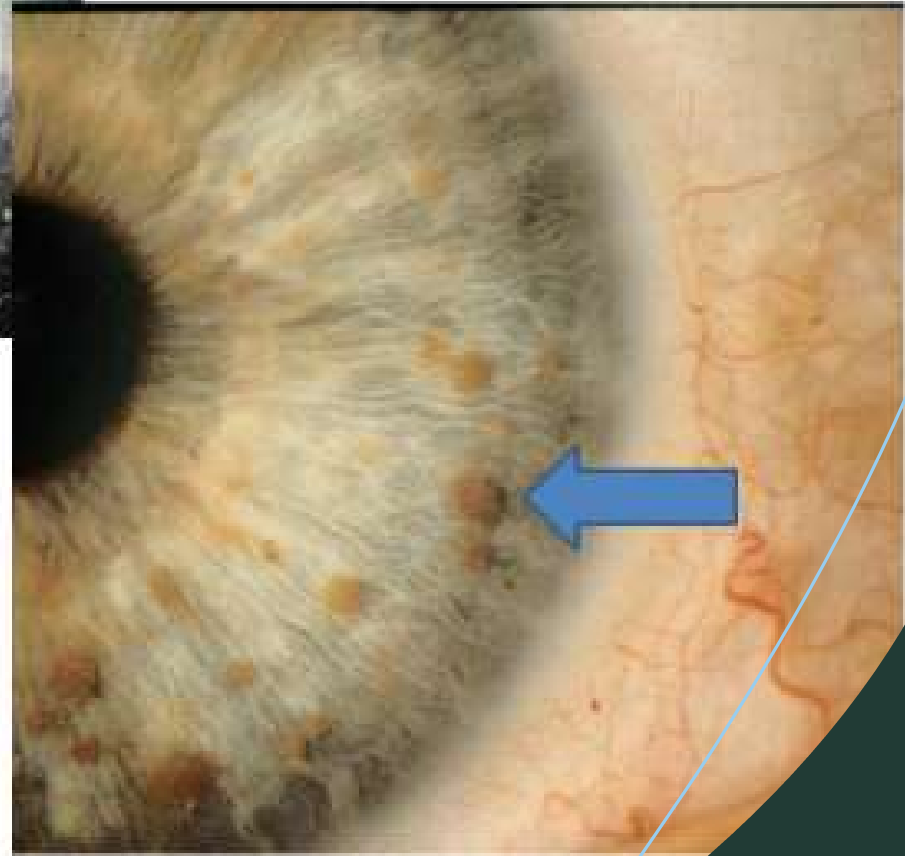
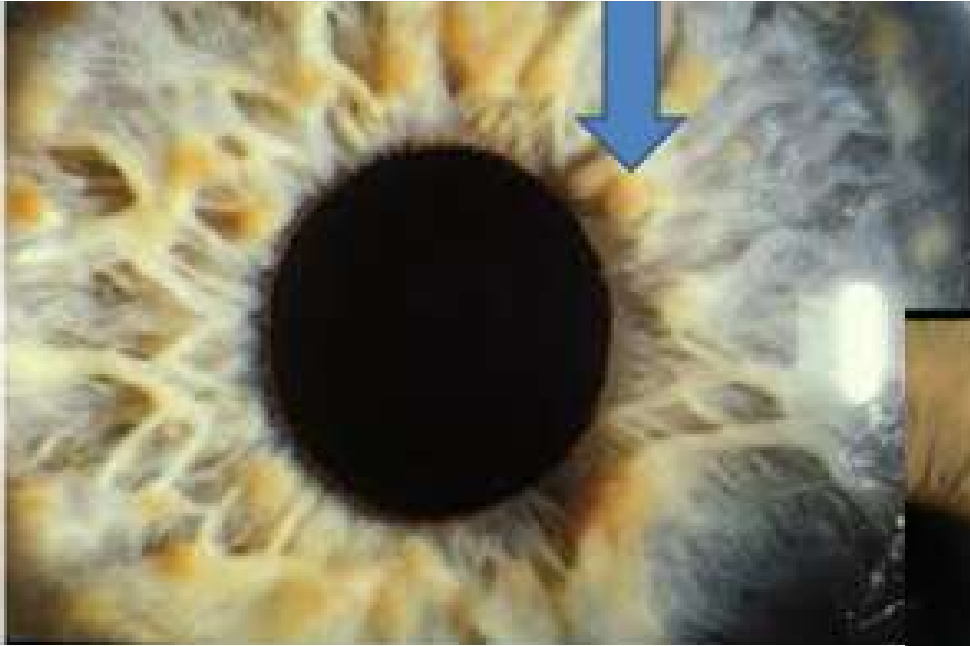
- Wilson's Disease is treated with a specific type of copper chelation therapy.
- When the tissue levels of copper decline, the Kayser-Fleischer ring will eventually go away within about two years of treatment.

Natural Chelation

- Cilantro and chlorella may be used to support natural chelation.
- Dandelion and Milk Thistle are supportive to liver cleansing and repair.
- Support nerves with B vitamins, rice bran, oat bran, skullcap



Lisch Nodules



Lisch Nodules

- Melanocytic (pigmented) growths, usually clear yellow to brown.
- Well defined, dome shaped elevations projecting from the surface of the iris.
- They may be seen without magnification but a slit lamp examination may be necessary to distinguish them from common pigments on the iris which are mostly flat with blurred margins. The nodules are thought not to cause any concerns to the vision.
- Lisch nodules are the most common clinical finding in adults over 20 years of age with Type I Neurofibromatosis (NF-1).
- This is an example of an **ocular manifestation of a genetic disease**. NF-1 has been mapped to a gene defect in chromosome 17.
- Recommend ophthalmology inspection.

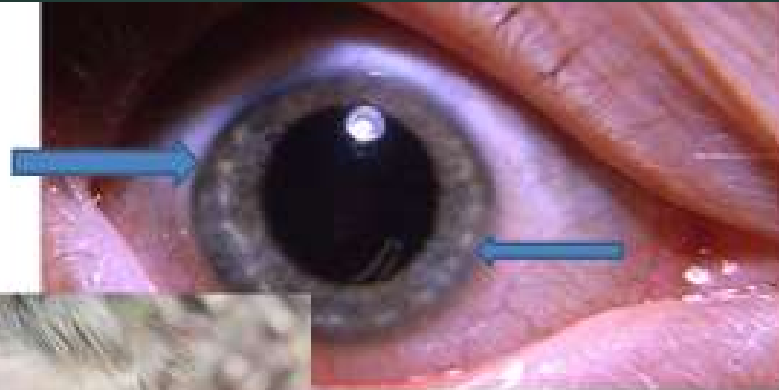


Neurofibromatosis (NF)

- Inherited condition with a high risk of tumor formation, particularly in the brain.
- Autosomal dominant. If only one parent has neurofibromatosis, his or her children have a 50% chance of developing the condition.
- It affects males and females equally.
- Type I, nerve tissue grows tumors that compress nerves.
- Type II, affects C-8 often leading to hearing loss.

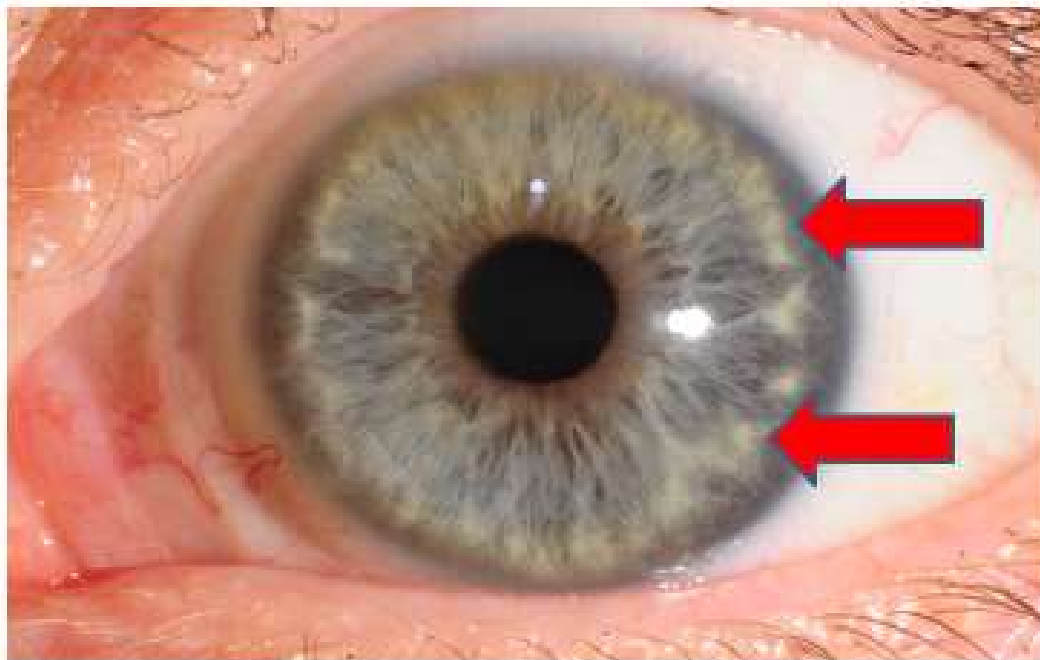


Brushfield Spots



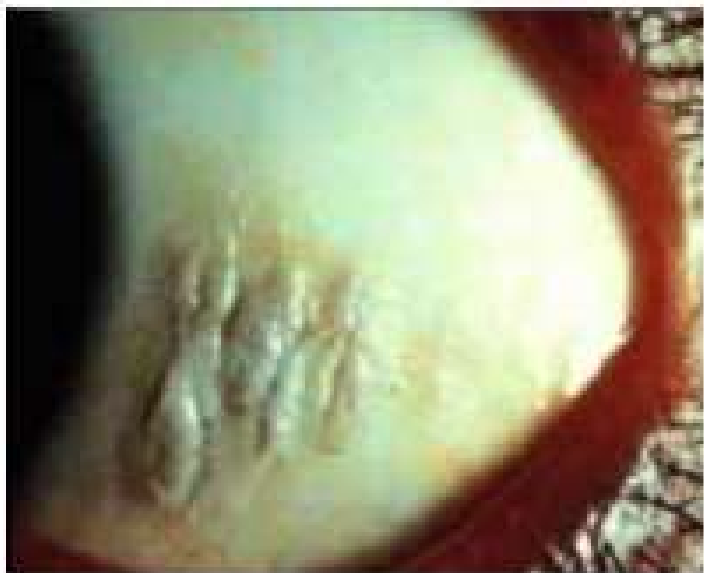Brushfield Spots

"Small white spots that are slightly elevated on the surface of the iris and are arranged in a ring concentric with the pupil. These spots occur in normal children but occur in 90% of children with Down's syndrome. Described and studied in 1924 by Thomas Brushfield and are due to aggregation of a normal iris element (connective tissue)." --EyeRounds.org



Wolfflin Spots

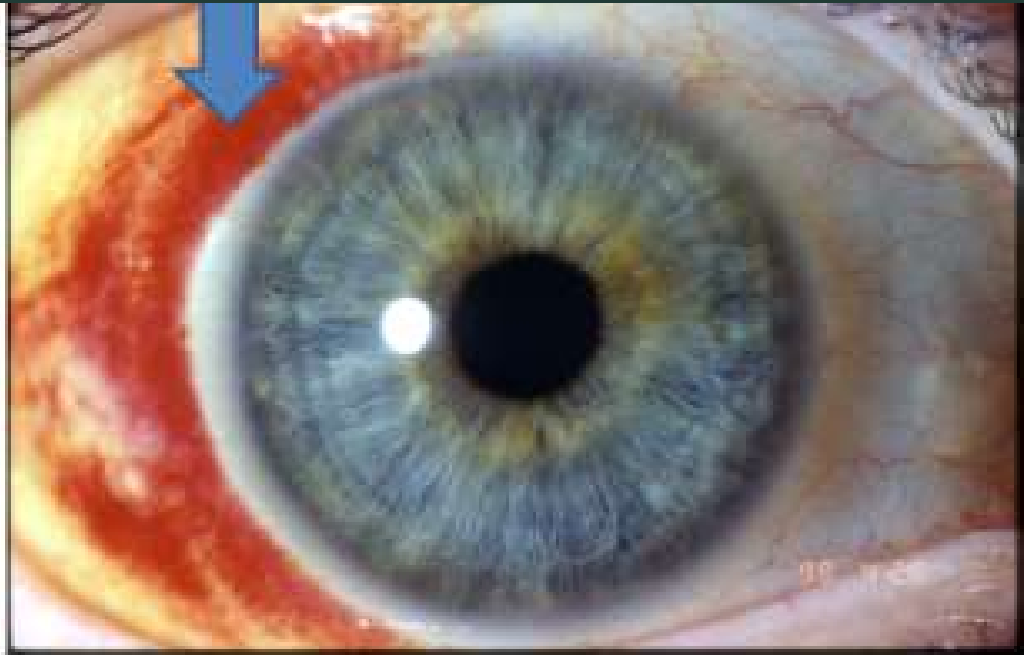
- Wolfflin spots are the whitish clumps of connective fibers found in some irises (mostly blue) near the periphery. These are somewhat distinct from Brushfield spots.
- Wolfflin described it as “elevated nodules (whitish or light yellow), usually situated in the periphery of the iris, and occurring in about 10% of all normal individuals.”
- In iridology known as lymphatic rosary, hydrogenoid
- Tophi are collagen bundles/clumps of connective fibers



Bitot Spots

- Raised, irregularly-shaped, foamy white or gray patches that appear on the conjunctiva.
- Caused by severe Vitamin A deficiency or malabsorption of fat and vitamins.
- Composed of accumulation of hardened epithelial debris and secretions.
- Often accompanied by night blindness.
- Eye ulcers can develop and the cornea starts to dissolve if Bitot spots are not treated. This can result in irreversible blindness.





Red Sclera

- Commonly occurs in the winter time when people spend a lot of time indoors with dry heat.
- Fluid dries in iris and vessels burst.
- Omega oils, bilberry, oat straw, rutin, celery juice are all supportive of healthy eyes in such cases.



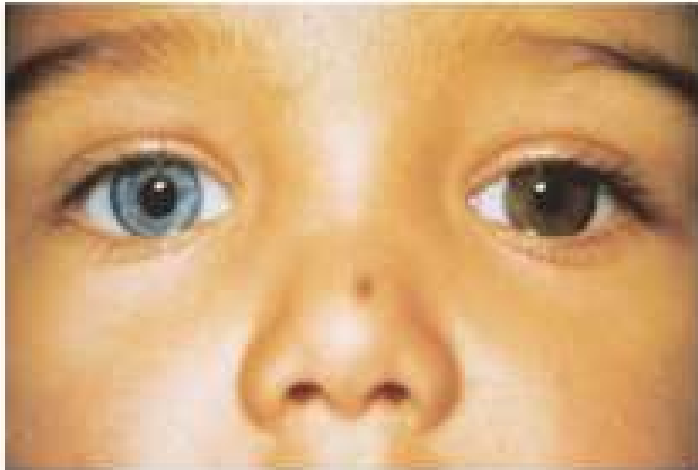

Conjunctivitis or Pink Eye

- Redness and inflammation of the conjunctiva or clear membrane that covers the sclera or white parts of the eyes.
- Symptoms are itching and burning of the eye and fluid drainage.
- Caused by a virus or bacterial infection. Allergies may play a roll.
- **Colloidal Silver, Similasan Homeopathic Drops for Irritated Eyes**

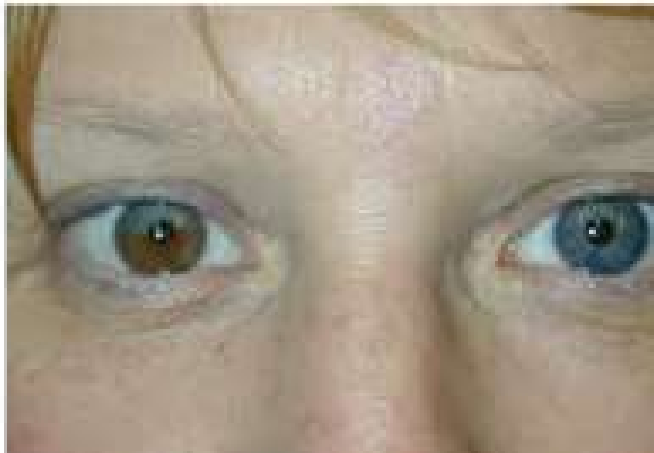

Waardenburg Syndrome



Heterochromia

A difference in coloration. Either excess or lack of pigmentation in the iris(es)



- ❑ Different colored eyes, such as one blue eye and one brown eye.
- ❑ Sometimes one eye has segments of two different colors.



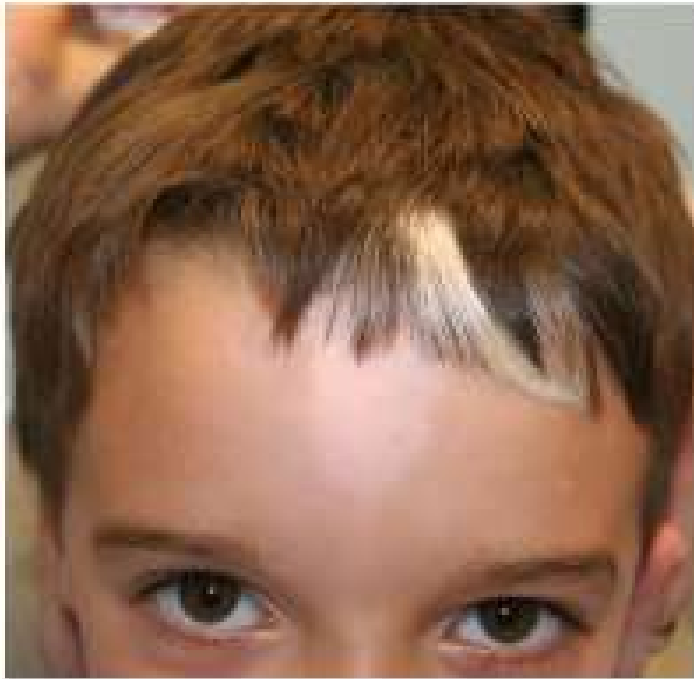Waardenburg Syndrome



- ❑ Often have very pale blue eyes.



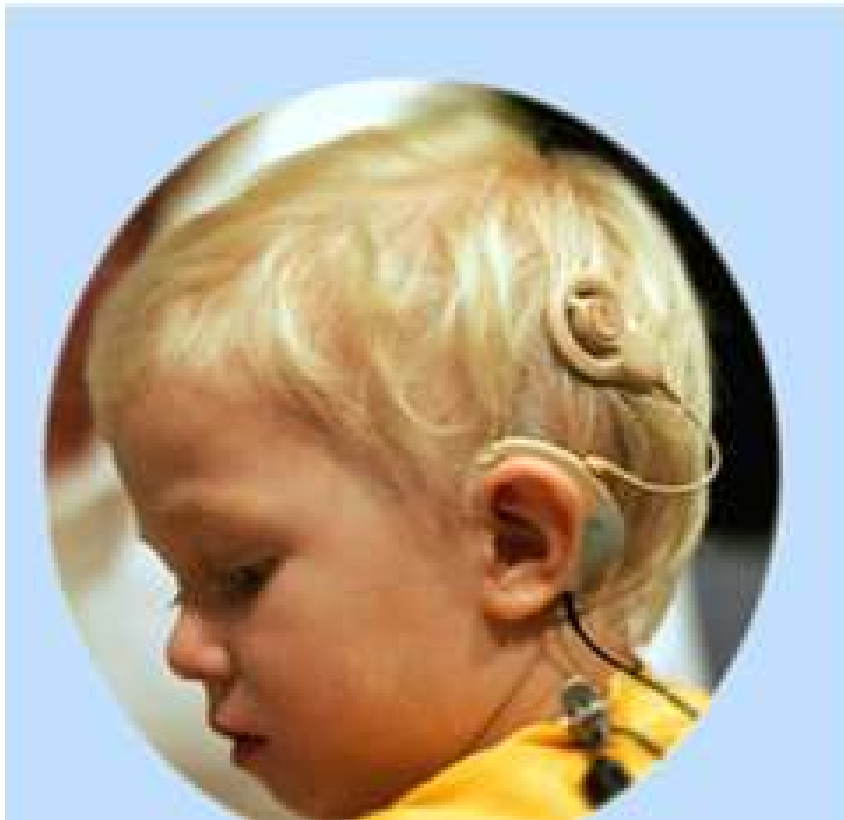Waardenburg Syndrome



- ❑ Distinctive hair coloring (such as a patch of white hair or hair that prematurely turns gray) is another common sign of the condition.



Waardenburg Syndrome



- Most have normal hearing.
- Moderate to profound hearing loss can occur in some people.
- Hearing loss is present from birth (congenital), but can often be corrected.



Other Conditions that may be Present in Waardenburg Syndrome

- Cleft lip (rare)
 - Constipation
 - Difficulty completely straightening joints
 - Possible slight decrease in intellectual function
 - Wide-set eyes
 - Pale color skin, hair, and eyes (partial albinism)
- Features of Waardenburg syndrome vary among affected individuals, even among people in the same family.



Waardenburg Syndrome

Exams and Tests

- Audiometry/Hearing Tests
- Bowel Transit Time
- Colon biopsy
- Genetic testing

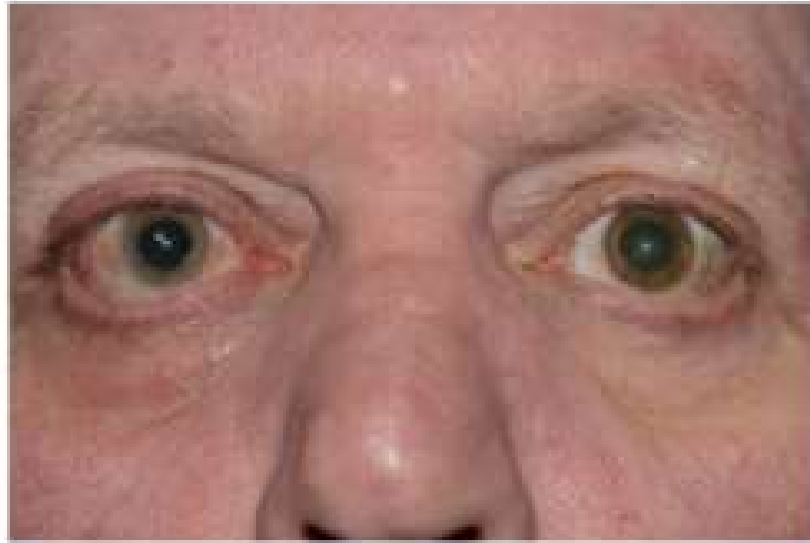Treatment

- There is no specific treatment. Symptoms will be treated as appropriate. Special diets and herbal remedies to keep the bowel moving are important for those with constipation. Oat or rice fiber, ground chia or flax seeds, fruits and vegetables are all helpful. Encourage joyful activities. Help them find what they love to do!

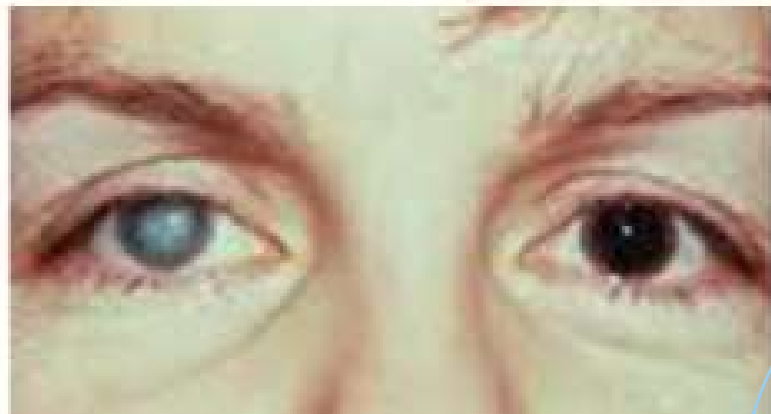
Outlook (Prognosis)

- Once hearing problems are corrected, most people with this syndrome should be able to lead a normal life. Those with rarer forms of the syndrome may have other complications.





Fuch's Heterochromic Iridocyclitis



- Usually only one eye will be affected causing it to look much lighter in color than the other eye.



Fuch's Heterochromic Iridocyclitis (FHI)

- Discovered by **Ernst Fuchs**, an Austrian ophthalmologist in the early 1900's.
- Causes **inflammation of the uvea** which includes the iris, the choroid or thin layer in back of the eye that contains many blood vessels, and the ciliary body, which joins the iris and choroid together.
- Usually only one eye will be affected causing it to look much lighter in color than the other eye.
- **Often the disturbed eye will be blue** while the other eye will be brown or darker blue.
- The cause of the inflammation is not known, however it is believed to be linked to the **herpes virus, rubella, or autoimmune disorders.**
- FHI causes a **predisposition to visual impairment, cataracts, and glaucoma.**
- Patients are often without symptoms and the disease is discovered through investigation of the heterochromia.

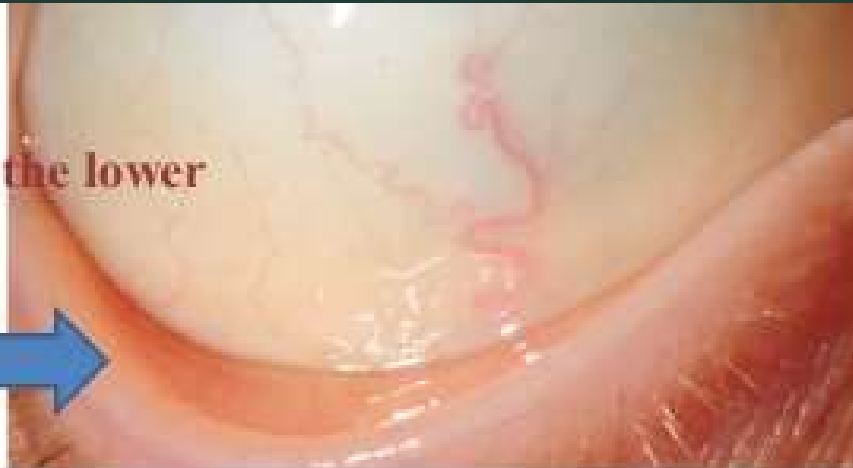


Iron Deficiency Anemia

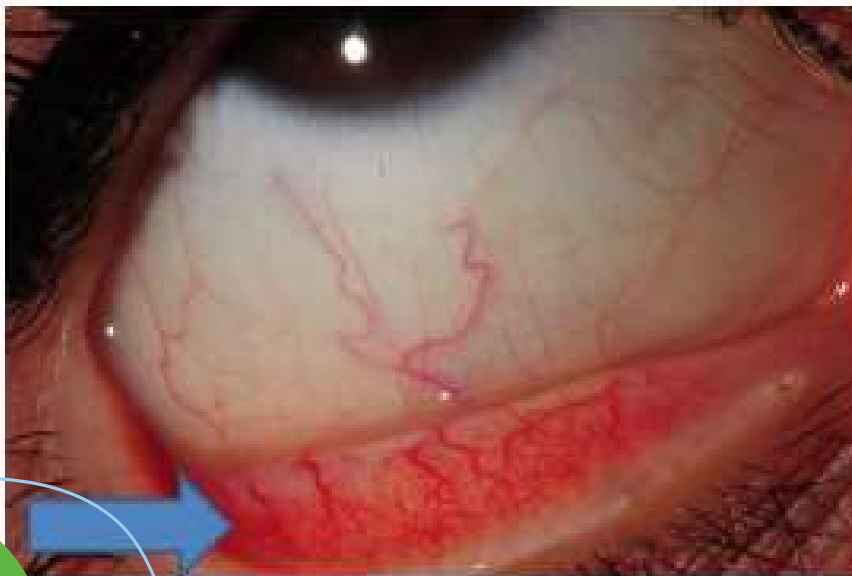- Condition in which the body does not have enough healthy red blood cells.
- Iron helps make red blood cells.
- When your body does not have enough iron, it will make fewer red blood cells or red blood cells that are too small.



White inside the lower eyelid.



Rich red blood vessels when there is no anemia.



Causes of Anemia

- Frequent and excessive blood loss
- Decrease in production of red blood cells
- High rates of blood cell destruction
- Iron deficient diet



Foods and Herbs that Support Healthy Blood

- Dark green leafy vegetables, spinach, kale, collards, chard
 - Red beets
 - Dark Red Cherries, Grapes, Plums, Blackberries
 - Oatmeal
 - Wheat grass juice
 - Chlorella, Spirulina
 - Ashwaghanda
 - Yellow Dock, Burdock, Nettle, Dandelion, Parsley, Alfalfa
- ❖ Shepherd's Purse, cayenne, rutin, known to strengthen blood vessels and may help stop blood loss.





Case Study

Idiopathic Thrombocytopenic Purpura



Jocelyn 5 Year Old Girl

Symptoms

- Mom had taken Jocelyn for the swine flu vaccine and she had become very ill and had fever and vomiting. Gave her Gatorade and 7-up.
- Then mother gave Jocelyn some children's Motrin. It was a batch that had been recalled because it had lead.
- Jocelyn woke up black and blue all over with her blood vessels breaking under her skin. Black blisters on lips and gums. Huge bruises on legs.
- Hospital diagnosis was ITP. (*Idiopathic Thrombocytopenic Purpura*)

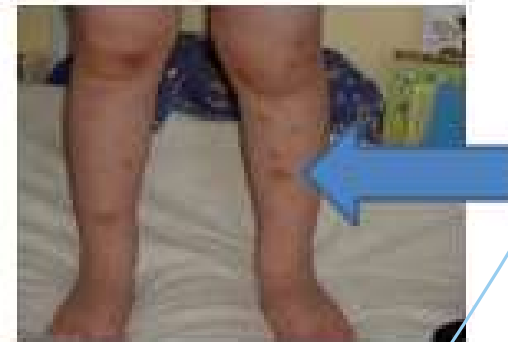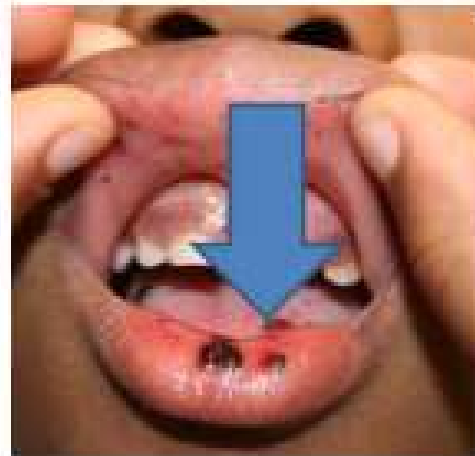
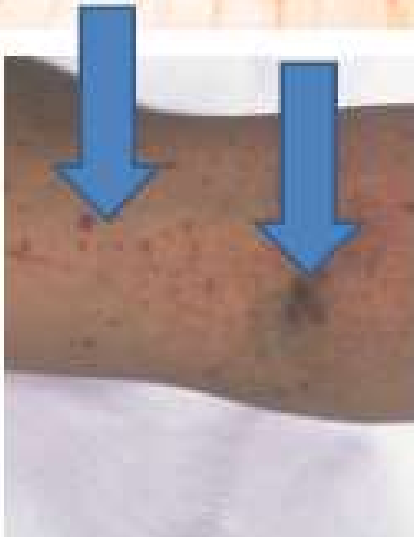

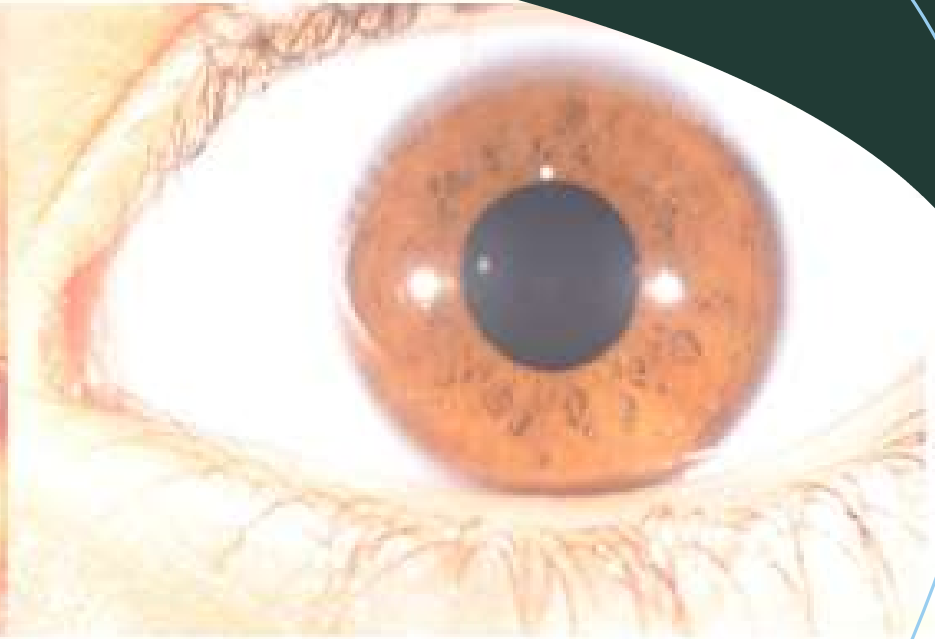
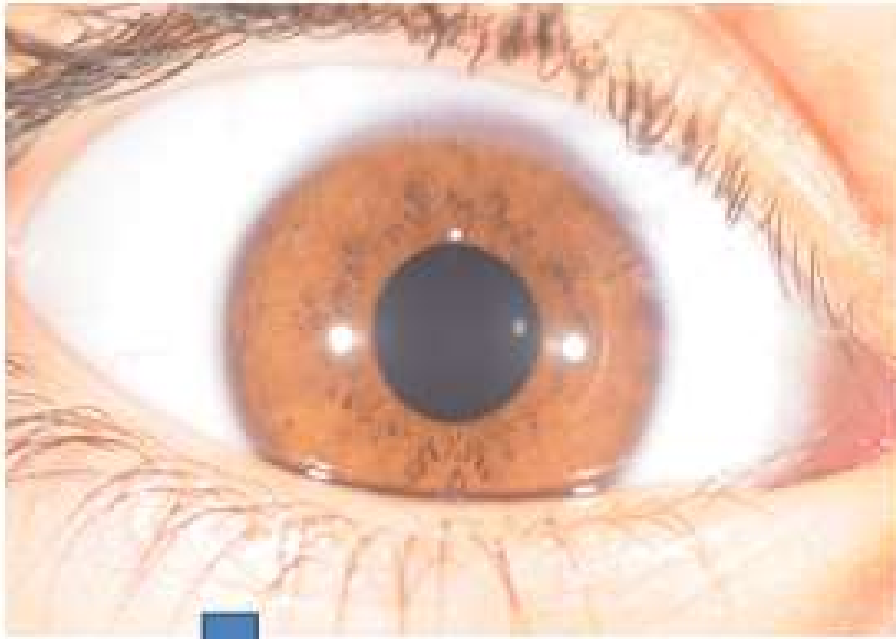Idiopathic Thrombocytopenic Purpura (ITP)

Symptoms

- ❖ Purpura/purple skin where blood has leaked under it.
- ❖ Bruises may be large or appear as tiny red dots.
- ❖ Nosebleeds, bleeding in mouth
- ❖ Blood in urine, and stool
- ❖ Severe anemia
- ❖ Extremely low platelet count (normal is 140-440). Jocelyn's was 6.
- ❖ **Often follows a viral infection leading to auto-immune disorder**
- ❖ **Medical Treatments**
- ❖ Steroids OR
- ❖ Intravenous gamma globulin (a protein with antibodies) that slows the destruction of the vessels.





Idiopathic Thrombocytopenic Purpura (ITP)

Natural Remedies for J.T.

- ❖ Rutin and Bioflavonoids
- ❖ White Oak Bark, Oatstraw, Horsetail, Rice Bran
- ❖ Chlorella, Spirulina
- ❖ Nettle, Ashwagandha, Yellow Dock tincture
- ❖ **Astragalus Tincture supports balanced immune function**
- ❖ Liquid children's multi
- ❖ Liquid minerals
- ❖ Liquid chlorophyll
- ❖ Parsley and Apple Juiced together
- ❖ Black cherry juice
- ❖ Cell Salts, Ferrum Phosphoricum



Bach Remedies and Emotional Therapies for Jocelyn

When Jocelyn was healing, she became afraid to go to school unless her mother went with her.

Bach Remedies that helped her were:

- Walnut – for fear of change
- Sweet Chestnut – to help restore joy in life
- Gorse – for children who feel there is no hope. Gorse helps restore hope.
- Play happy music in the home.
- Mother recorded a tape to play at night to assure Jocelyn that she was safe.



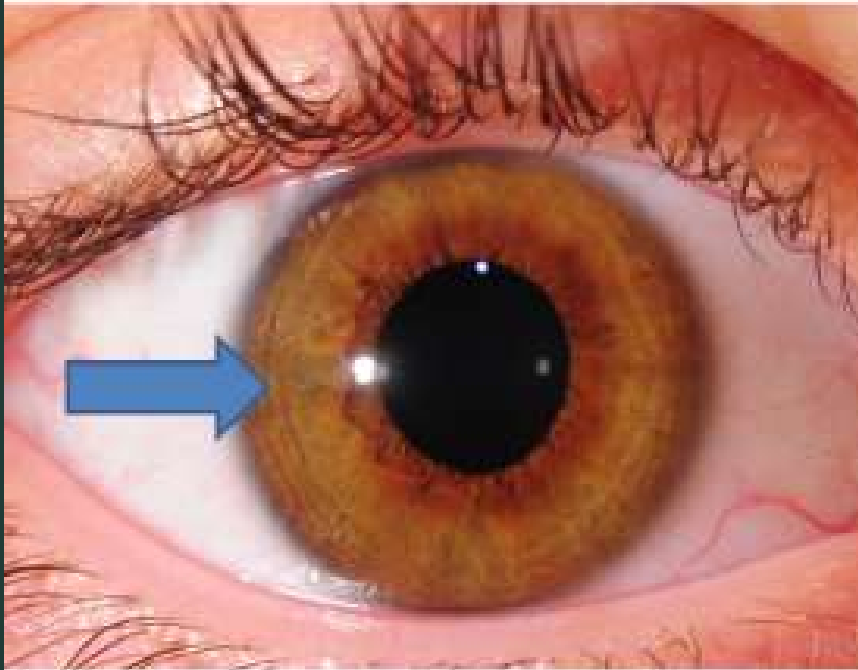
Foods for Jocelyn

- ❖ Dark green leafy vegetables, beets, blueberries, dark cherries
- ❖ Juices and shakes with these foods as well
- ❖ Organic thick rolled oats
- ❖ Beans, eggs, fish, poultry
- ❖ Use sparkling mineral water with black cherry concentrate in place of sodas
- ❖ Drink Red Clover tea to build blood

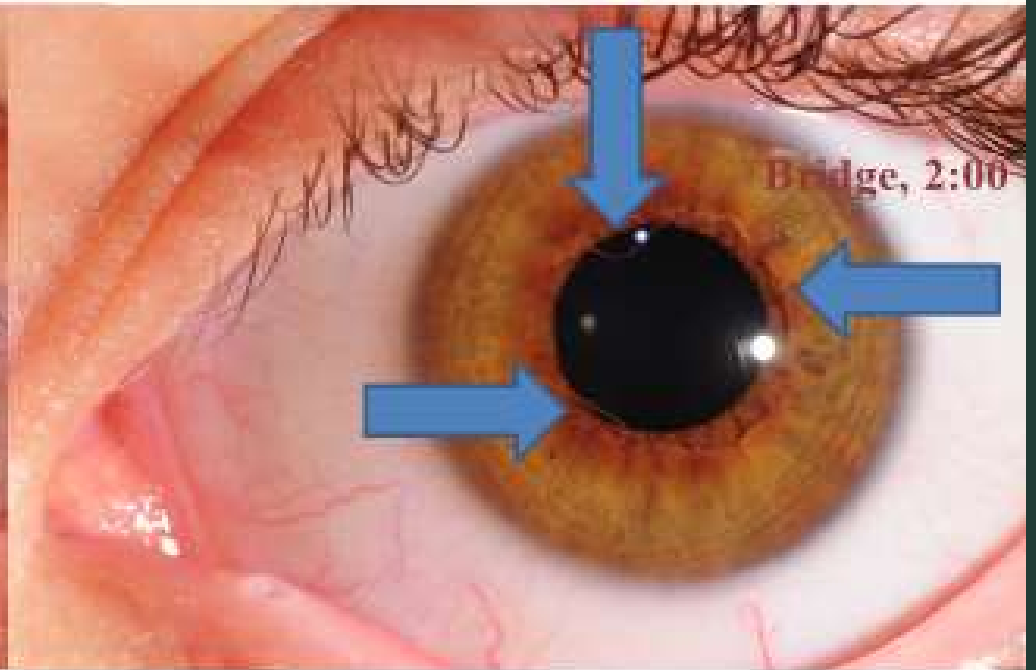
Avoid: gluten, sugar and sweeteners, sodas, pasteurized milk, soy, GMO's, preservatives, food colorings



Koch Sign/Syndrome



Medusa Lacuna



Collarette Loose Over Pupil

Koch Sign

Collarette loose, often with bridges or breaking bridges. Collarette often floating over the pupil.

Stroma of the iris is often wavy with Medusa (jellyfish) lacunae.

Tendencies:

- Difficulties in upper respiratory tract, trachea, and bronchus.
- May be prone to pneumonia, asthma, or emphysema.
- May have digestive disorders.
- Blood sugar imbalances.
- Use up minerals quickly. B vitamins also most helpful to balance nervous system.

Emotional Aspects:

- Dissatisfaction with repetitive experiences.
- Highly sensitive.
- Always searching for the new.
- Desire to travel.
- Like to do research.
- Intolerance of confinement and restraints.
- Quickly switch from excitement to exhaustion.



L.M. 11 Year Old Girl

Physical and Emotional Characteristics:

- Very slim, nervous, intense, inquisitive, thinks outside the box.
- Becomes annoyed when people do not listen to her ideas.
- Very picky eater. Difficulty with digestion. Loves and craves sweets.
- Often throat and lung congestion.
- Quickly changes from being very energetic and excited to exhaustion and silent observation.

Natural Therapies

Try to eat vegetables, fish, poultry, beans, eggs.

Try to eat fruits in place of cakes and candies.

Hair test for heavy metals showed **high cadmium, low chromium and low lithium.**

Digestive enzymes before meals

Echinacea, 20 drops, two times per day.

Chromium picolinate

DHA to support brain and nerves

Rice Bran and Oatstraw tinctures

Minerals and trace minerals

Chlorella and Parsley to pull out metals

Liquid Magnesium Orotate

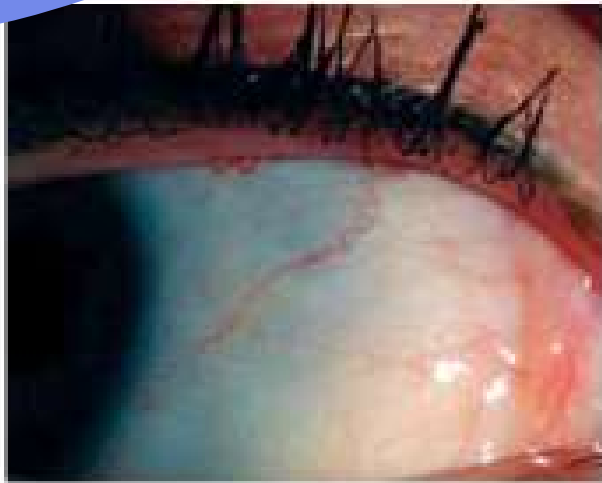Bach Flower Remedies:

Scleranthus for children that are highly sensitive and have problems with appetite. They change from over-excitement to fatigue. They live in extremes with highs followed by lows.

Vervain: for children that demand to be listened to. For children who want to pass on their ideas immediately.

Results: still a work in progress

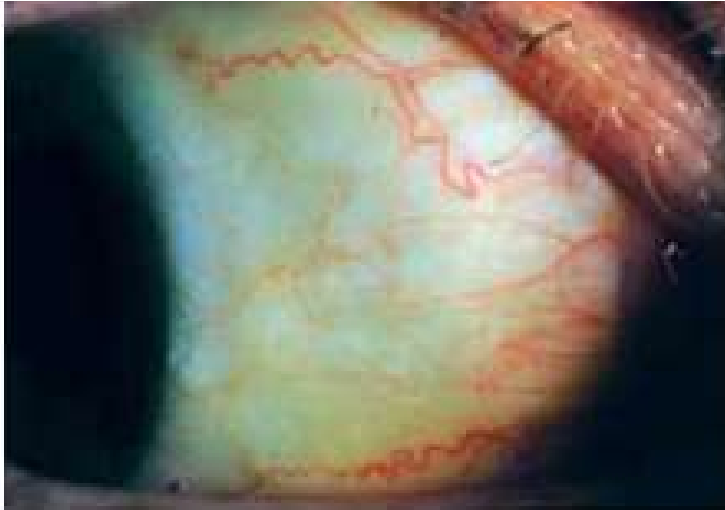




Blue Sclera

- Blue sclera in newborns is normal
- Changes to white around six to eight months of age when the sclera thickens.
- In adults, lack of exercise, fresh air, oxygen.
- Often occurs in older people and sedentary people
- Without oxygen, iron is not properly utilized
- Without oxygen, anemia may occur



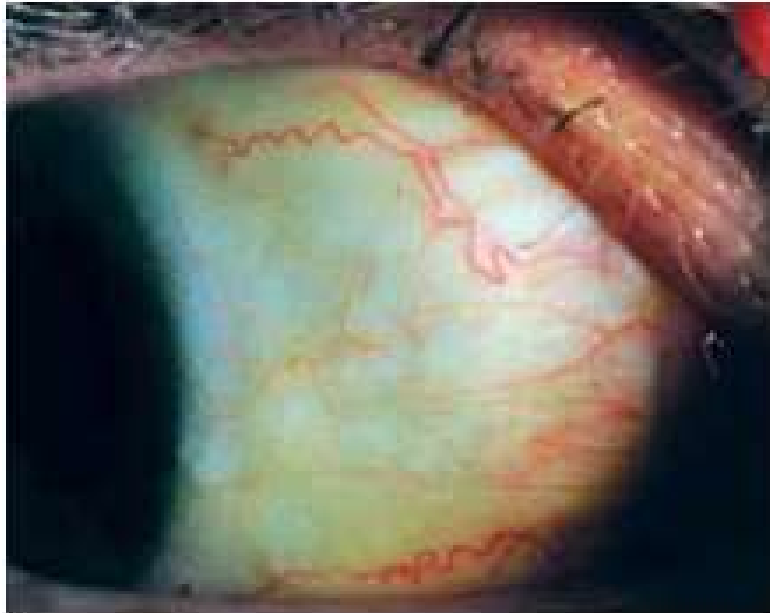


Yellow Sclera Jaundice

- A yellow sclera will show a sign of jaundice
- Caused by excess bilirubin in the blood.
- Bilirubin is produced by the normal breakdown of red blood cells.
- In a newborn, mild jaundice can be common due to the immaturity of the baby's liver, which leads to a slow processing of bilirubin.
- It generally disappears by 1 to 2 weeks of age.

- In an adult, jaundice can be caused by a number of liver disorders.





Jaundice

Caused by Liver Disorders

- Blocked bile ducts, hepatitis or cirrhosis.
- Gallstones, blood disorders, infections
- Use of certain drugs
- Check to see if skin is also yellow

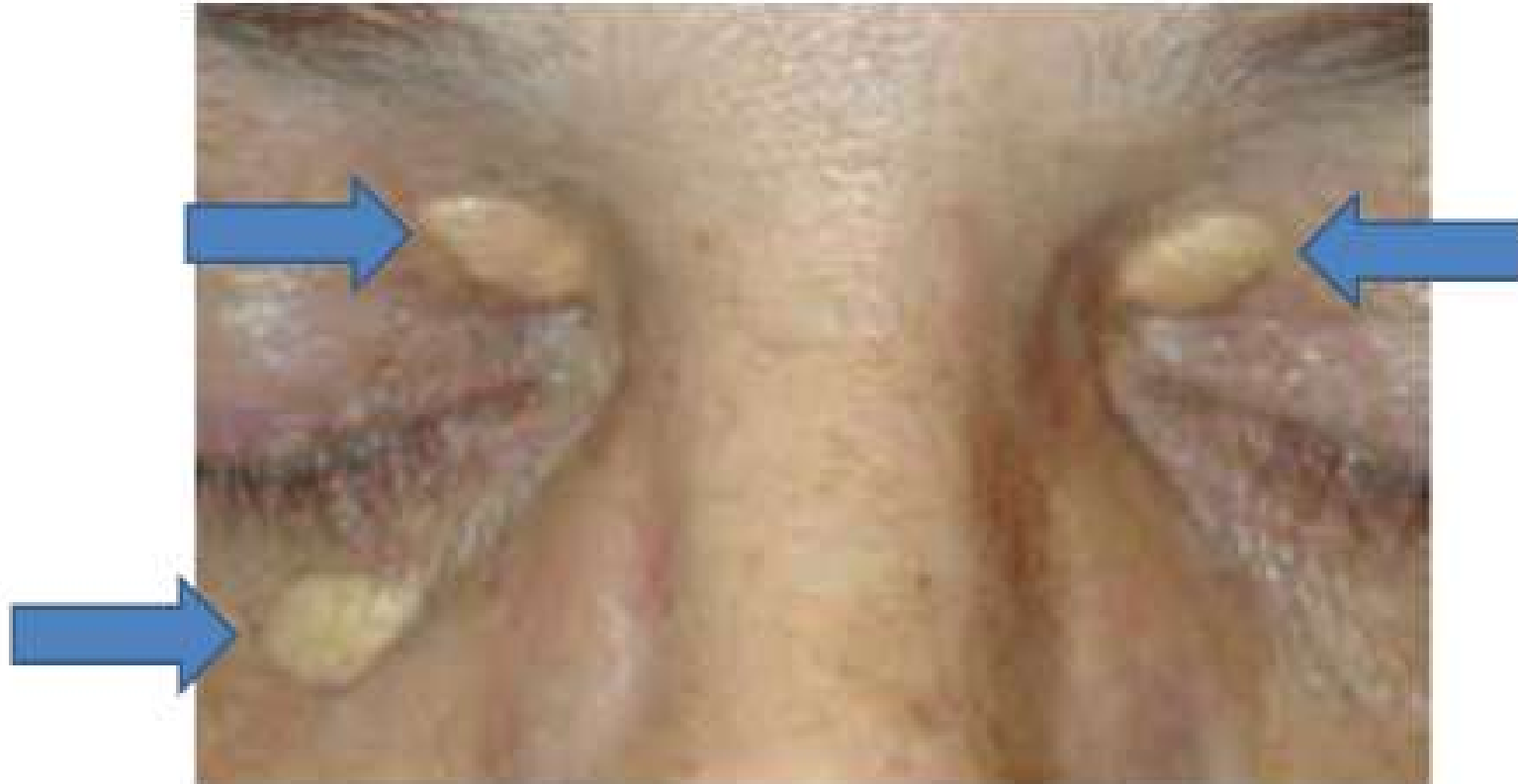

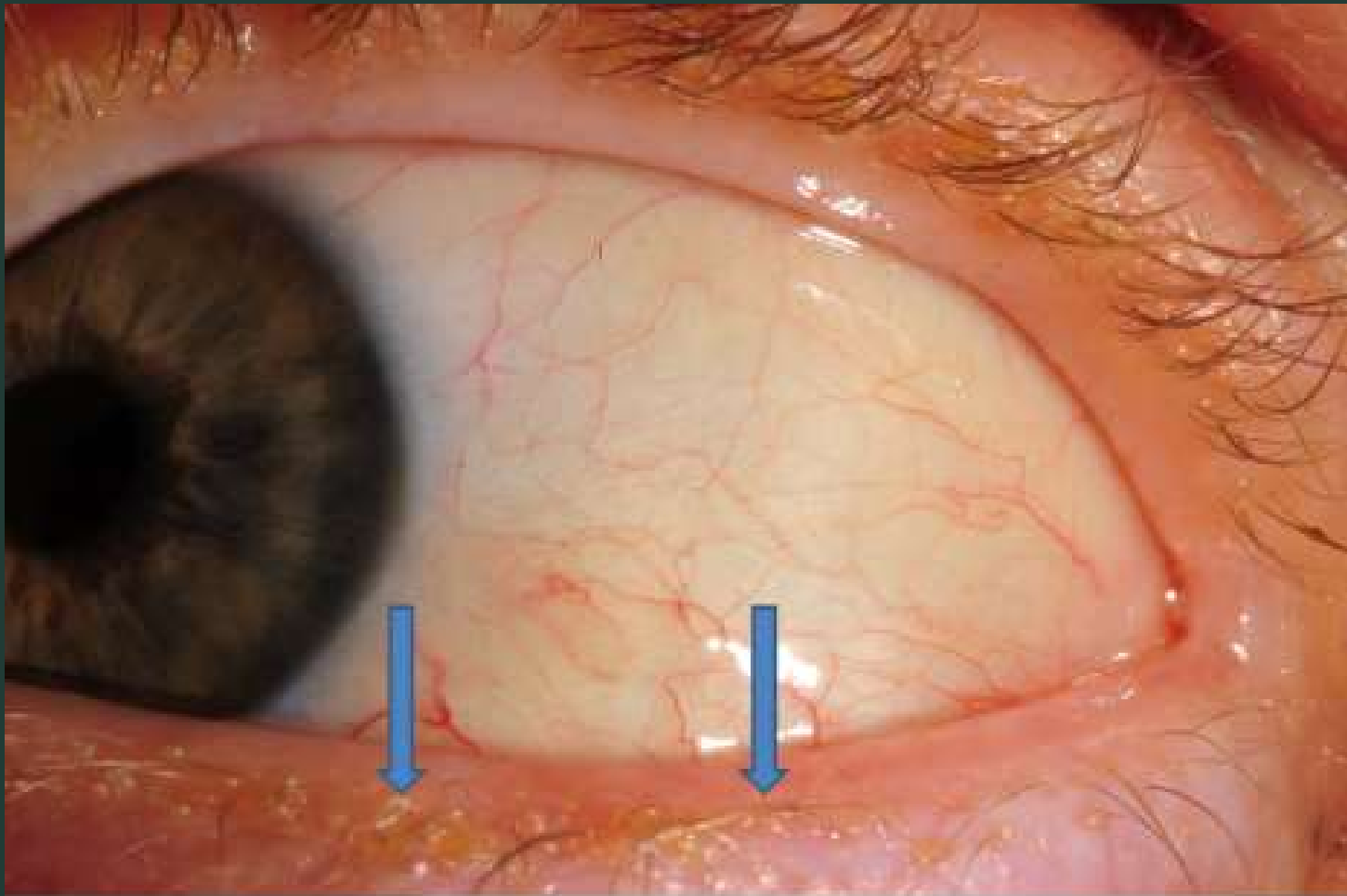
Xanthelasma

- Skin condition with yellow lipid deposits in the skin of the eyelids.
- They look like yellowish raised patches of tissue often near the canthus (at the corner of the eye near the nose).
- Occur most commonly in the elderly.
- May be an indication of elevated cholesterol or triglyceride levels.
- Possible concern with assimilation of fats which can lead to plaque in the arteries, heart disorders, and hypoglycemia or diabetes.
- In addition to the iris analysis, blood work should be done.



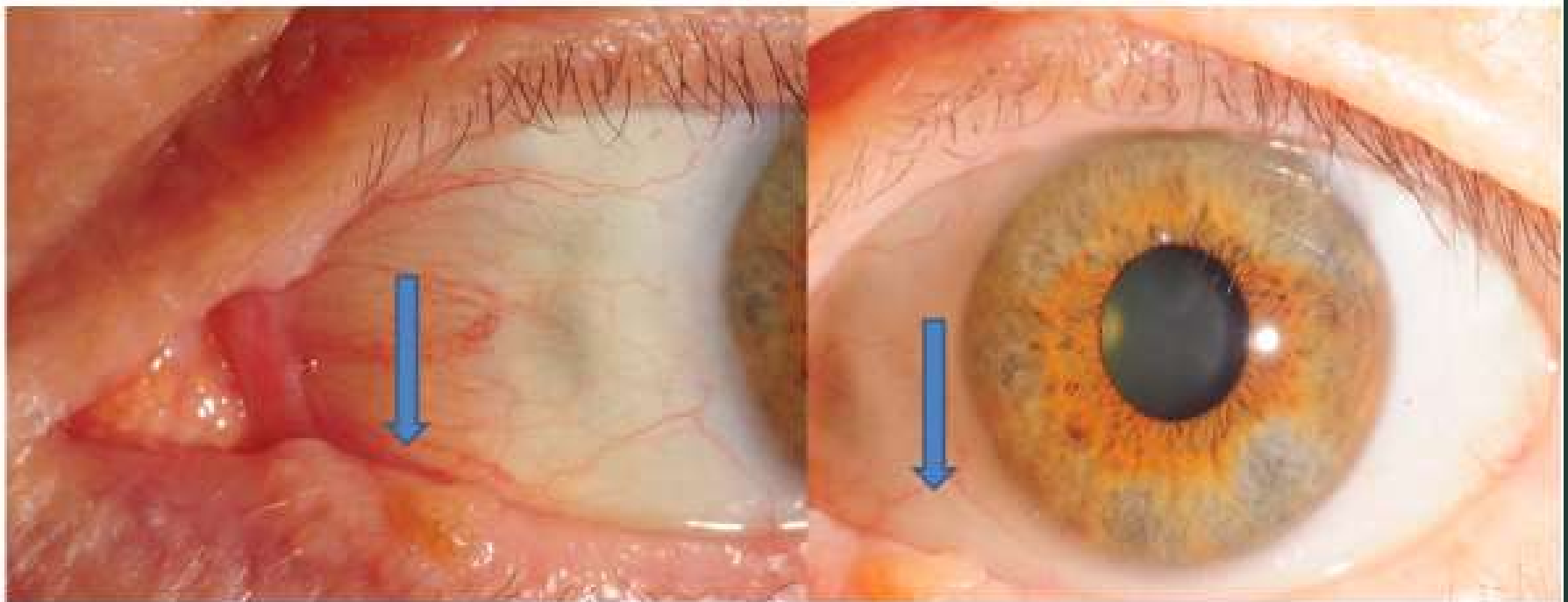
Xanthelasma





Xanthelasma

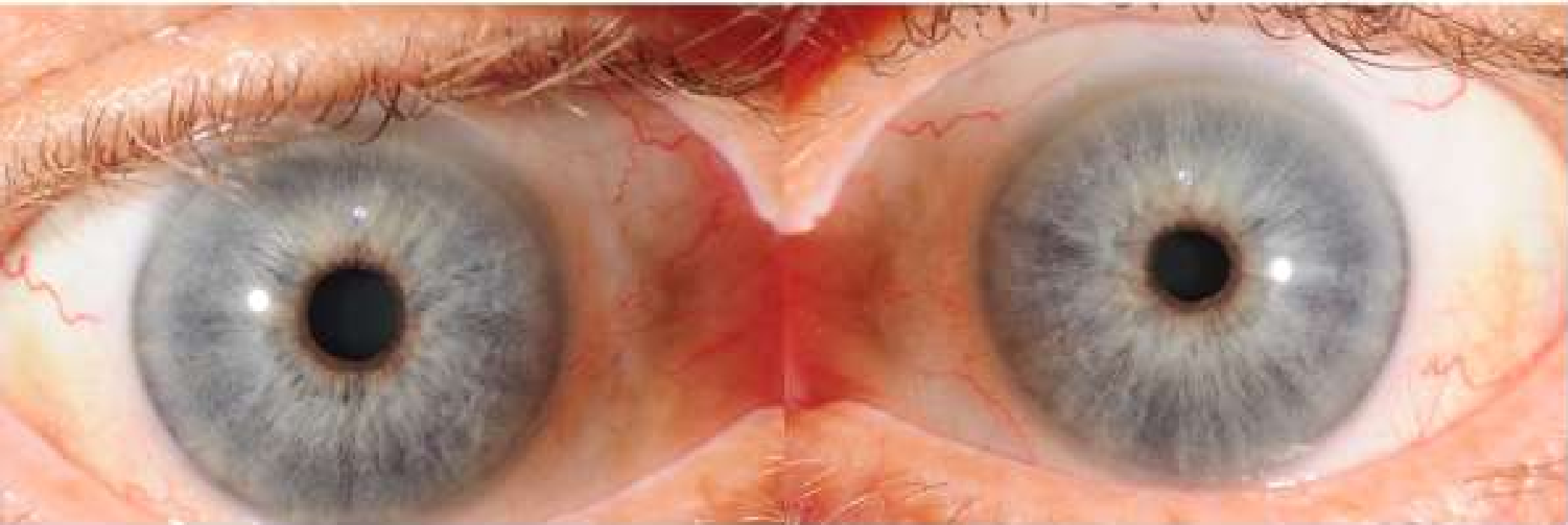




Xanthelasma

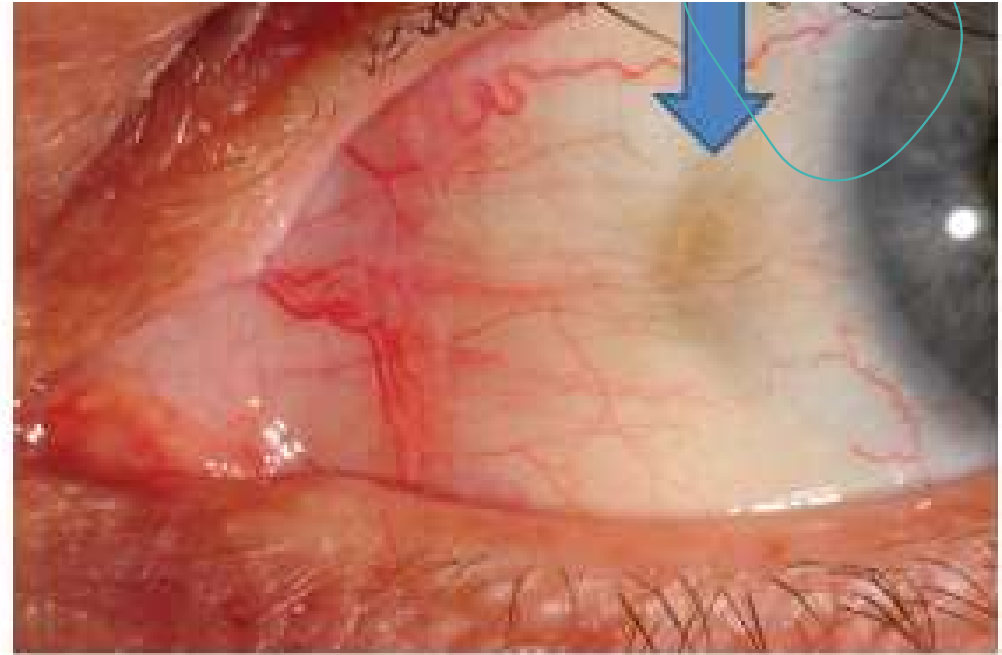
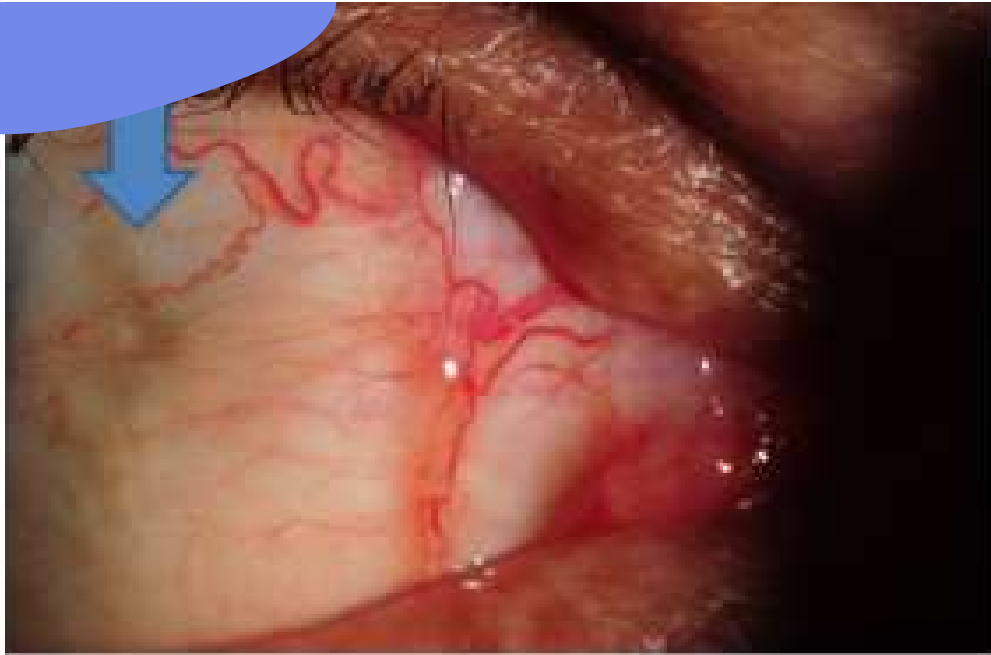- Support liver and digestion with enzymes, bitter greens, cinnamon, garlic, chickweed
- Fiber including chia and flax seeds, oat bran
- Castor oil applications may be helpful





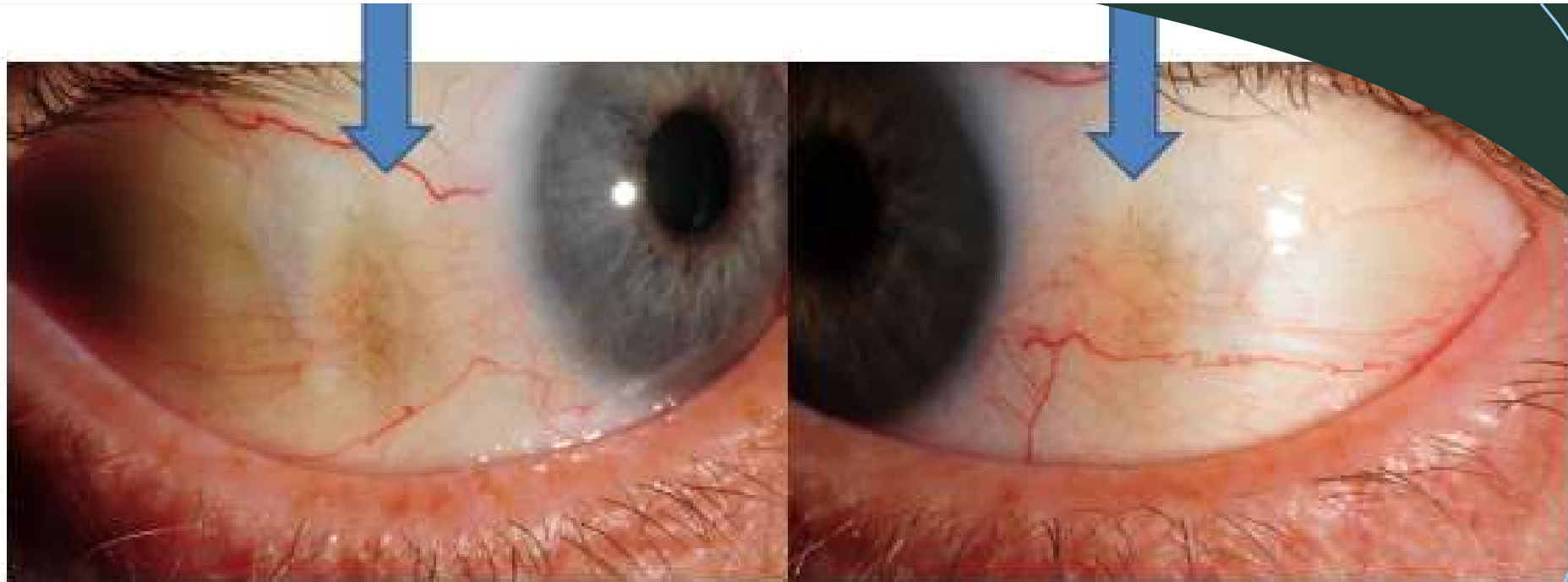Male, age 75, smoker





- These opaque glassy looking patches appear in the sclerae of the elderly. They are a sign of toxicity in the tissues of the body.
- Often seen in long term heavy smokers as well as in people that have used a lot of alcohol, coffee, and drugs.
- These blue gray patches can occur on the medial or lateral sectors of the sclera.



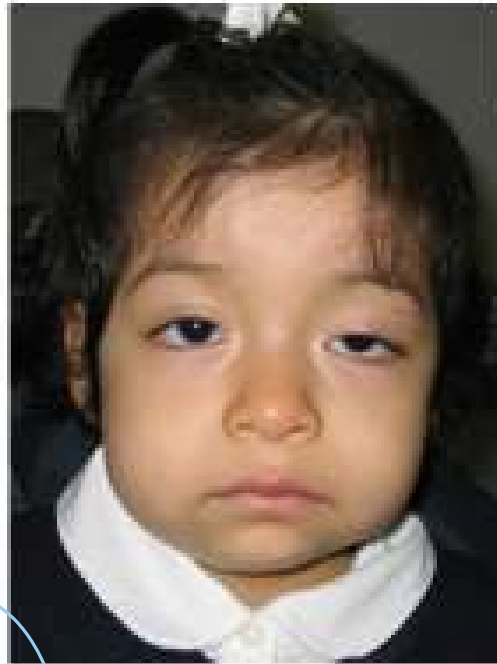
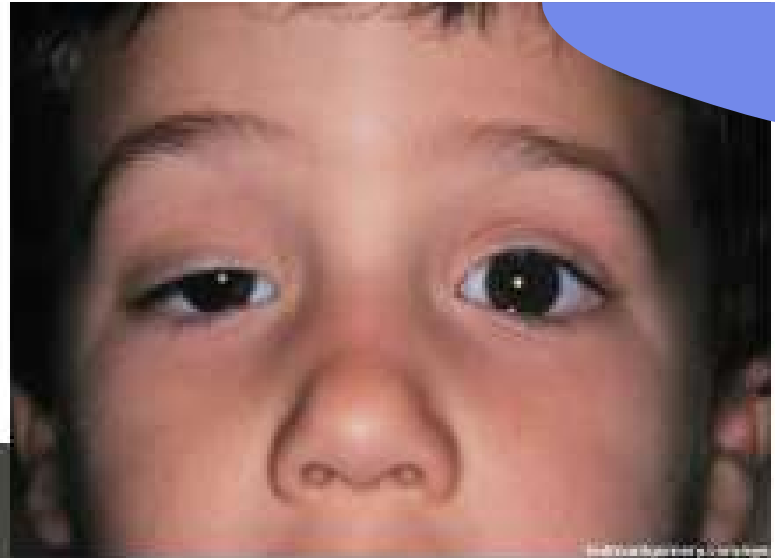
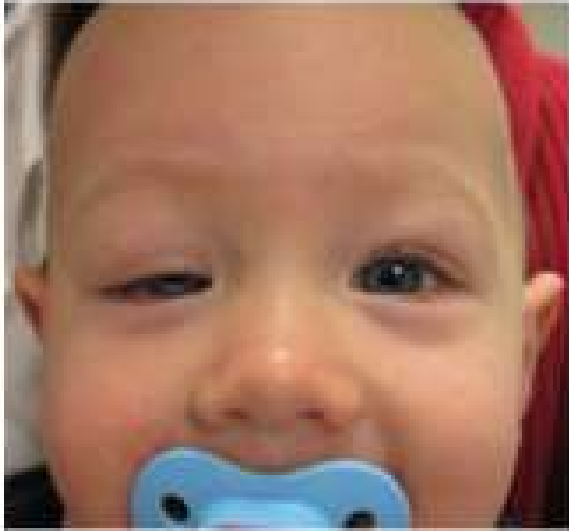
■ Lung and liver toxicity

- Support lungs with lobelia, cayenne, lemon, elecampane, mullein, yerba santa
- Support liver with milk thistle, dandelion, burdock, turmeric, bitter greens
- Support the release of grief and encourage self esteem and love of self



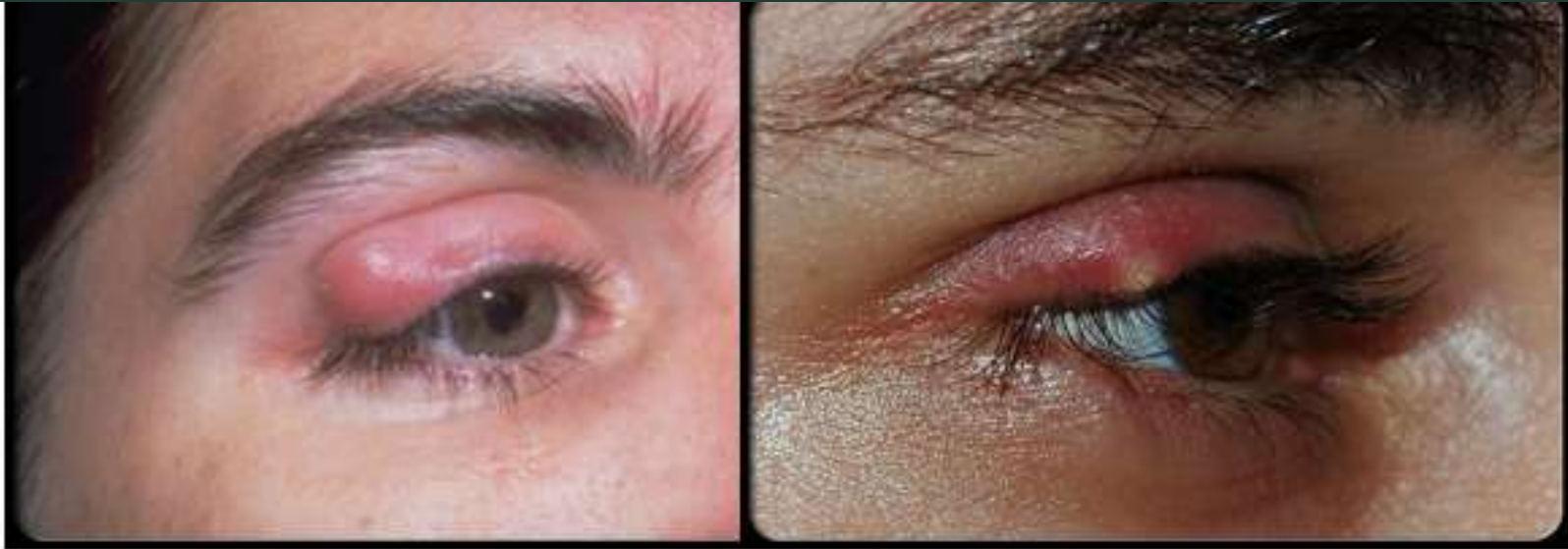Ptosis



Ptosis

- ❑ Aging results in loosening of the skin and ligaments which keep the eyelid open thus resulting in a droopy eyelid.
- ❑ Eye surgery (e.g. cataract removal) can result in loosening of the ligaments which help keep the eyelid open. Neck surgery infrequently can interrupt pathways in the spinal cord resulting in ptosis.
- ❑ Eye or eyelid trauma
- ❑ Cancers of the eyelid or nerves which control the eyelid
- ❑ Certain muscle diseases (muscular dystrophy)
- ❑ Myasthenia Gravis (MG) or ocular MG (chronic autoimmune neuro-muscular weakness)
- ❑ Nerve dysfunction from trauma, diabetes, infection, or inflammation
- ❑ Stroke
- ❑ Multiple Sclerosis



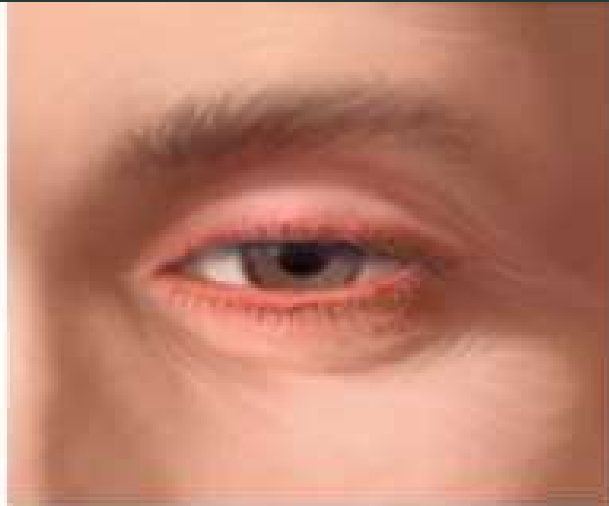

Chalazion or Stye

- A chalazion is a lump on the eyelid caused by a swelling of an oil gland.
- A stye is a swelling closer to the eyelashes caused by infection.

- A warm potato poultice has proven to be most helpful.
- Blend potato in food processor. Warm raw potato in a pan or in the oven.
- Place warm potato mush directly on the area.
- Colloidal silver may be used beneficially as well.



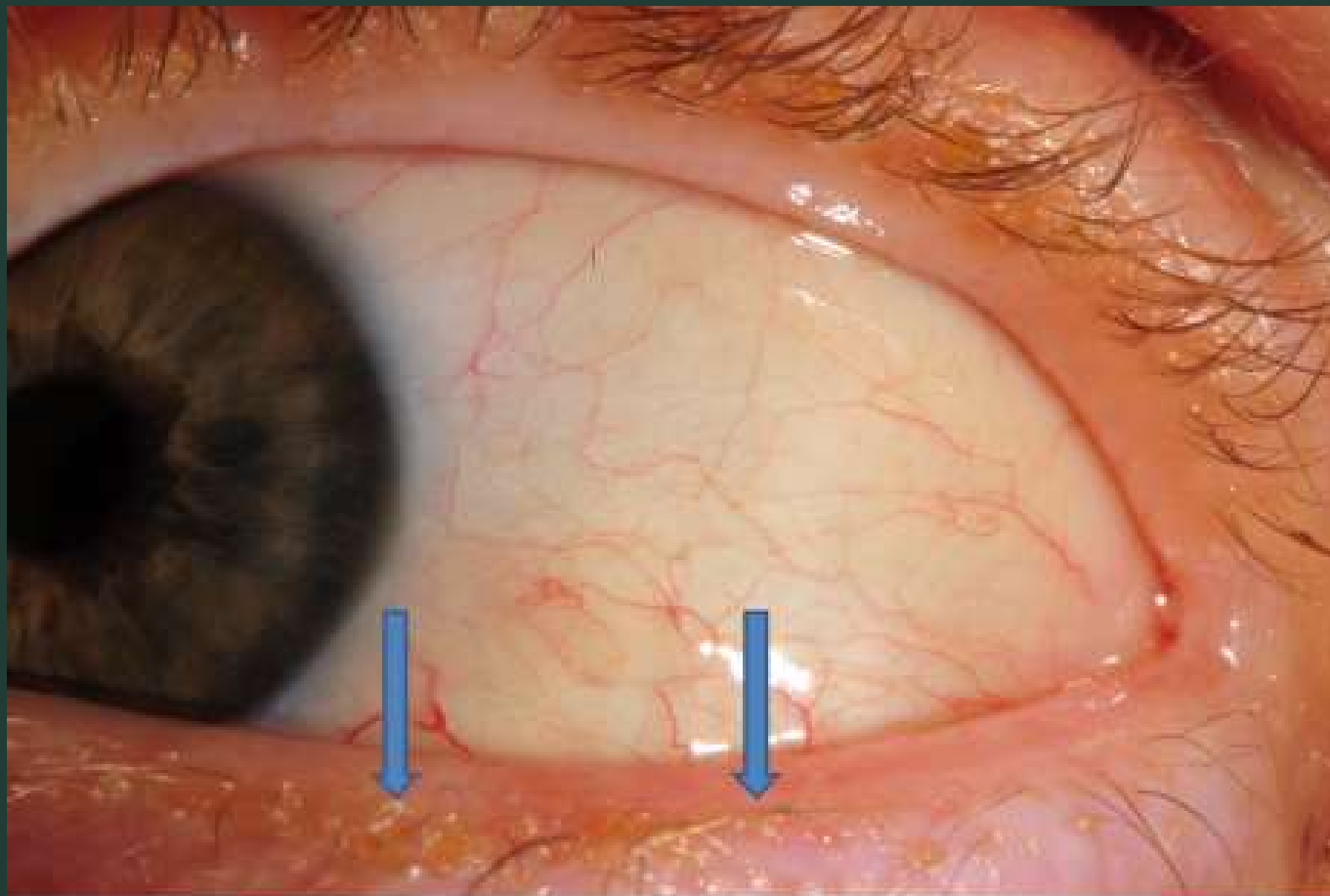


Blepharitis

- **Blepharitis is an inflammation of the eyelids in which they become red, irritated and itchy.**
- **Dandruff– like scales form on the eyelashes.**
- **Common disorder caused by either bacteria or skin condition such as dandruff or rosacea.**

- **Vitamin A and zinc have proven to be most helpful.**
- **Warm olive oil mixed with colloidal silver has also been used.**





Blepharitis

Congestion and dysfunction of the oil glands.

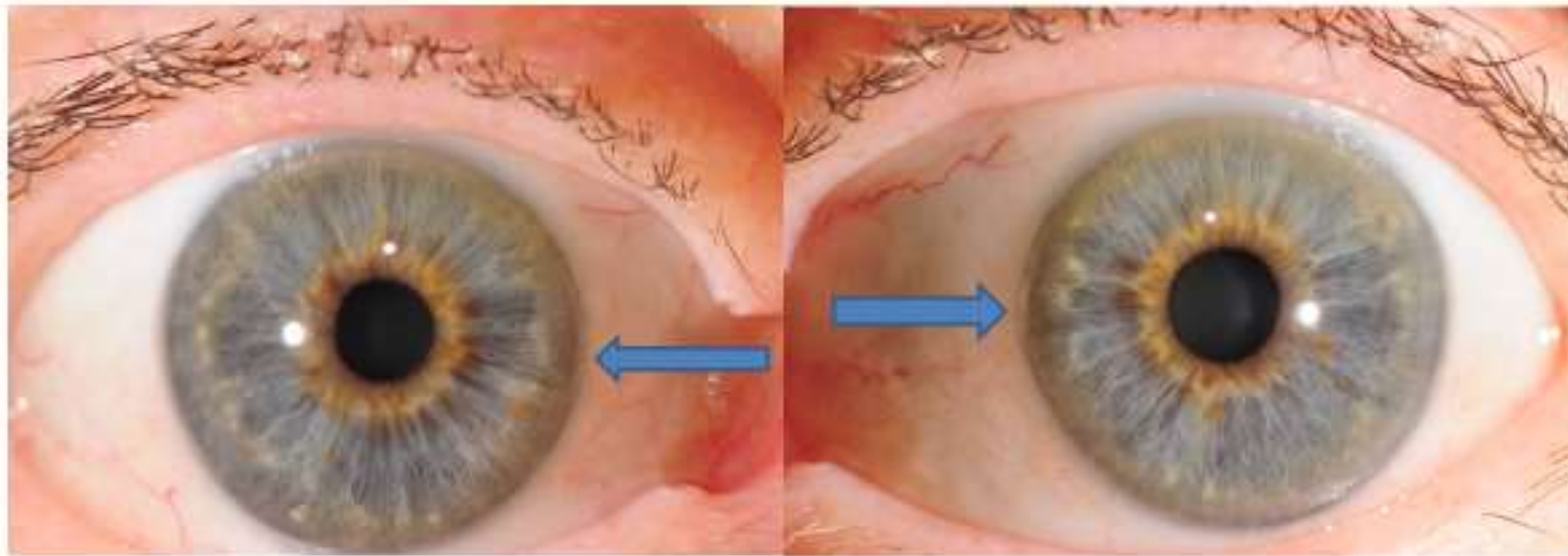


Vogt's Limbal Girdle

Vogt was the first to describe the limbal girdle – white, arc-like opacities in the cornea central to the limbus in the 3 or 9 o'clock positions. What Vogt described was a type of calcific band with a peripheral clear zone.

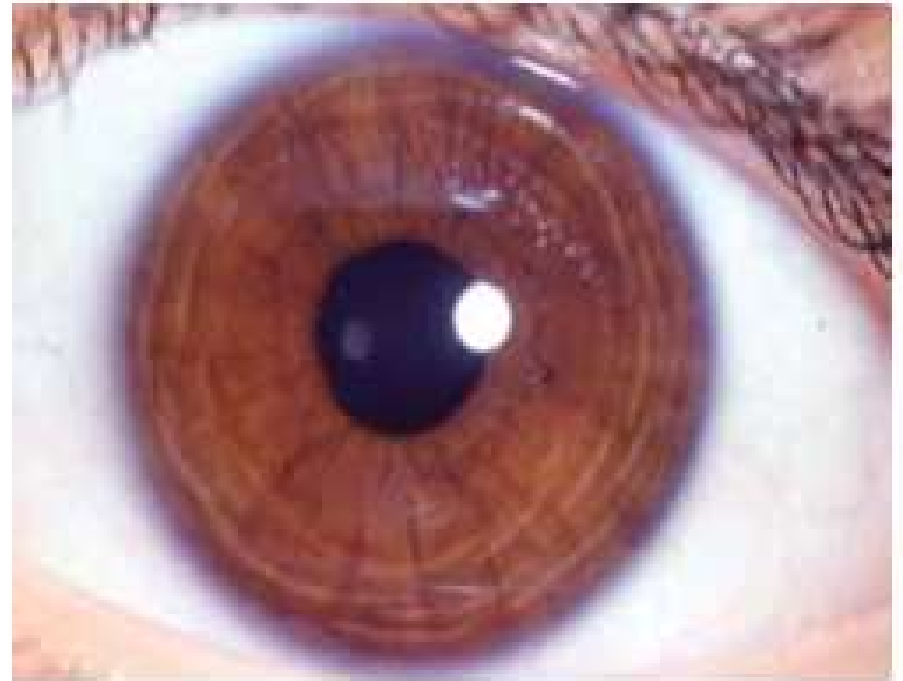
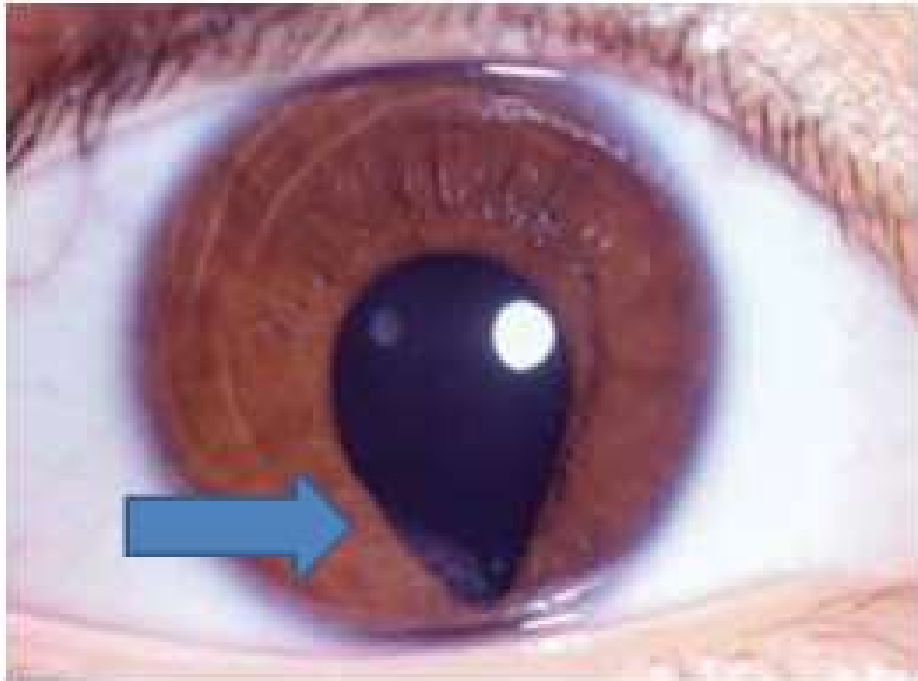
This is different from corneal arcus or lipids in the cornea.

Ophthalmology by Myron Yanoff, MD and Jay S. Duker, MD



- Ask questions about osteopenia or osteoporosis in the family.
- Always check thyroid and parathyroid areas.
- Ask questions about hardening of the arteries.
- Check heart reaction fields as well.
- pH test in these cases is always important. Acids pull calcium from the bone.





Coloboma



Coloboma

- The word coloboma comes from the Greek word, koloboma, which means defect.
- Usually in one eye, but can occur in both eyes.
- Gap is there at birth because certain structures of the eye did not develop properly during the early stages of prenatal development.
- Little effect on the vision. However, because the pupil is larger, too much light may enter the eye and cause discomfort and possibly distort the image they see.
- These people should wear sun hats and sunglasses.
- Develops in the eyes of about 1 in 10,000 babies.
- May or may not be genetic.



5 Year Old Girl with Coloboma

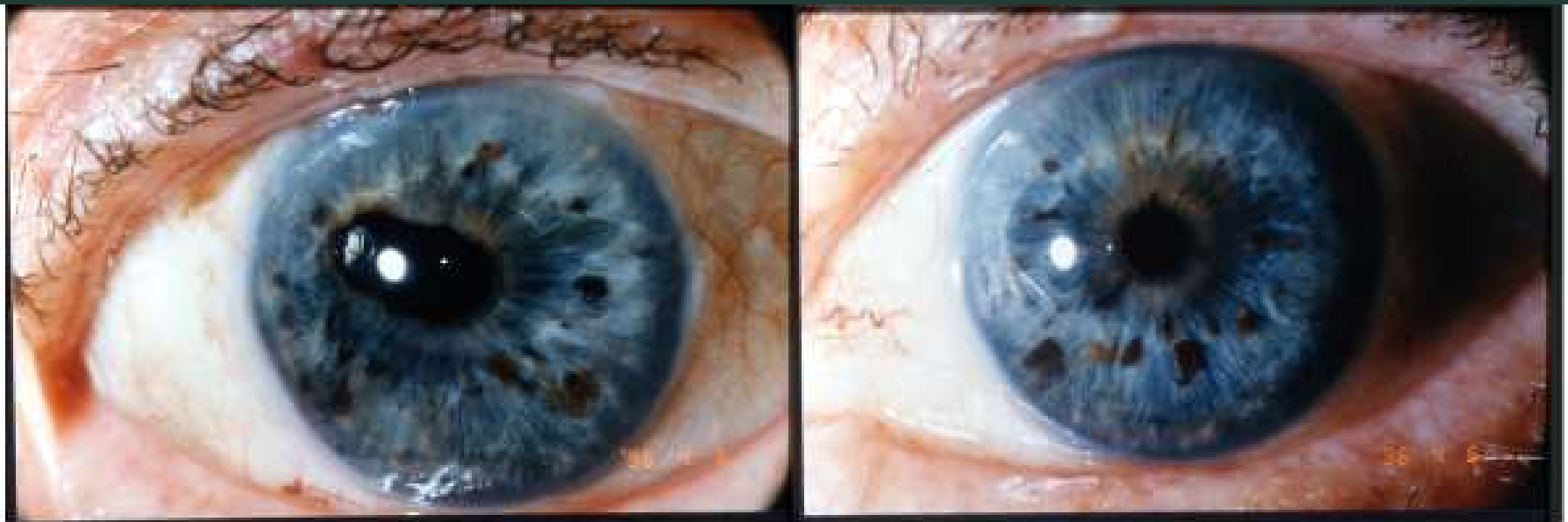Symptoms:

- In this little girl, the pupil extends into the reaction fields of the adrenal gland, kidney, thigh, knee, leg, and foot.
- In addition, she has contraction furrows.
- She was very hyperactive in school and had difficulties paying attention.
- No problems with vision.

Health Suggestions:

- B vitamins, minerals, and Holy Basil herbal tincture to help support the nervous system and soothe the adrenal glands.
- DHA for brain and nervous system
- Avoid caffeine, sugars, artificial sweeteners, sodas, food dyes, and food preservatives.
- Drink plenty of purified water.
- Raw vegetable juice with greens to neutralize acids and include parsley to help strengthen kidneys.
- Reduce stimuli in areas of learning. Play gentle music. Let her dance!

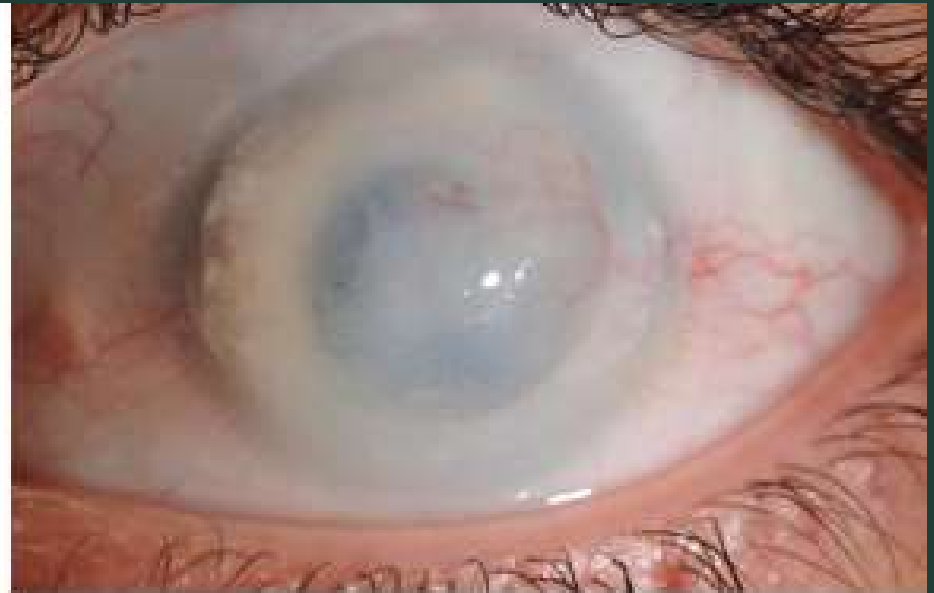
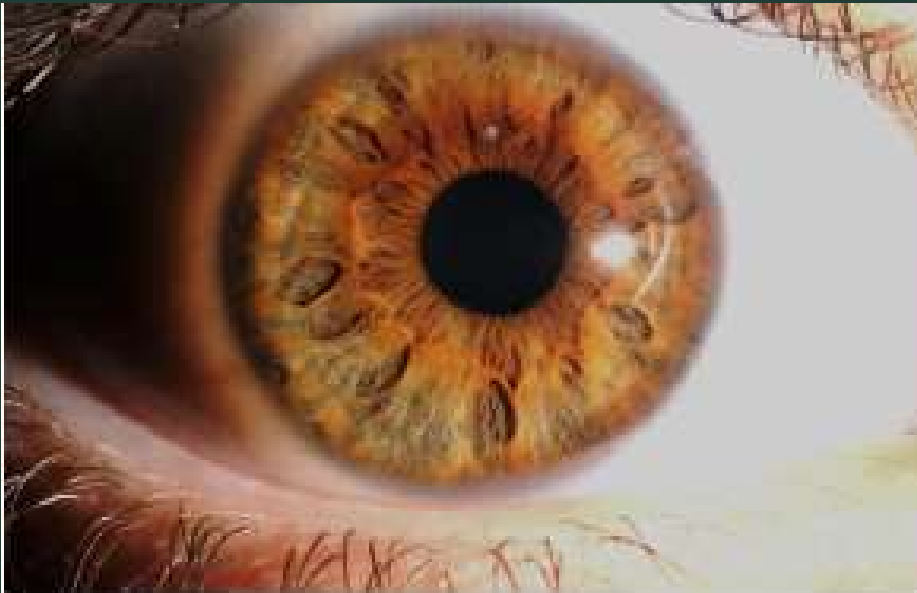


Cancer of the Eye and Eye Surgery

- The most common cancer that occurs in the eye is **melanoma**. The cells that become **cancerous in the eye with melanoma are the melanocytes** where the pigment is made.
- Melanomas can start in the iris, the conjunctiva covering the sclera, or the eyelids.
- When a person has had surgery to remove melanoma from the iris, it is called *iridectomy* and will look like a portion of the iris has been removed.
- Note the black hole in the superior sector of this iris on the left.
- It may appear to some to look like a lacuna, but careful observation will show that there are no fibers inside the black hole. The iris on the left has had a considerable amount of the iris cut away.





Young man, 18 years old.

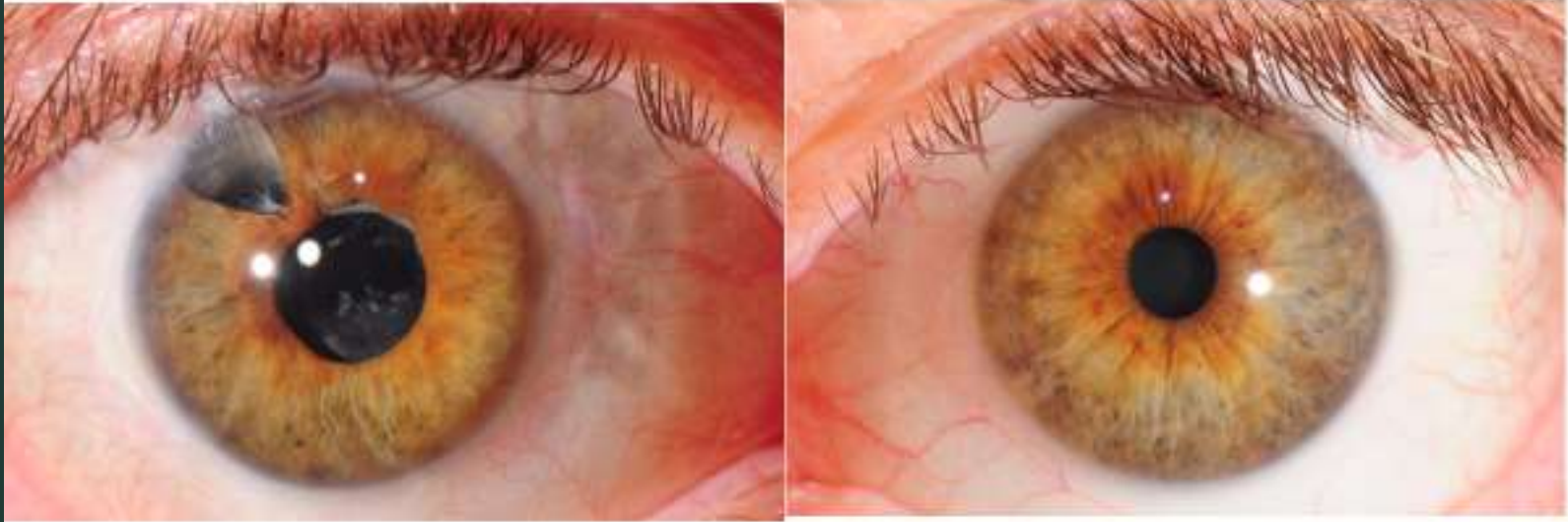Eye injury that occurred at age five.

The eye is still useful in that he can see light in the periphery.

It helps him to keep his balance.

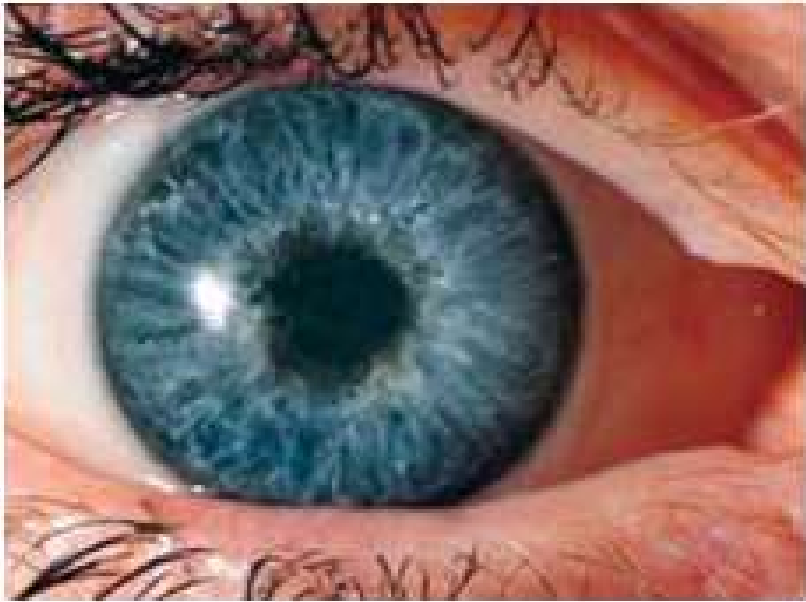

Iritis, Glaucoma, Cataract

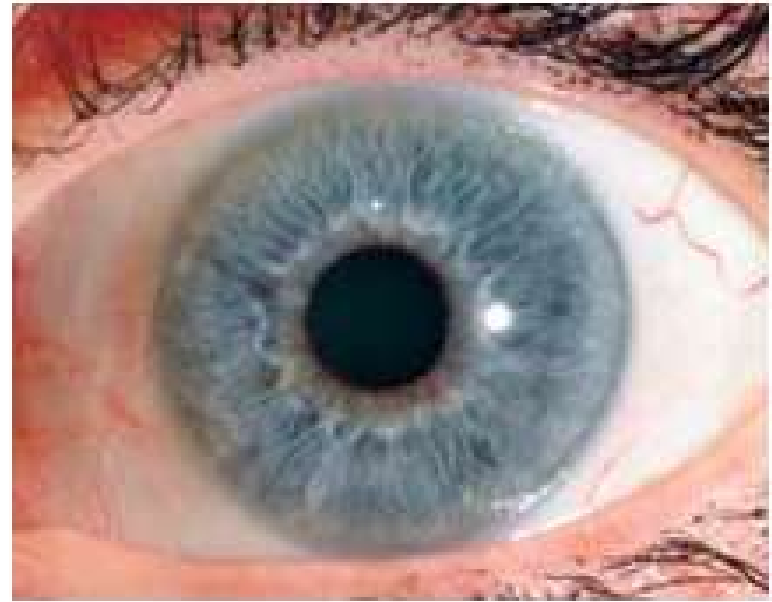


- Daniel was exposed to Agent Orange in Vietnam and got Iritis or inflammation of right iris, glaucoma, and cataract. Received many vaccinations.
 - After 12 years, the optic nerve died.
 - Lens was replaced with 10% vision.
 - Mercury and lead levels very high.
-
- Support eyes with eyebright, bilberry, parsley, rosehips, cayenne
 - Improve immunity with astragalus, colloidal silver
 - Remove mercury and lead with cilantro, parsley, chlorella, rose hips



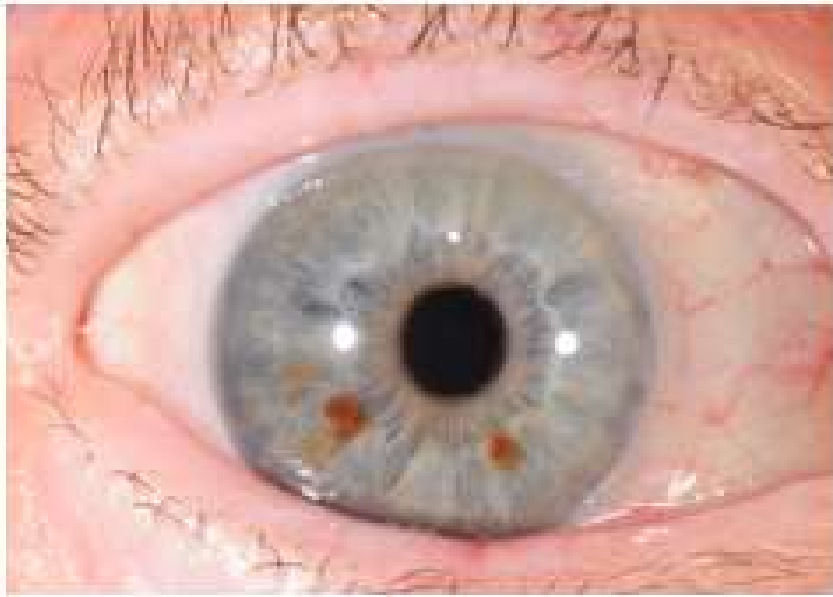

Prosthesis

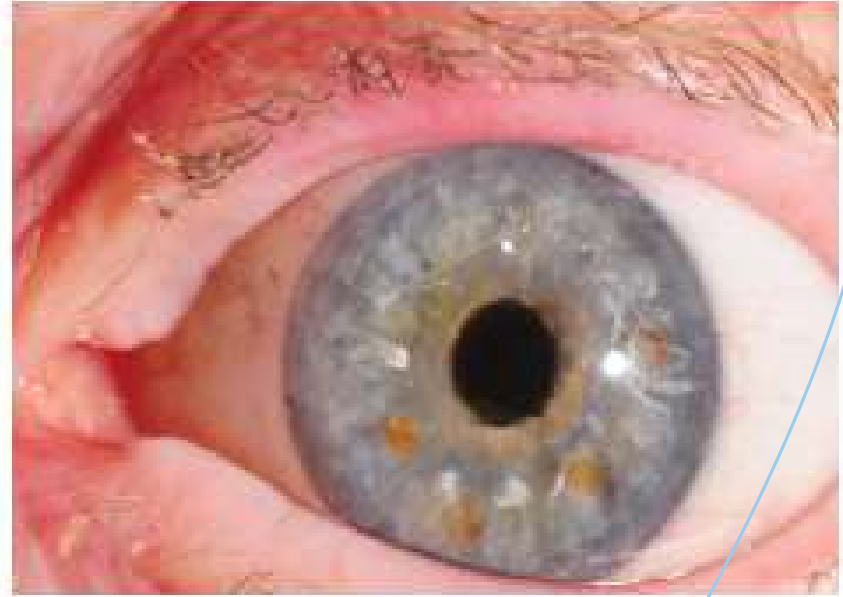

Normal Iris





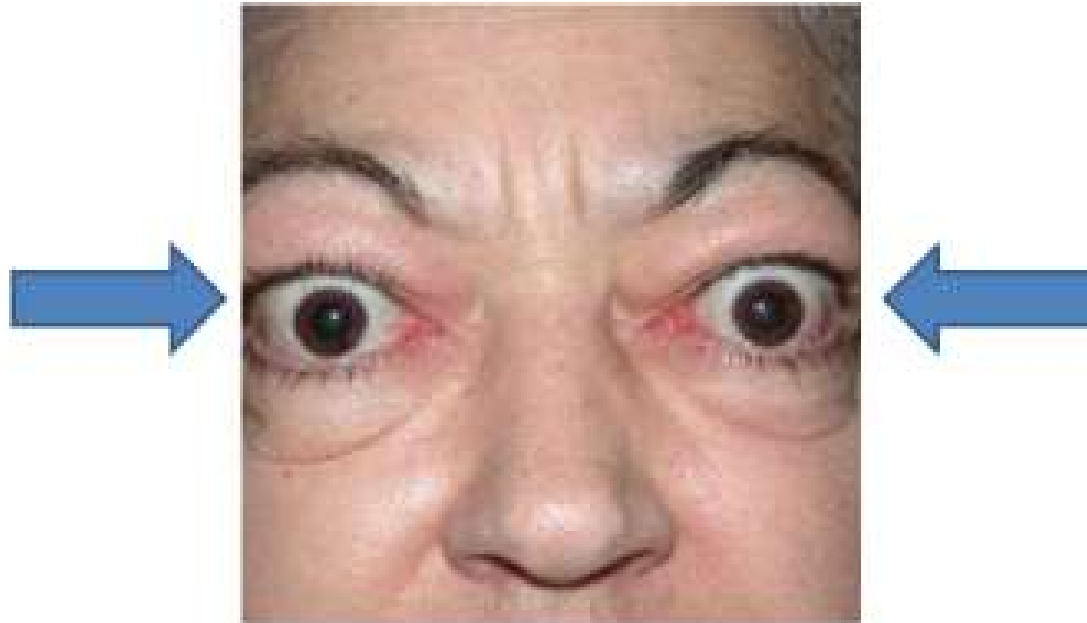Normal Iris



Prosthesis



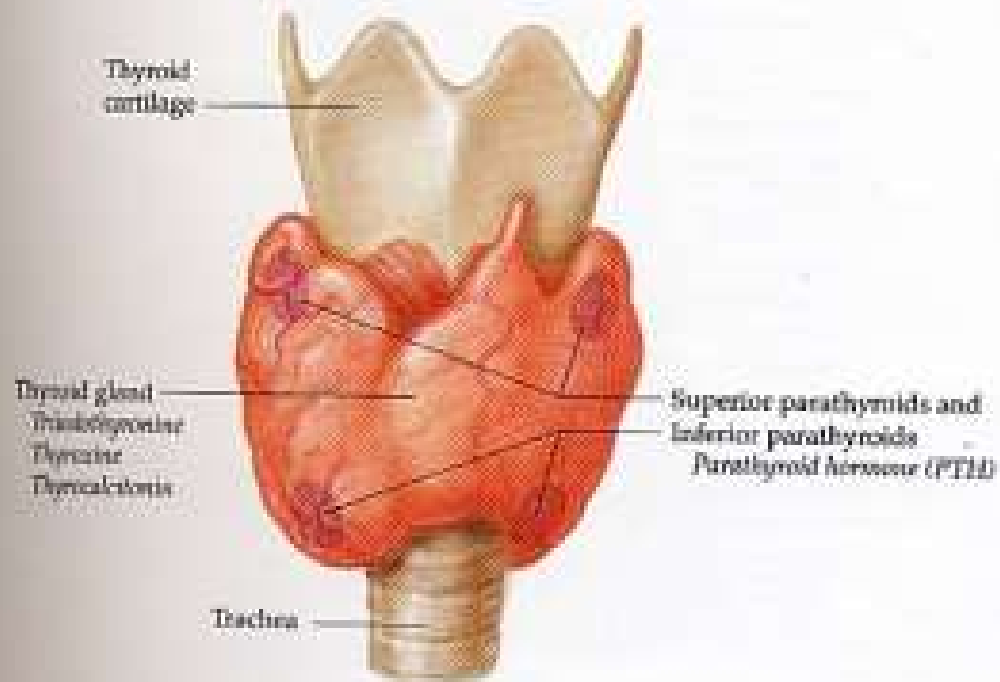
Grave's Ophthalmopathy



Hyperthyroidism



Thyroid and Parathyroid Glands



Thyroid Disorders



Grave's Ophthalmopathy

- Autoimmune inflammatory disorder affecting the orbit around the eye with upper eyelid retraction, swelling, redness, and bulging eyes.
- It is part of a systemic process with variable expression in the eyes, thyroid, and skin.
- Caused by autoantibodies that bind to tissues in those organs.
- Most common in Grave's Disease or **Hyperthyroidism**.
- The autoantibodies target the fibroblasts (cells that synthesize collagen) in the eye muscles, causing fat cells and muscles to expand and become inflamed. Veins become compressed, and are unable to drain fluid, causing swelling
- Females are four times more likely to develop ophthalmopathy than men.



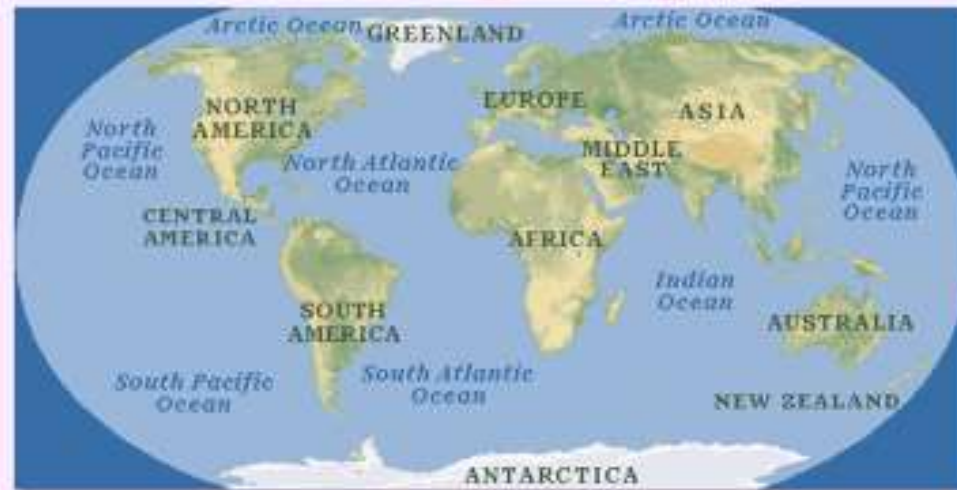Thyroid/Eye Support

- Seaweeds
- Alkaline foods/fresh raw greens and green juices
- Cruciferous vegetables
- Lemon Balm, Motherwort, Bugleweed
- Astragalus and Marshmallow Root
- Bilberry, Eyebright
- Bioflavonoids, Rutin
- Avoid cigarettes and alcohol
- Potato and cucumber poultices
- Sing!



The International Iridology Practitioners Association Founded in 1982 is Taking Iridology into the Future

www.iridologyassn.org



THE UNIVERSAL MODEL

The International Iridology Practitioners Association was founded for the purpose of increasing and diffusing knowledge concerning the art and science of Iridology and to provide a forum for the exchange of information and research with the goal of promoting excellence in international Iridology standards.

IIPA's vision is to have iridology integrated into the healthcare system worldwide.



Rarely Seen Ocular Signs Disclaimer

The information on this CD is provided for informational purposes only and is not a substitute for professional medical advice, diagnosis, treatment or medical training. The illustrations and information on this CD are not intended to replace the services of a physician, to diagnose a medical and/or health condition, or to recommend a course of treatment. If a reader suspects that he or she has a problem, a licensed healthcare provider should be consulted immediately. NEVER DISREGARD PROFESSIONAL MEDICAL ADVICE OR DELAY SEEKING MEDICAL TREATMENT BECAUSE OF SOMETHING YOU HAVE READ ON THIS CD. THE AUTHOR OF THIS CD IS NOT RESPONSIBLE NOR LIABLE FOR ANY ADVICE, COURSE OF TREATMENT, DIAGNOSIS OR ANY OTHER INFORMATION PROVIDED ON THIS CD, AND SPECIFICALLY DISCLAIMS ALL RESPONSIBILITY FOR ANY LIABILITY, LOSS OR RISK, PERSONAL OR OTHERWISE, WHICH IS INCURRED AS A CONSEQUENCE, DIRECTLY OR INDIRECTLY, OF THE USE AND APPLICATION OF ANY OF THE INFORMATION ON THIS CD. The statements concerning individuals on this CD are solely from the experience of the respective individuals. The results alluded to by individuals are not typical and may be the result of numerous individual factors. Results may vary. Iridology is an evolving science and art form. The information presented on this CD, although drawn from the most up-to-date research, may become outdated or incomplete. The current information presented is based on "Comprehensive Iridology." Comprehensive Iridology™ is the type of iridology taught and recognized by the International Iridology Practitioners Association or IIPA. The information is also based on research in the field of nutrition and ophthalmology.