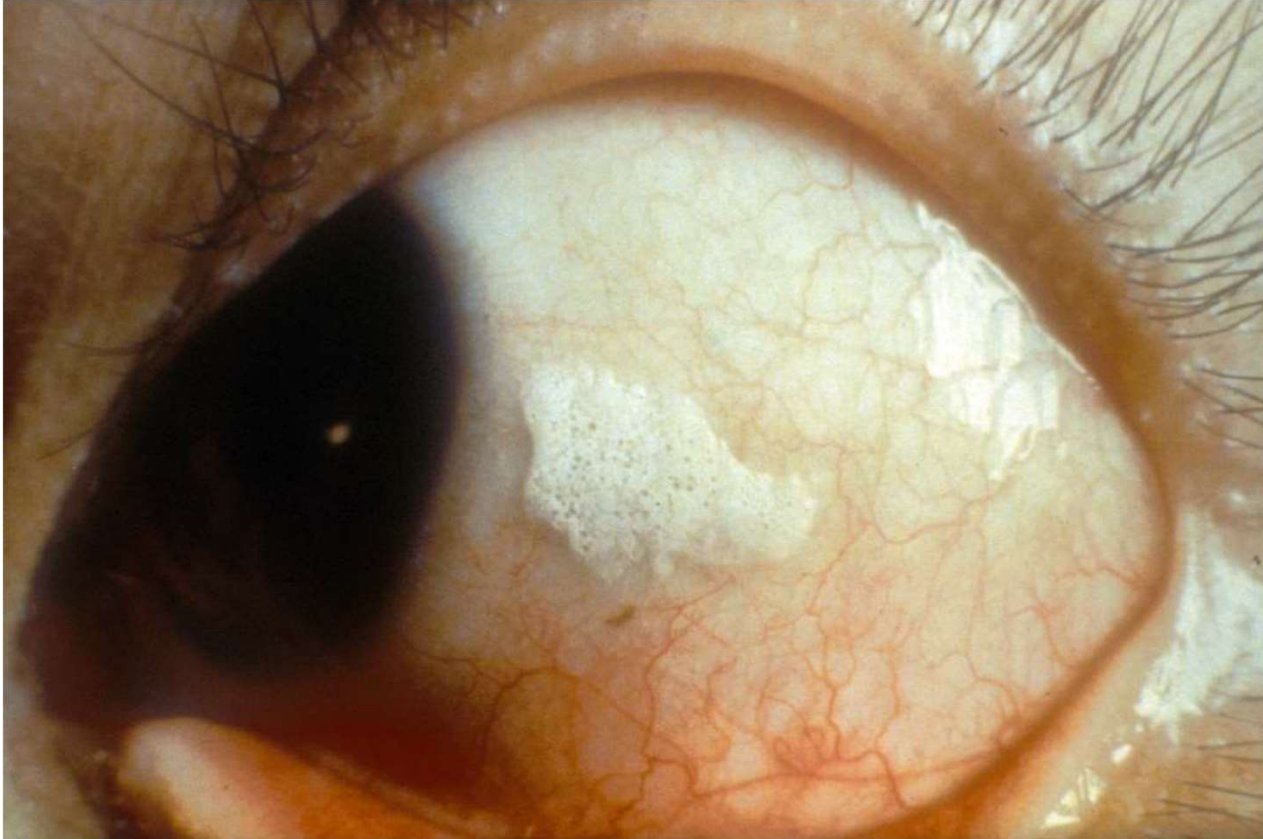

The background is a vibrant green with a fine, woven texture. A large, semi-transparent white circle is positioned on the right side of the image, serving as a backdrop for the text.

# IIPA Level III

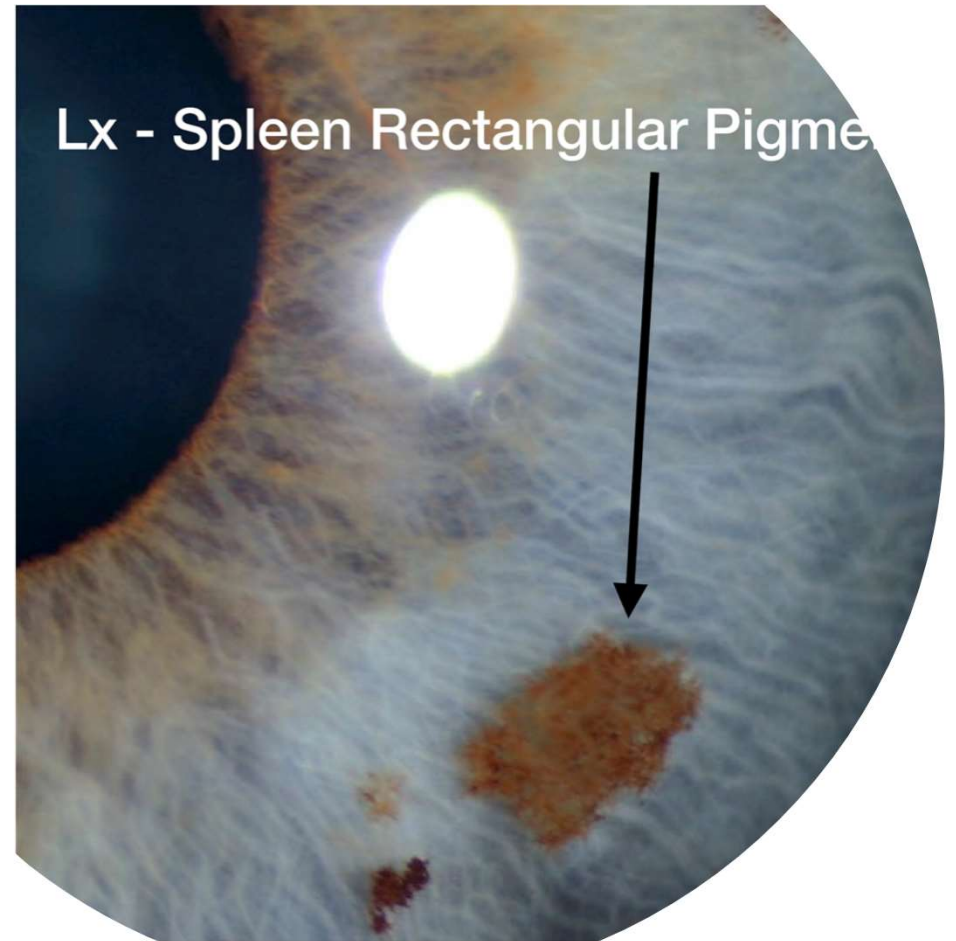
Exam Practice

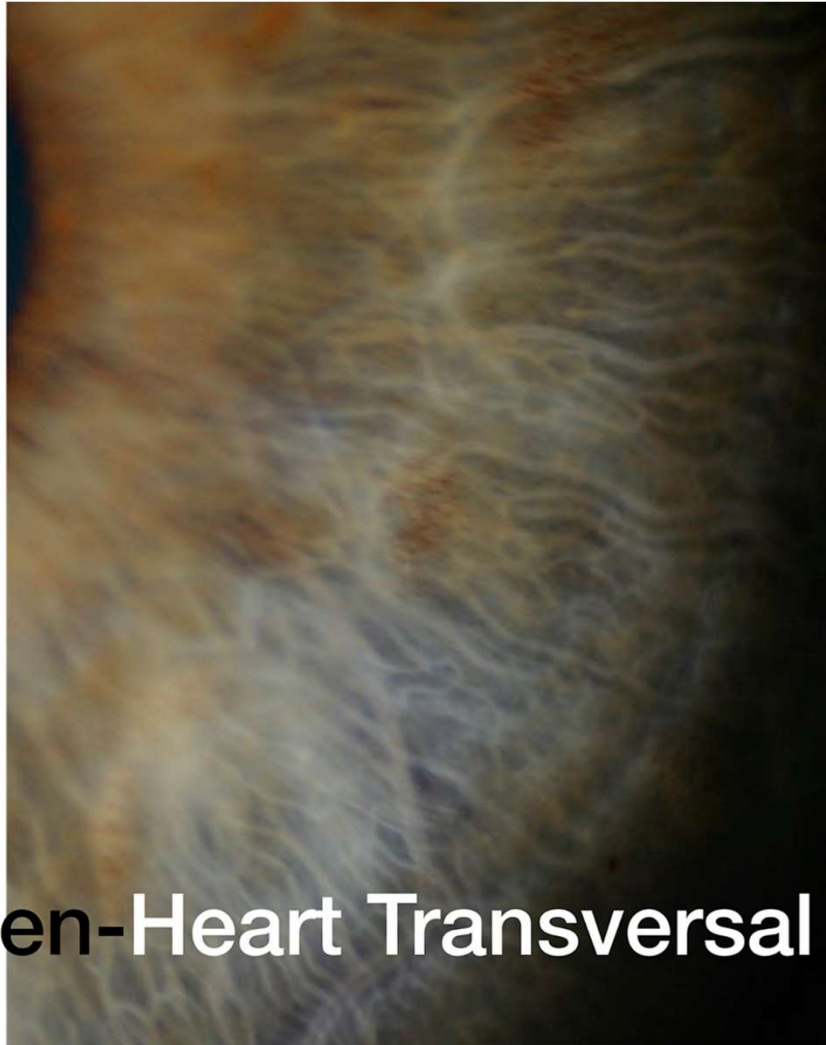


Based on John Andrew's works, what is this spot called and what causes it?

1. Pinguecula
2. Bitot's Spots
3. Brushfield's Spots
4. Lymph Cords

Where can you find a rectangular pigment and what can it mean?





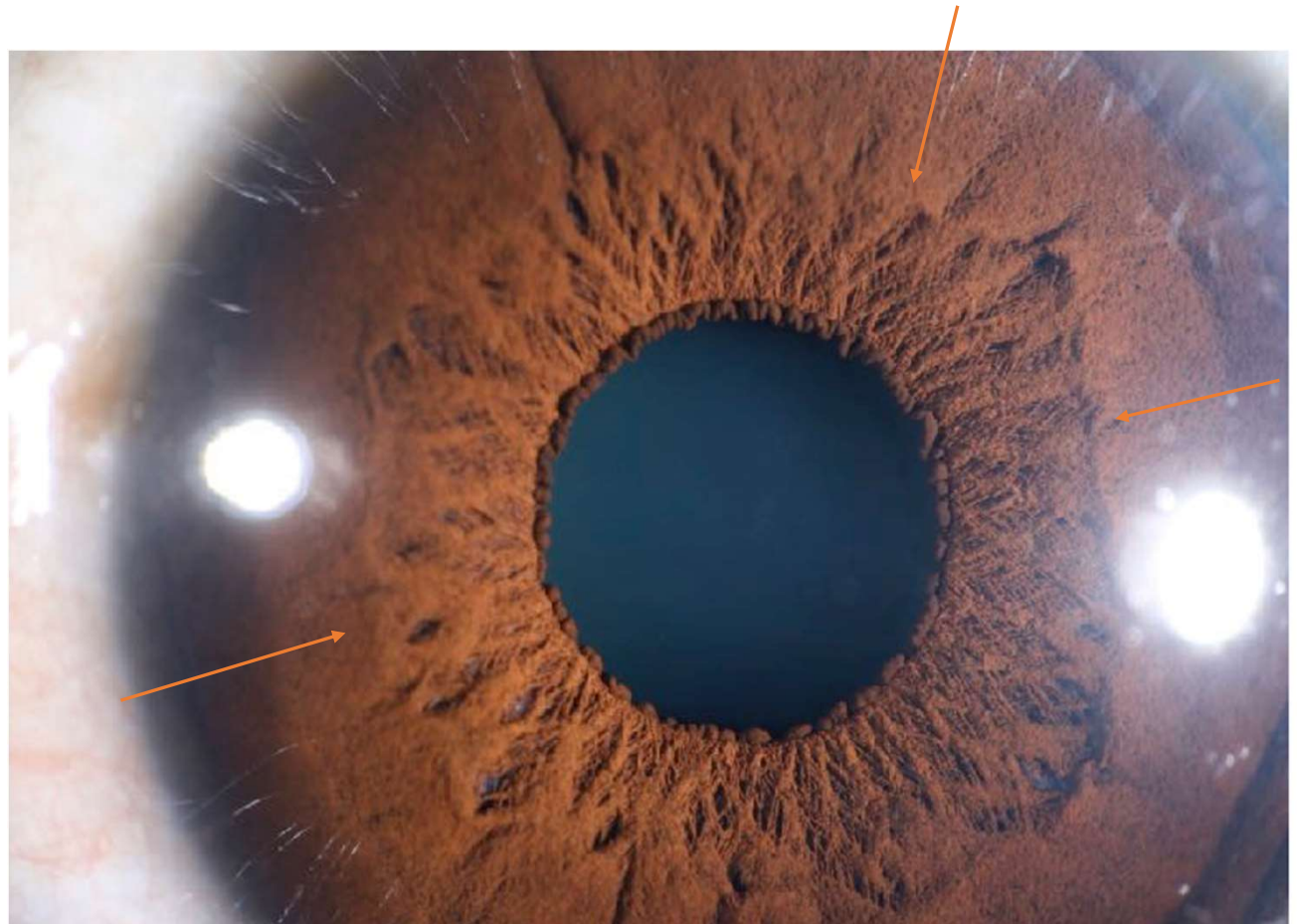
**Lx Spleen-Heart Transversal**

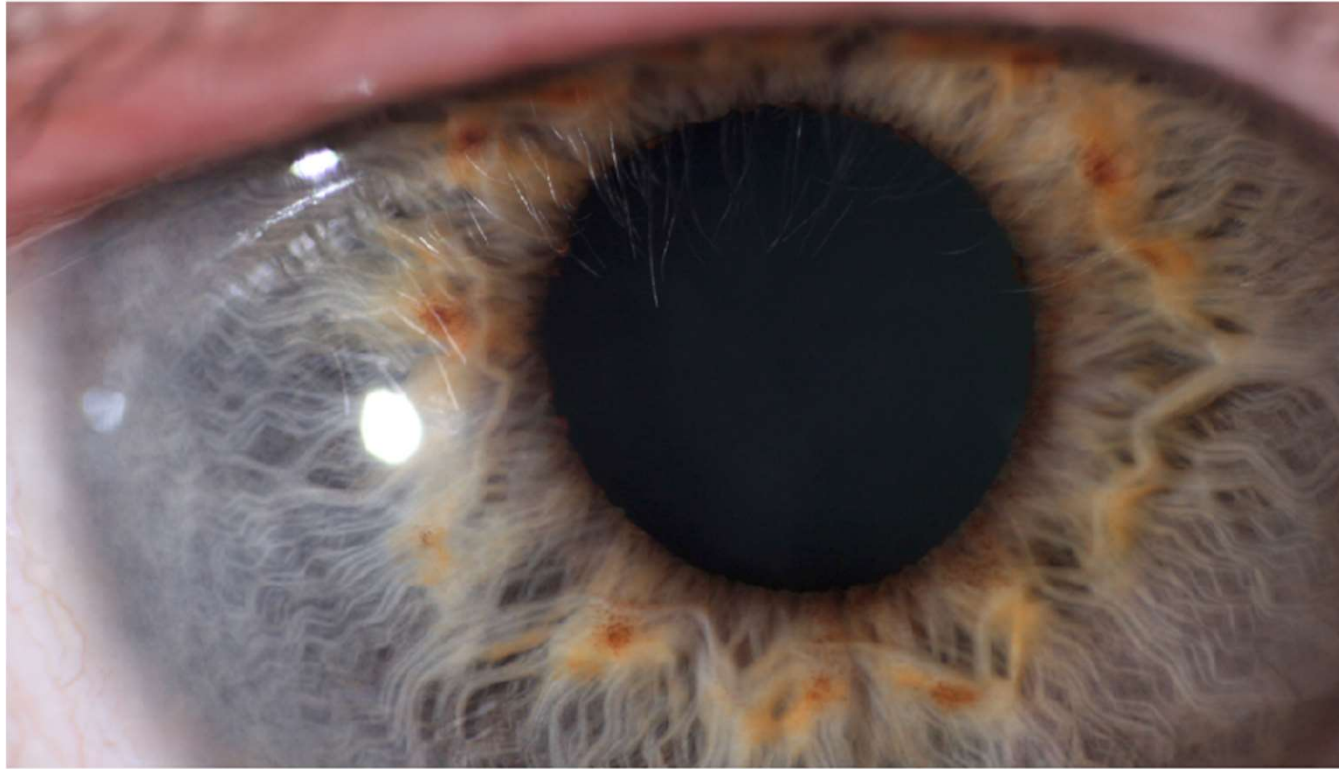
What can a Spleen-Heart Transversal indicate?

T/F: A Spleen-Heart Transversal can be seen in both the right and left irises.

Notice the arrows.

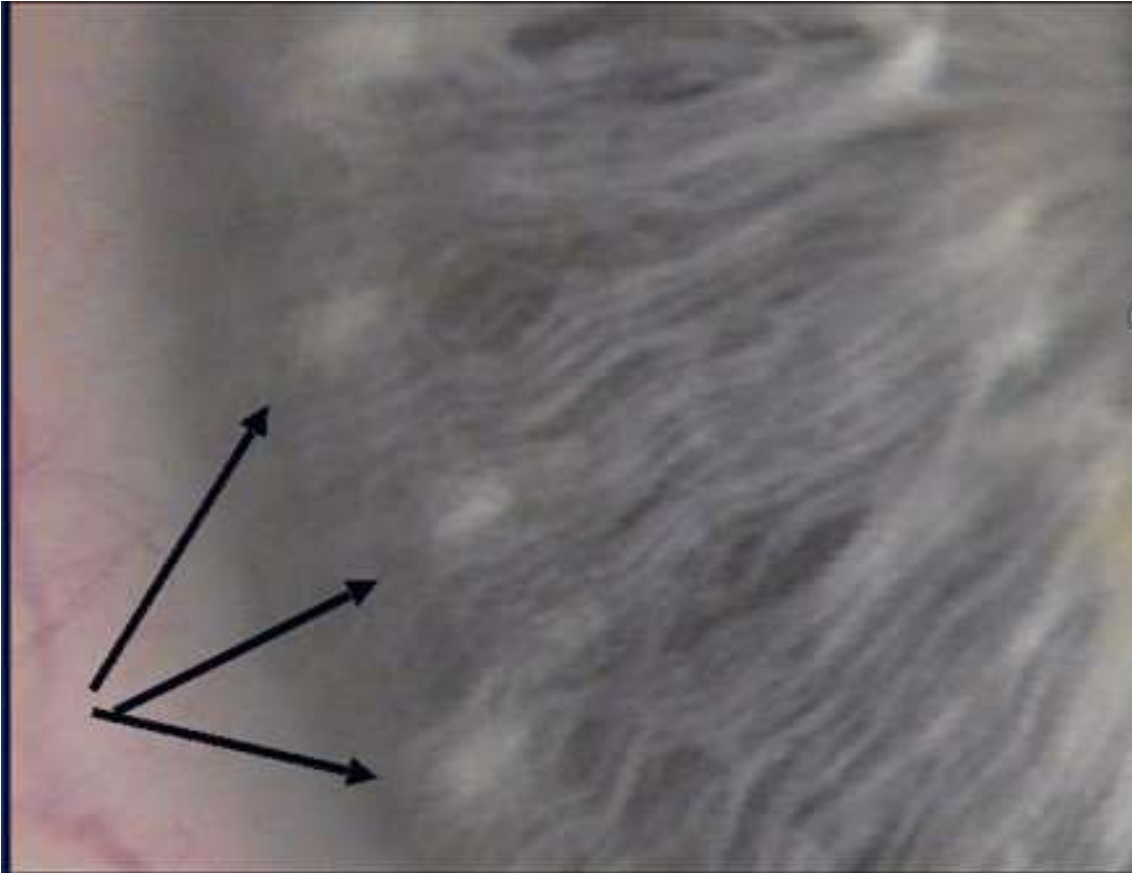
What type of collarette do you see here and what can it mean?





Think of John Andrew's works. What are the pigments around the collarette called and what can cause it?

1. Square Pigment
2. Swirls of Orange
3. Bitot's Spots
4. Liver Detox Spots

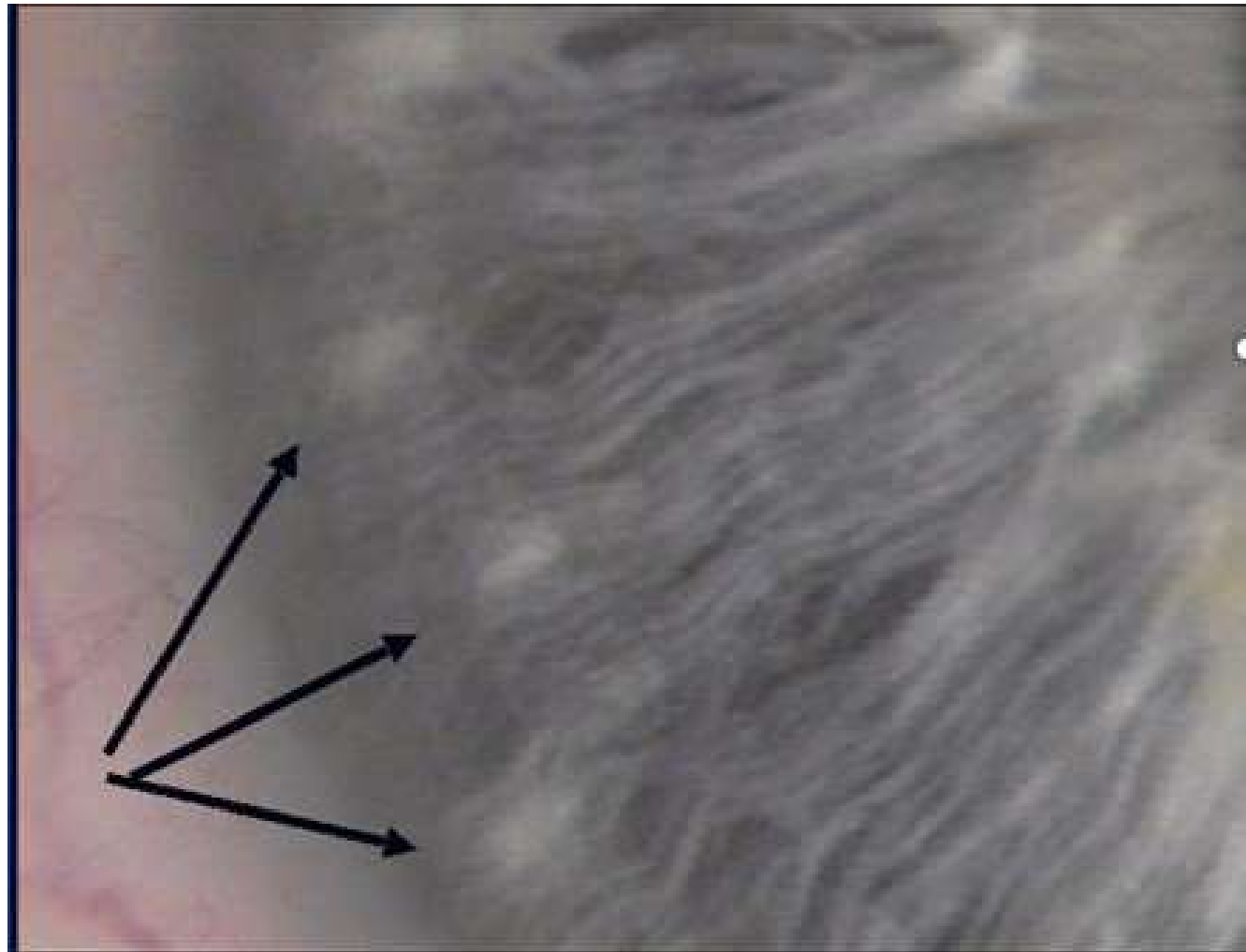


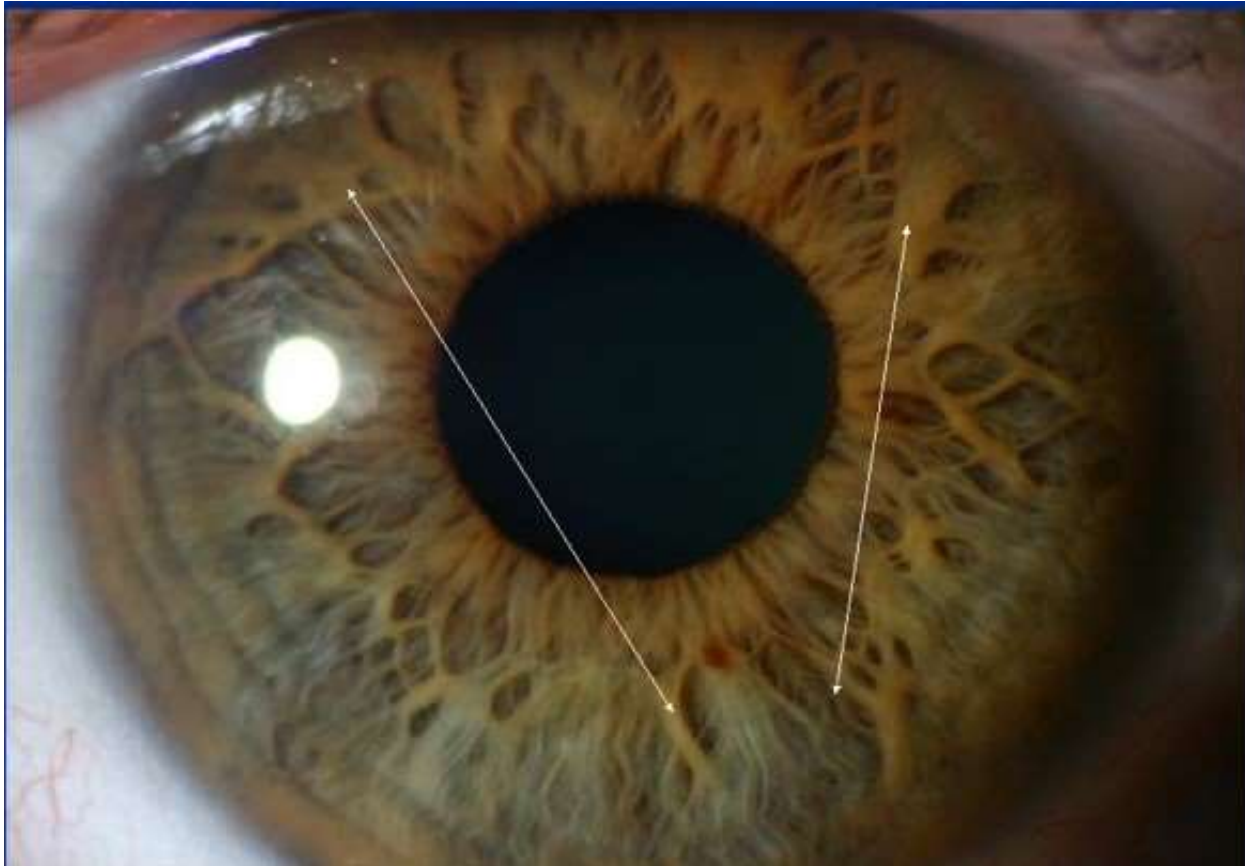
Think of John Andrew's works. What are these spots called and what can cause them?

1. Square Pigment
2. Swirls of Orange
3. Bitot's Spots
4. Brushfield Spots

This ring is called a:

1. Lipemic Diathesis
2. Ring of Perfection
3. Ring of Harmony
4. Kayser-Fleisher Ring

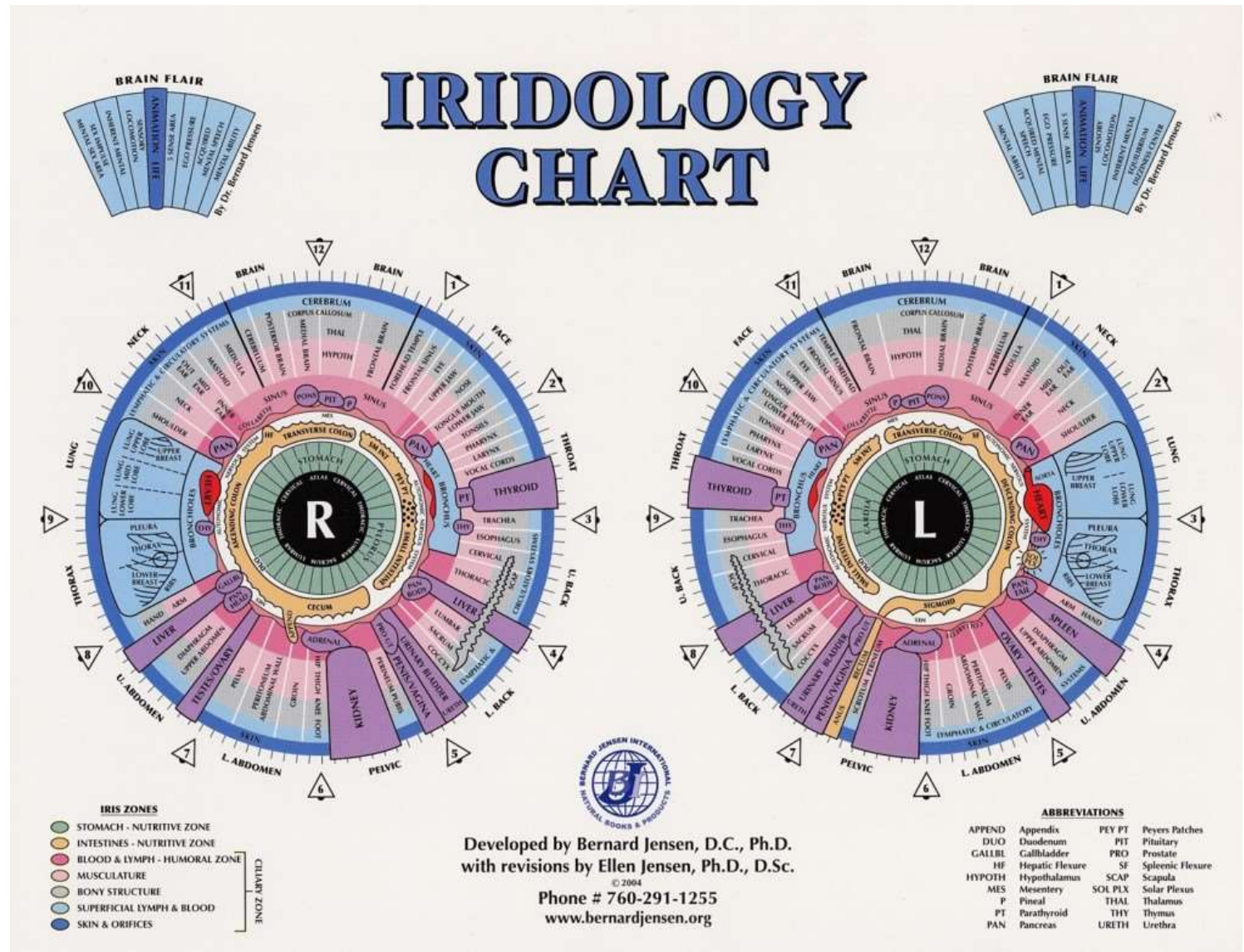


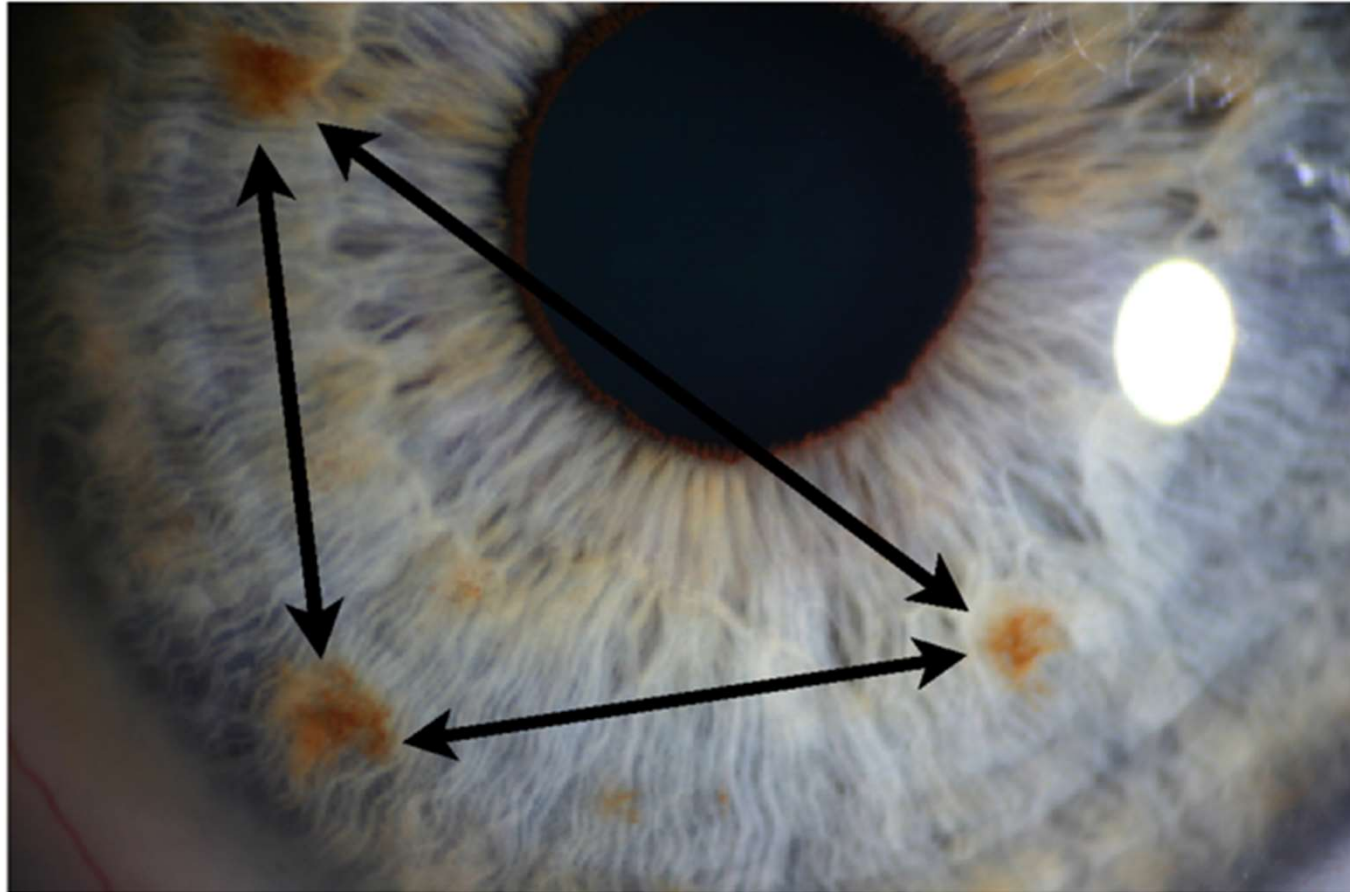


Thinking of John Andrew's works and looking at the yellow arrows, what are these markings called and what do they mean?

1. Fibers of the Iris
2. Lymph Cords
3. Linear Collarette
4. Swirls of Orange

What is the Mesenchyme and where is it located on the iridology chart?

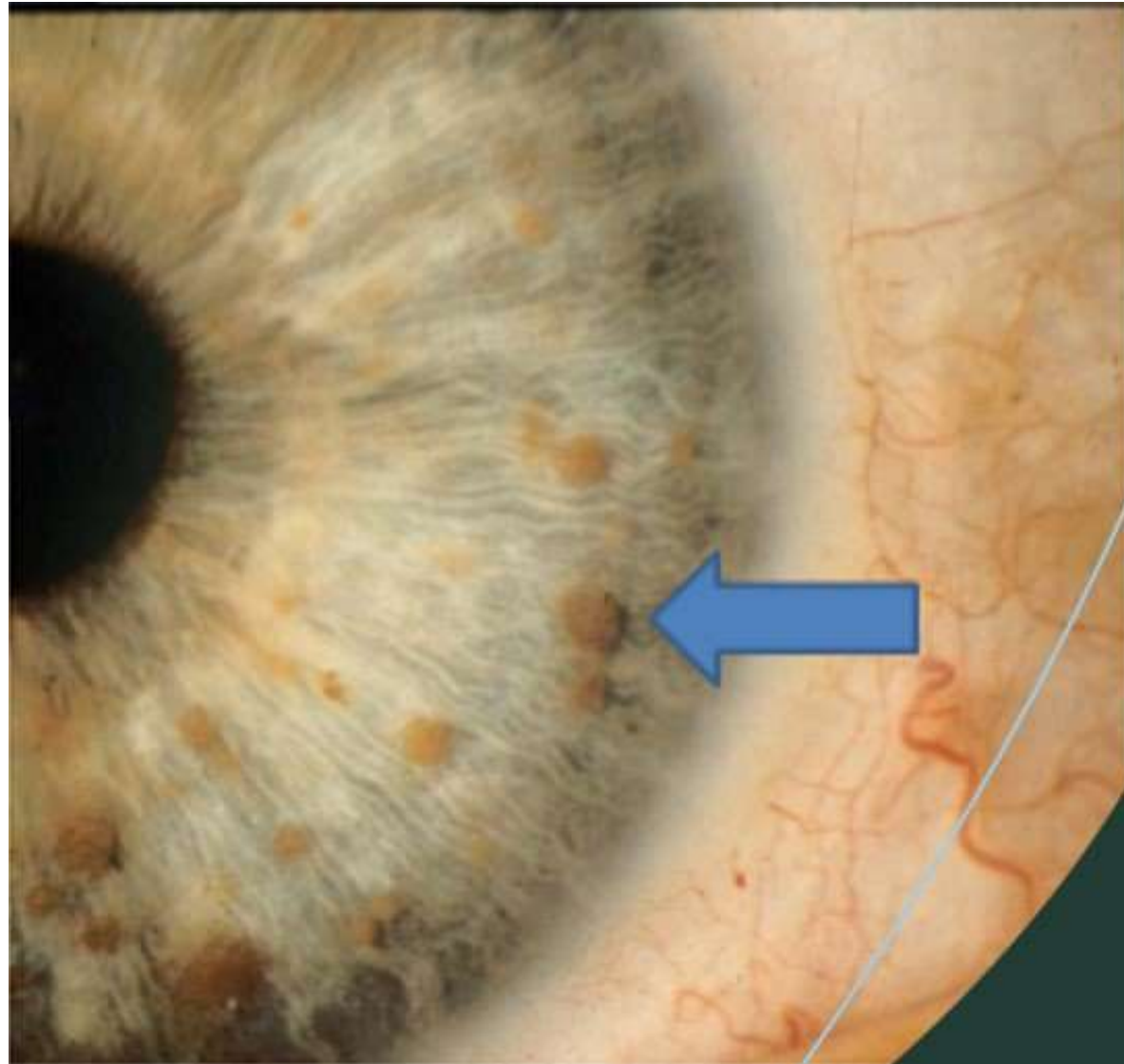


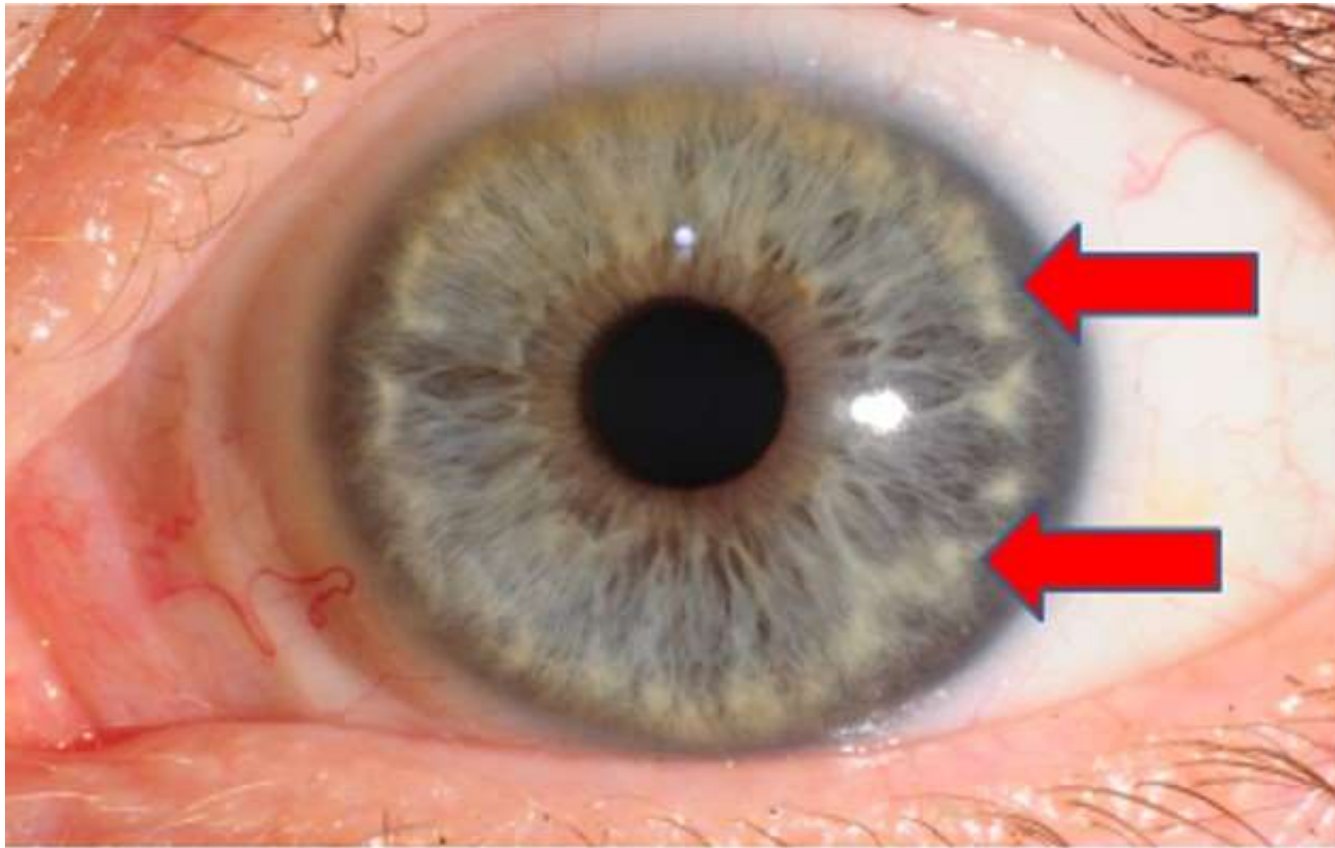


What are these 3 pigments called and what can this mean?

Think about Ellen Jensen's Atypical Ocular Signs, what is the name of these markings and what do they mean?

1. Orange Pigments
2. Lisch Nodules
3. Mammilations
4. None of the above



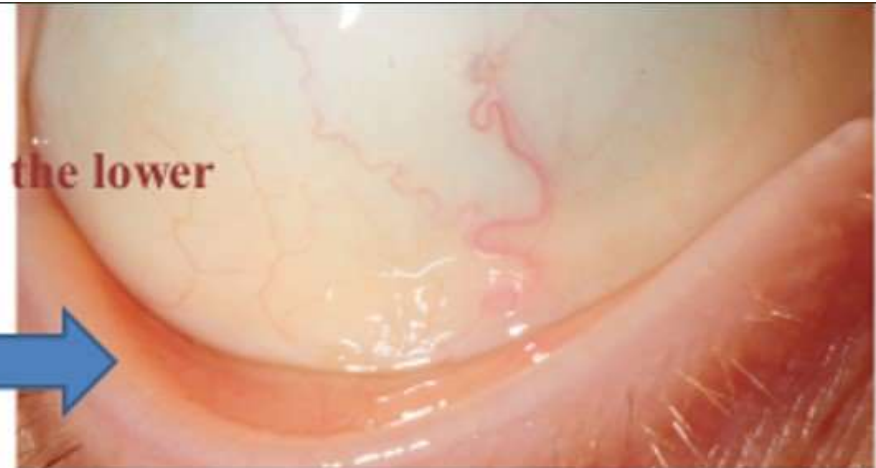

What are these spots called and what can they mean?

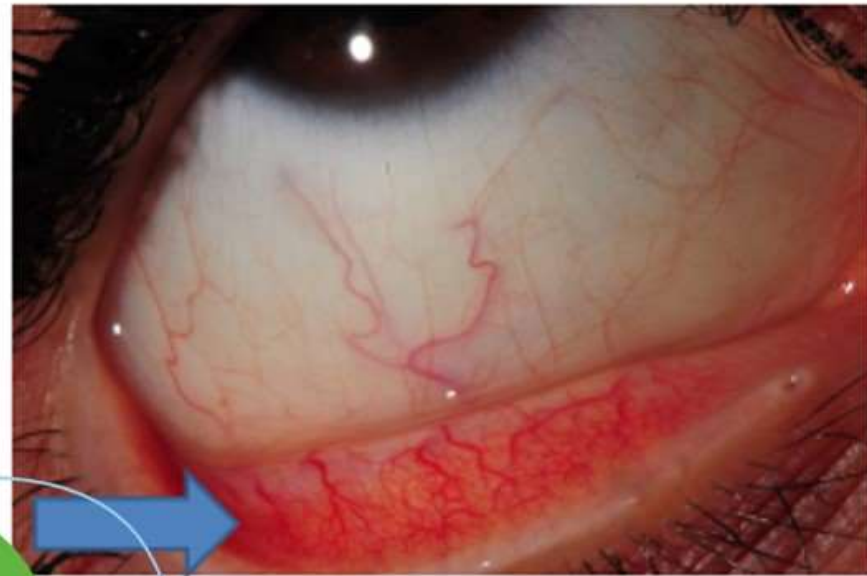
1. Bitot's Spots
2. Wollflin Spots
3. Ring of Freedom
4. None of the above

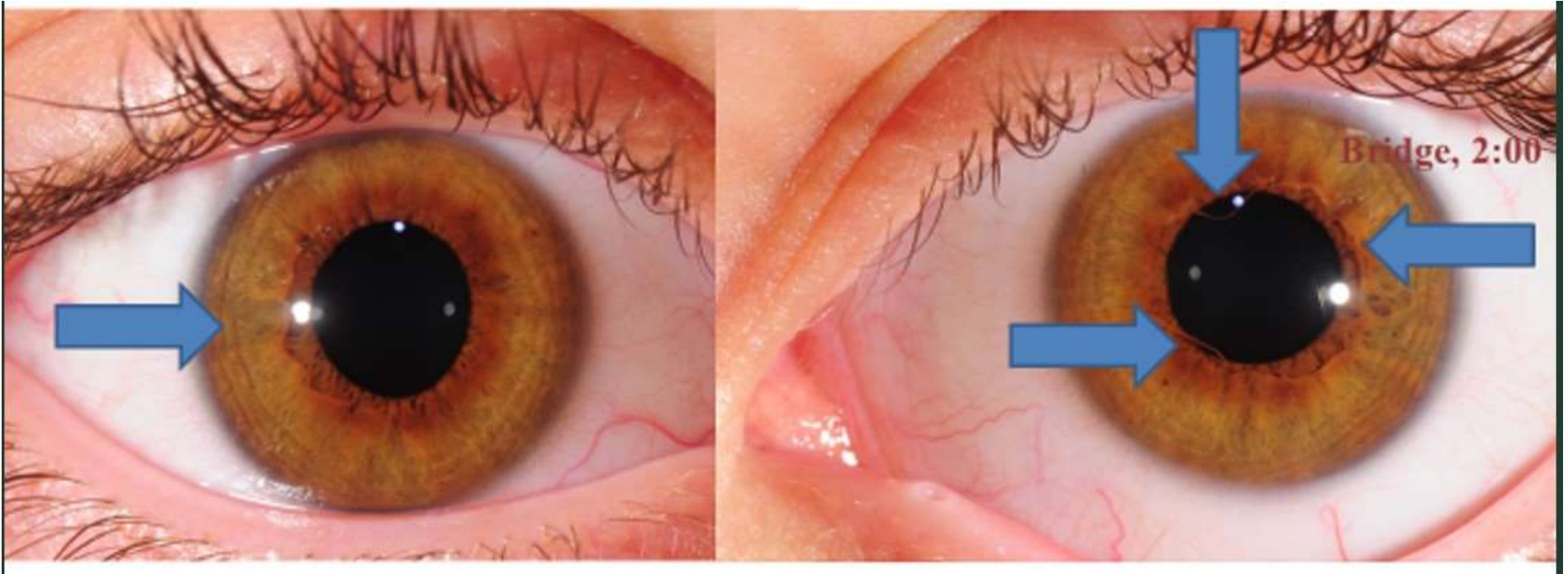
What is it called when the inside of the lower eyelid is devoid of blood vessels and what could be the symptoms and the cause?

**White inside the lower eyelid.**

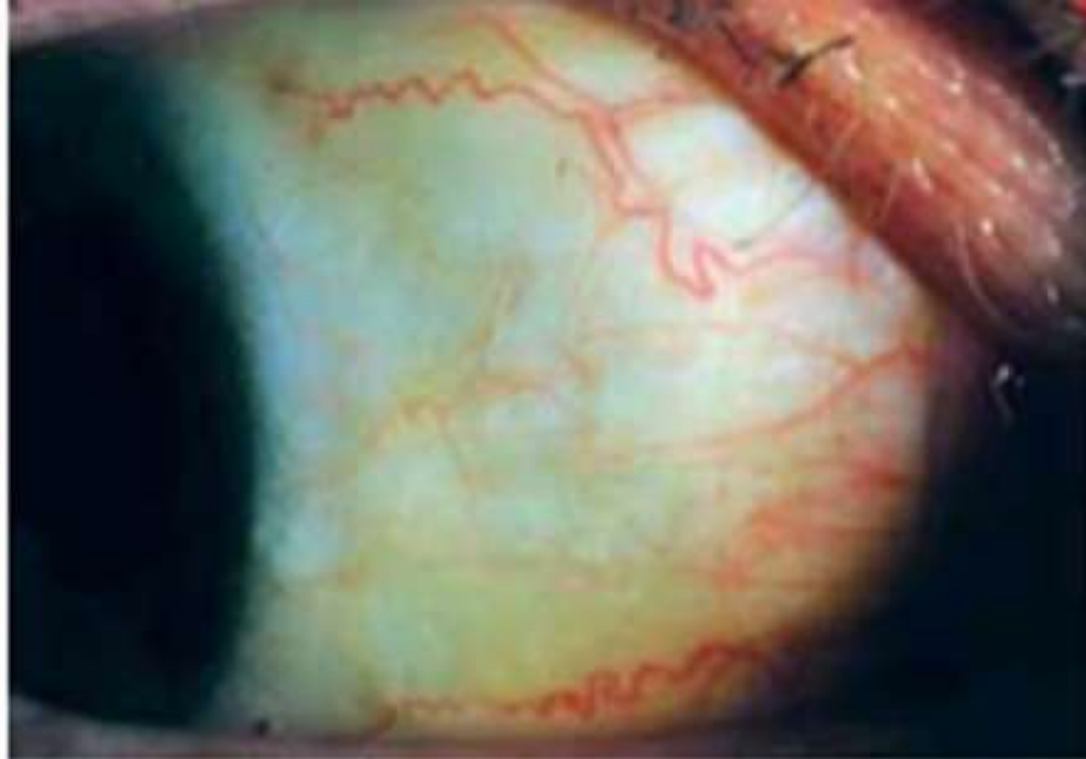
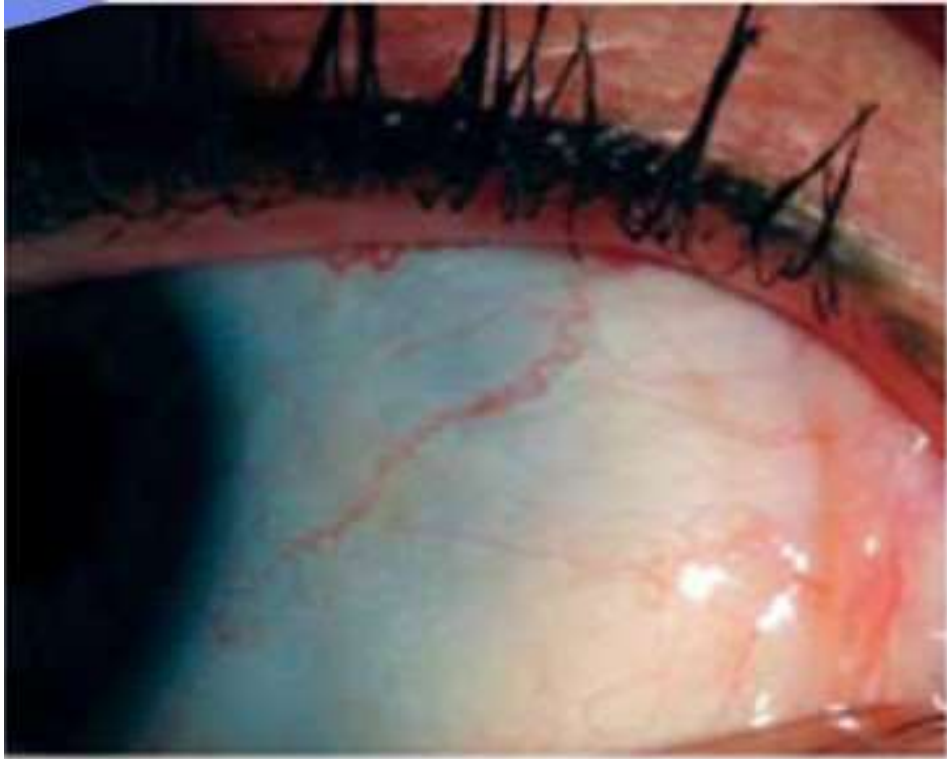


**Rich red blood vessels when there is no anemia.**





What is this sign/syndrome called and what does it mean?



What are the names of the 2 sclera markings you see here and what can they mean to your client?