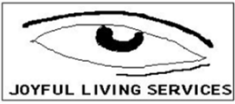



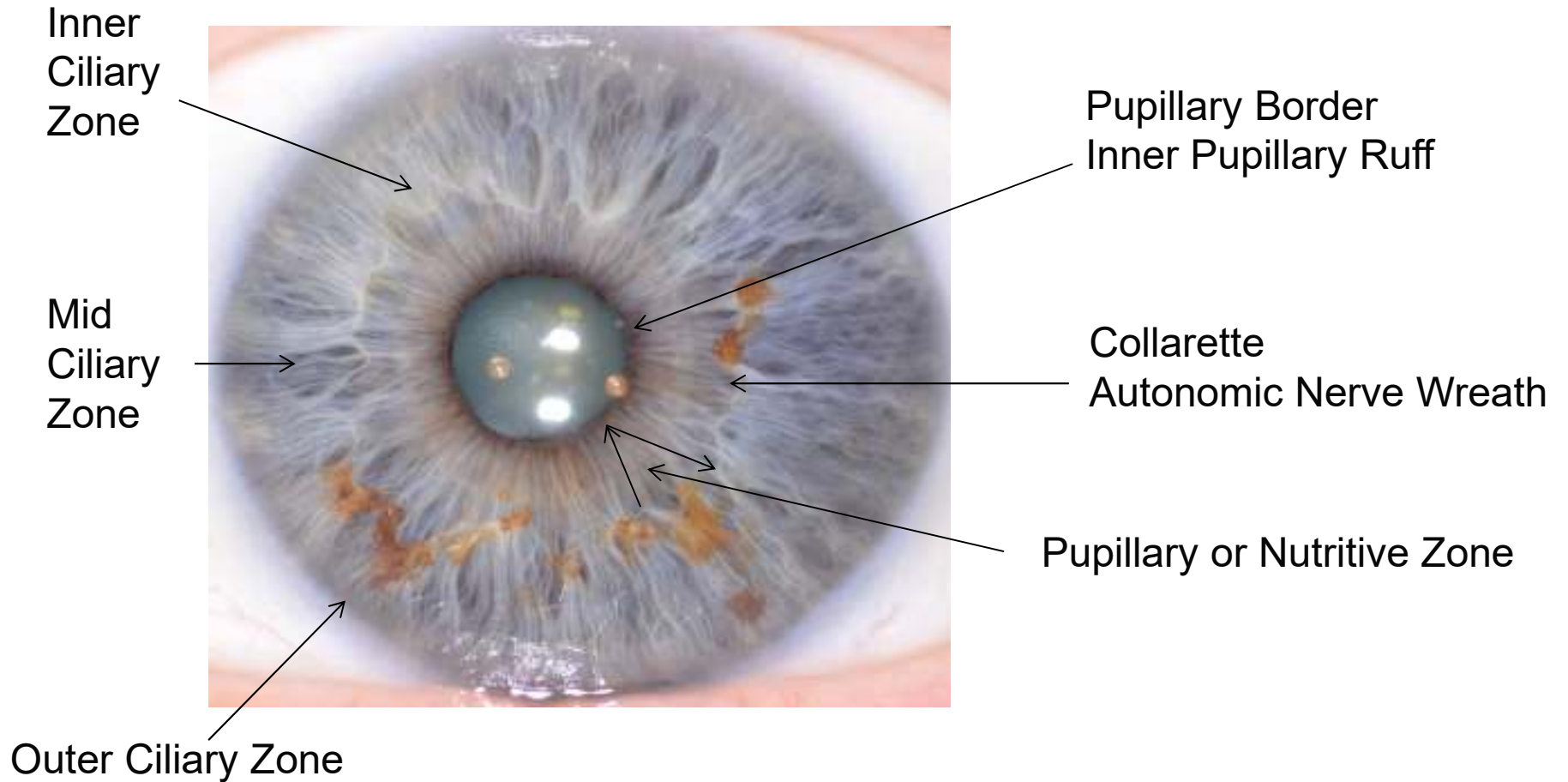
Iris Zones





Iris Zones

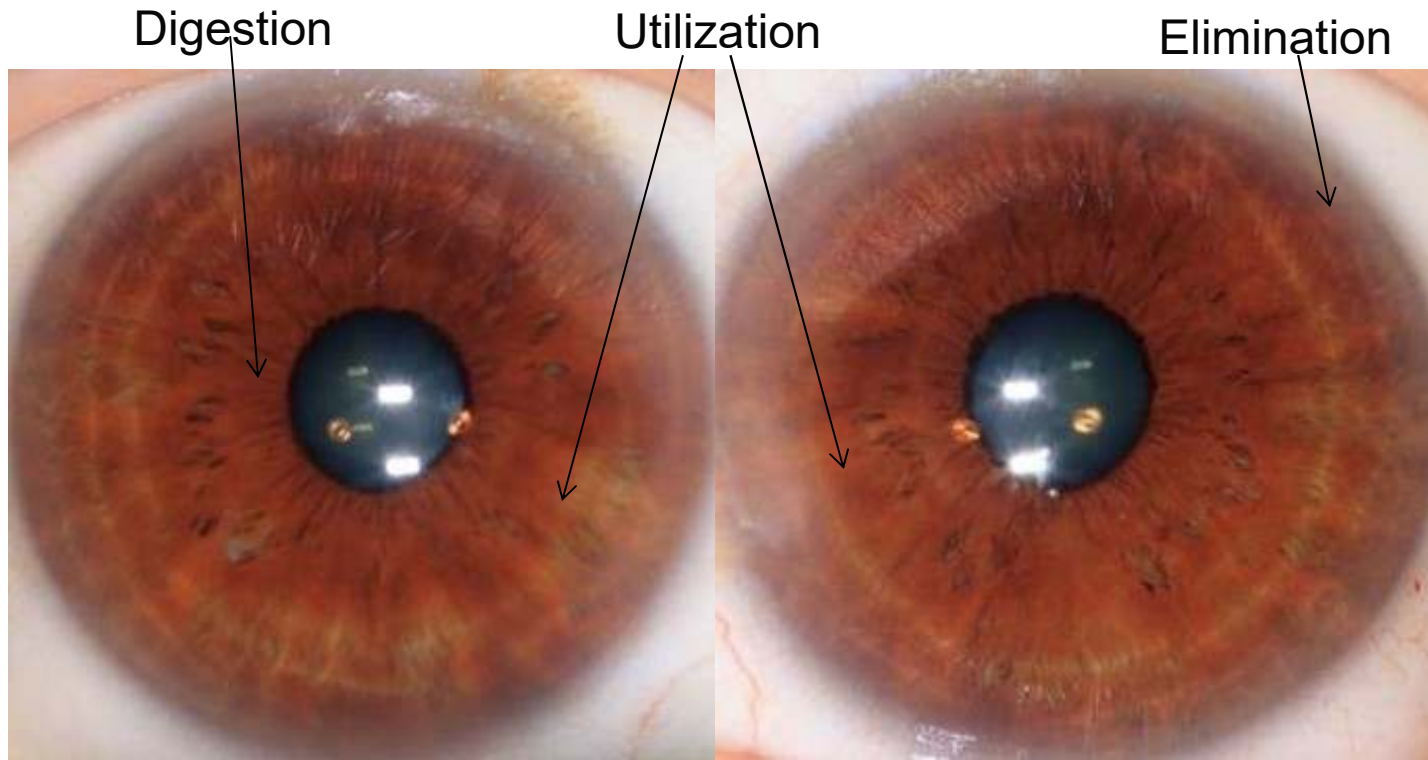
Visible Rings in the Iris





Iris Zones

The iris can be divided into 3 major zones: Digestion, Utilization and Elimination



Digestion

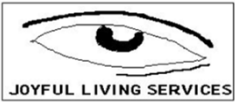Utilization

Elimination

Right Iris
Father

Left Iris
Mother





Iris Zones

Zone 1-2: Digestive/Intestinal

- Stomach & Intestines

Zone 3: Humoral: Inner Ciliary

- Blood, Lymph & Glands

Zone 4: Musculature: Mid Ciliary

- Muscles

Zone 5: Structural: Mid Ciliary

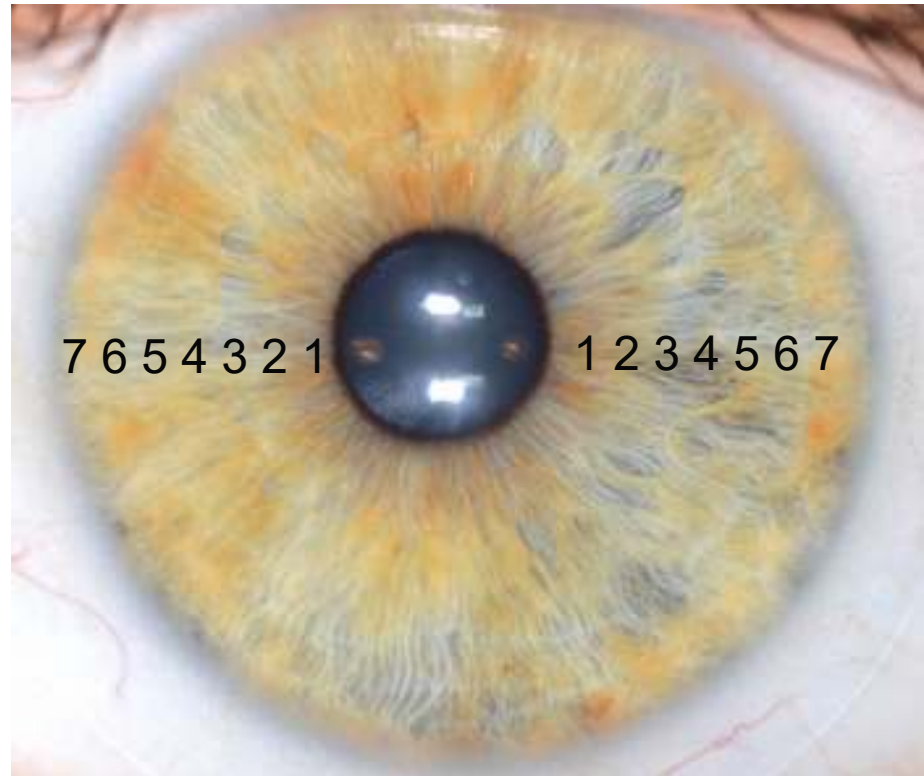
- Bony Structure and Ultimate Utilization

Zone 6: Lymph

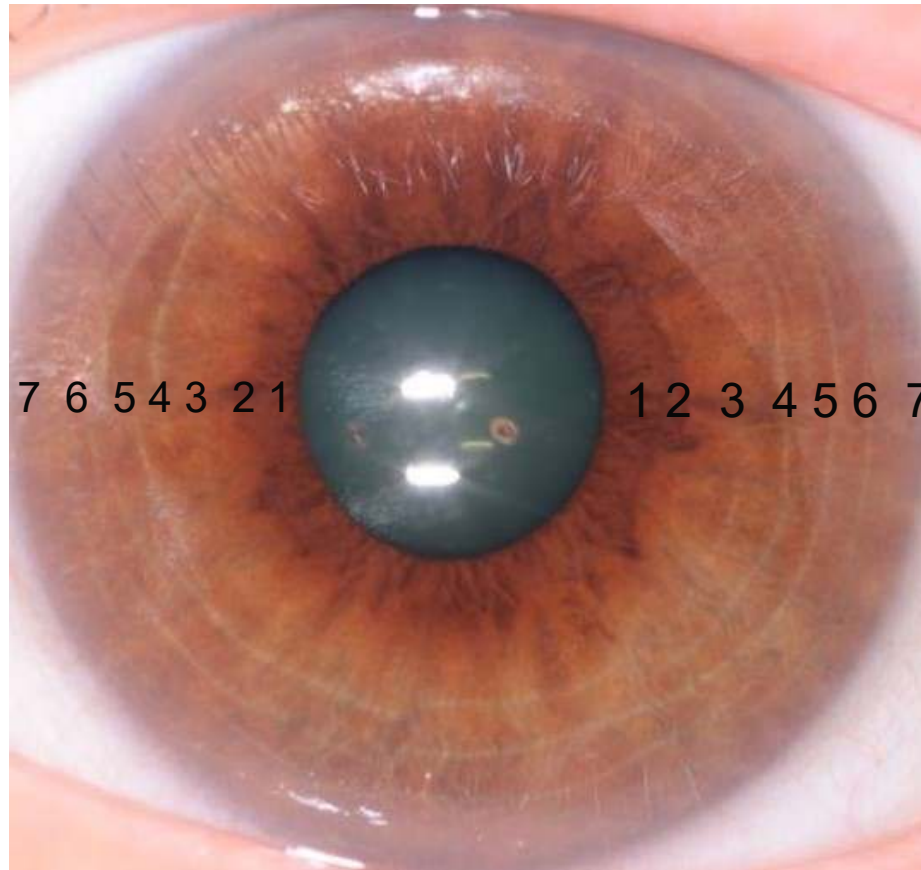
- Lymph Detoxification

Zone 7: Skin: Outer Ciliary

- Skin Elimination



Iris Zones

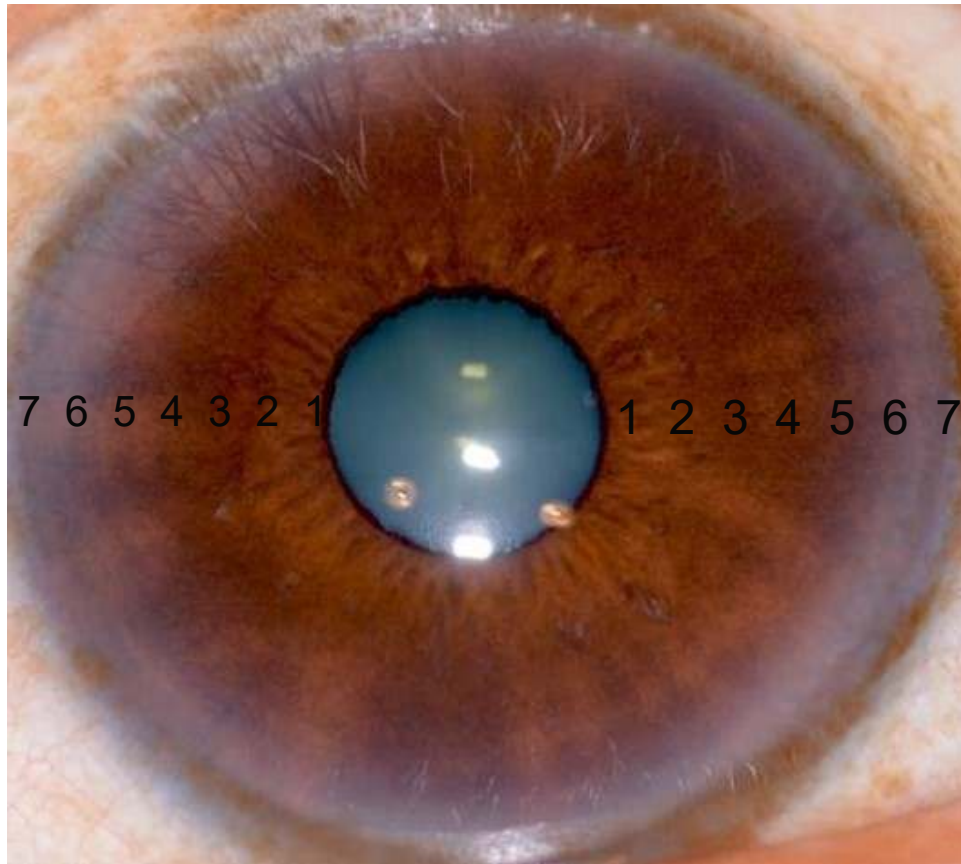


1. Digestive
2. Intestinal
3. Humoral
4. Muscular
5. Structural
6. Lymph
7. Skin

Mixed Iris – Mixed-Biliary Iris Constitution



Iris Zones

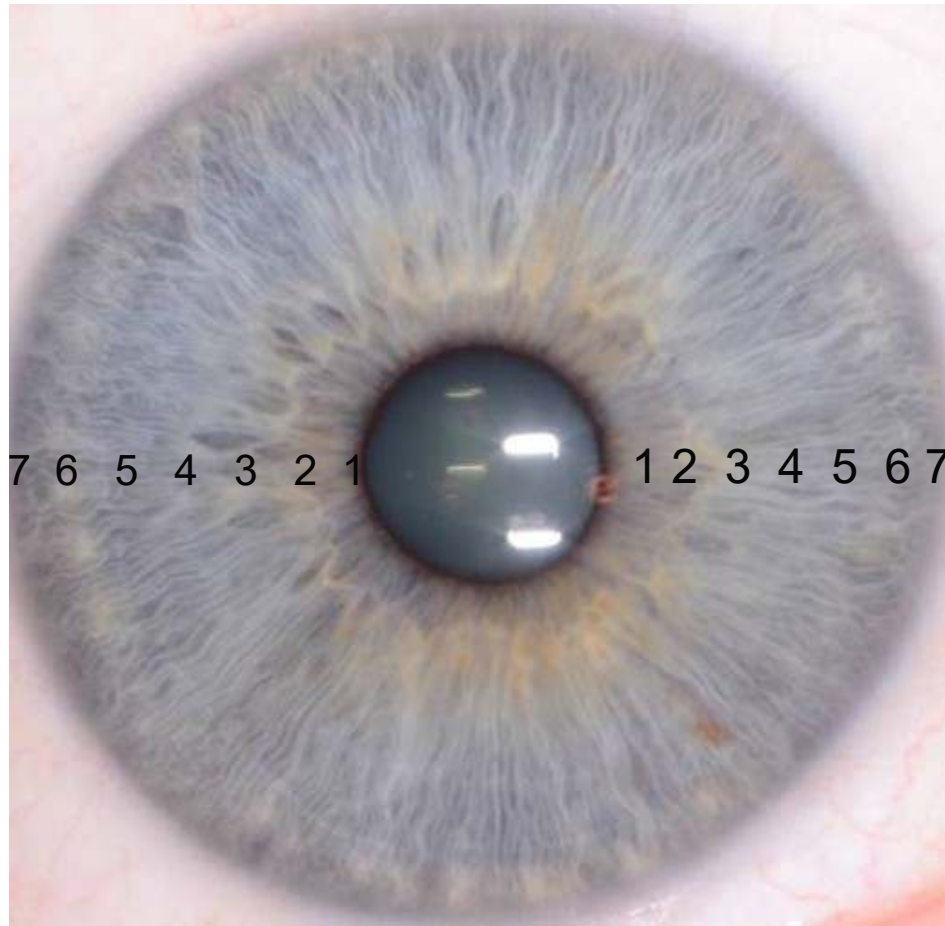


1. Digestive
2. Intestinal
3. Humoral
4. Muscular
5. Structural
6. Lymph
7. Skin

Brown Iris – Hematogenic Iris Constitution



Iris Zones



1. Digestive
2. Intestinal
3. Humoral
4. Muscular
5. Structural
6. Lymph
7. Skin

Blue Iris – Lymphatic Iris Constitution

